

RENAL ARTERIOVENOUS FISTULA FOLLOWING KIDNEY BIOPSY IN SYSTEMIC LUPUS ERYTHEMATOSUS

K H Leong, M L Boey, P H Feng

ABSTRACT

Patients with lupus nephritis frequently undergo renal biopsies. A rare complication of this procedure is the development of renal arteriovenous fistulas. We report two patients with systemic lupus erythematosus (SLE) who developed this vascular complication several years after renal biopsy.

Keywords: systemic lupus erythematosus, renal biopsy, renal arteriovenous fistula

SINGAPORE MED J 1993; Vol 34: 327-328

INTRODUCTION

Renal biopsy in patients with lupus nephritis provides histological data and helps discriminate between patient outcomes. It is a standard procedure in centres involved in experimental therapeutic protocols for patients with lupus nephritis. The mortality rate from percutaneous renal biopsy is low, being less than 0.1%⁽¹⁻³⁾. Well-known complications of renal biopsy include gross haematuria, peri-renal haematoma, infection and accidental puncture of adjacent structures⁽¹⁾. A rare complication is renal arteriovenous (a-v) fistulas. This may occur in the immediate post-biopsy period or several years later. We report two patients with lupus nephritis who developed renal a-v fistulas, a delayed vascular complication of renal biopsy.

CASE HISTORY

Patient 1

LLC is a 35-year-old Malaysian Chinese female. She developed acute nephritis at 20 years of age. Serological investigations confirmed the diagnosis of SLE. A renal biopsy was performed in 1977. Histology showed diffuse proliferative lupus nephritis (WHO Class IV). The immediate post-biopsy period was uncomplicated. She was treated with prednisolone and her disease entered remission in 1981.

In April 1989, she developed microscopic haematuria and proteinuria of 900mg per day. Blood pressure was 110/80mmHg. An intravenous urogram showed a mass lesion in the left kidney. A renal angiogram revealed a large a-v fistula with a lobulated aneurysm occupying almost the lower half of the left kidney (Fig 1). Angiographic embolisation was performed satisfactorily. The a-v fistula closed. The urinary abnormalities resolved completely and she remained well one year after the procedure.

Patient 2

TSH was a 35-year-old Chinese female. SLE was diagnosed in 1974 when she developed rashes and thrombocytopenia.

Department of Rheumatology & Immunology
Tan Tock Seng Hospital
Moulmein Road
Singapore 1130

K H Leong, MBBS, M Med (Int Med) MRCP (UK)
Registrar

M L Boey, MBBS, M Med (Int Med), FAMS
Consultant Physician

P H Feng, MD, FRCP (Edin), FRCP (Glasg), FAMS
Senior Physician & Head

Correspondence to: Dr M L Boey

Fig 1 - Renal angiogram showing a large a-v fistula with a lobulated aneurysm in the left kidney.

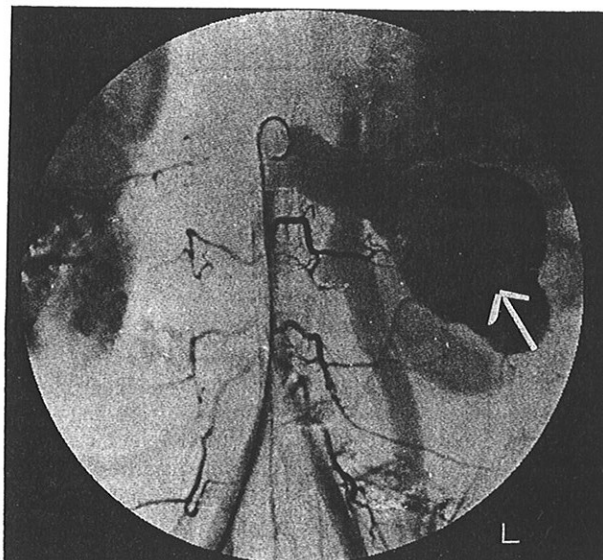
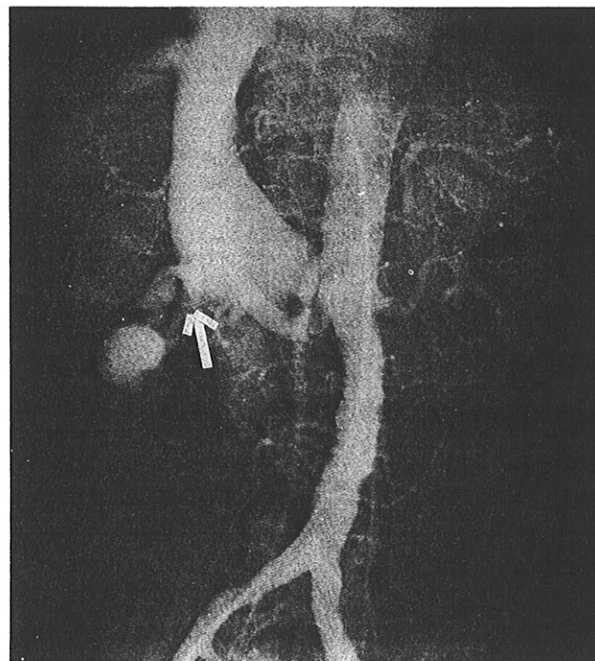


Fig 2 - Huge a-v fistula in right kidney which communicated by means of a vein with IVC.



Anti-nuclear antibody test and LE cell test were positive. A year later she developed lupus nephritis. A renal biopsy was performed in 1975. Blood pressure at the time of biopsy was 120/70 mmHg. The immediate post-biopsy period was uncomplicated. Histology revealed minimal changes with focal sclerosis (WHO Class 1). Her disease was well controlled between 1974 and 1983.

A right renal bruit was detected in 1984. Angiographic studies showed a huge a-v fistula in the right kidney involving a single hypertrophic segmental artery which communicated by way of a vein with the inferior vena cava (IVC) (Fig 2). She refused therapeutic intervention until 1987 when she developed cardiac failure. A repeat renal angiogram showed that the size of the a-v fistula remained the same. She agreed to angiographic embolisation of the fistula. However, the procedure was unsuccessful due to migration of the coils inserted. In 1988, she died from cor pulmonale secondary to pulmonary hypertension in SLE.

DISCUSSION

Renal a-v fistula is a rare but well-documented complication of percutaneous renal biopsy. Blake et al⁽⁴⁾ reported two patients who developed this complication within six months and three weeks respectively of the biopsy. Both patients had renal bruits. Some patients may be asymptomatic. DeBeukelaer et al⁽⁵⁾ described three paediatric cases, one of whom had an enlarging abdominal mass and a bruit twenty-four hours post-biopsy. The second had uncontrolled hypertension three months after the biopsy and the third was asymptomatic.

The kidney is a richly vascular organ with small arteries and veins occurring close together. Arteriovenous perforations which heal adequately are common after renal biopsy. However, the presence of hypertension, sclerosis and interstitial fibrosis makes difficult immediate closure of such perforations. Furthermore, an intra-renal haematoma may create an arteriovenous channel by a "pressure" mechanism. This may eventually become an arteriovenous fistula. Therefore factors

which may predispose to the development of renal a-v fistula include uncontrolled hypertension, gross haematuria or severe flank pain following biopsy, especially in patients in whom large blood vessels are seen on histology⁽⁵⁾.

In our patients, haematuria or flank pain were absent in the immediate post-biopsy period and the biopsy specimens did not reveal the presence of large vessels. They were not hypertensive at the time of the biopsy. Though no evidence of a fistula was noted post biopsy or on follow-up over a period of 4 and 9 years, subsequent evaluation revealed the presence of a renal a-v fistula. At the time of detection, the size of the fistulas and the extent of a-v shunting in both patients were significant. Thus, intervention was necessary so as to prevent complications such as heart failure, bleeding or rupture. Angiographic embolisation was preferred to surgery since it is a procedure which is associated with low morbidity.

We conclude that awareness of renal a-v fistula as a complication of renal biopsy is important in SLE and other renal diseases. Symptoms and signs such as haematuria, proteinuria and heart failure are common to both SLE and renal a-v fistula and may cause confusion in diagnosis. We recommend regular abdominal auscultation in all SLE patients who have undergone renal biopsy. Ultrasound or CT scans of the abdomen may assist in the diagnosis of this complication. A high index of suspicion is required to ensure early diagnosis of this treatable condition.

REFERENCES

1. Slotkin EA, Madsen PO. Complications of renal biopsy: Incidence in 5000 reported cases. *J Urol* 1962;87:13-5.
2. Muth RG. The safety of percutaneous renal biopsy: An analysis of 500 consecutive cases. *J Urol* 1965;94:1-3.
3. Kark RM, Muehrcke RC, Pollack VE, Pirani CL, Kiefer JH. An analysis of five hundred percutaneous renal biopsies. *Arch Int Med* 1958;101:439-47.
4. Blake S, Hefferman S, McCann P. Renal arteriovenous fistula after percutaneous renal biopsy. *Br Med J* 1963;1:1458-60.
5. DeBeukelaer MM, Schreiber MH, Dodge WF, Travis LB. Intra-renal arteriovenous fistulas following needle biopsy of the kidney. *J Paed* 1971;78:266-72.