

# XANTHOGRANULOMATOUS PYELONEPHRITIS IN A MALAYSIAN POPULATION

K B H Koh

## ABSTRACT

*Xanthogranulomatous pyelonephritis is a clinico-pathological entity that is gaining awareness amongst urologists worldwide. It is an unusual chronic inflammatory lesion involving the kidney that destroys renal parenchyma and may mimic renal carcinoma. It is usually seen in middle-aged women and is associated with urinary tract infections and urinary calculi. Most reports and reviews of this condition come from the West; this study reviews the incidence and presentation of the condition in a Malaysian population.*

**Keywords:** xanthogranulomatous pyelonephritis

SINGAPORE MED J 1993; Vol 34: 341-342

## INTRODUCTION

Xanthogranulomatous pyelonephritis (XGPN) is an unusual chronic infective disorder of the kidneys which affects mainly middle-aged females with recurrent urinary tract infections and calculi. It differs from the more common chronic pyelonephritis which we see by its more aggressive nature. It is capable of invading and destroying renal parenchyma and adjacent tissues, and is characterised histologically by the presence of foamy macrophages in clusters. Patients usually presents with chronic loin pain, persistent urinary infections and general debility, and the affected kidney is often nonfunctioning by the time they are referred. Occasionally they may present acutely with one of the complications like a renal abscess or sinus. Nephrectomy rids the patient of his or her symptoms.

This study reviews ten patients with XGPN who were treated in the University Hospital Kuala Lumpur. We wish to highlight our experience with this disorder and hopefully increase the index of suspicion in our colleagues so that these patients need not suffer a long period of illness before curative nephrectomy.

## PATIENTS

Between January 1985 and December 1991, 35 nephrectomies were performed in the University Hospital Kuala Lumpur for non-malignant disease. All the specimens were sent for histopathological examination and 10 out of the 35 were diagnosed as xanthogranulomatous pyelonephritis (XGPN). This is a retrospective review of the clinical presentations of these patients with XGPN and data were collected from patients' notes.

## RESULTS

Ten patients were diagnosed to have XGPN between 1985 and 1991. There were two males and eight females and they ranged in age from 36 to 64 years with a mean of 49 years.

Department of Surgery  
University Hospital  
Kuala Lumpur  
Malaysia

K B H Koh, MBBS, FRCS  
Medical Officer

Correspondence to: Dr K B H Koh  
Department of Urology  
St James' University Hospital  
Beckett Street  
Leeds LS9 7TF  
United Kingdom

Table I - Symptoms at presentation (n = 10\*)

Symptoms	Number
Loin pain	8
Recurrent UTI	5
Discharging sinus	1
General ill health	3

(\*Some patients present with more than one symptom)

Table II - Urine cultures in patients with XGPN

Organism	Number
Escherichia coli	3
Pseudomonas	2
Klebsiella	1
Proteus	1
Streptococcus faecalis	1
No organism	2

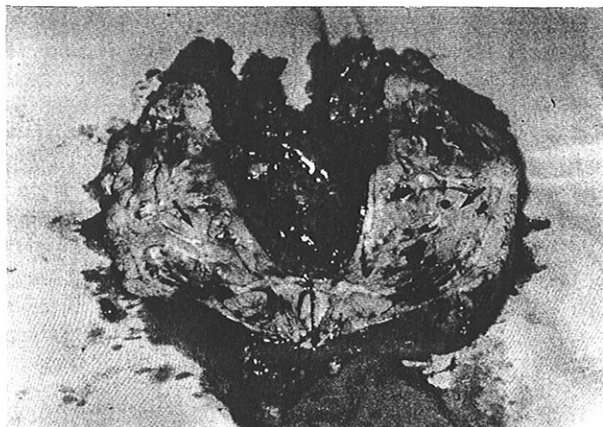
The duration of symptoms varied from one week to 10 years with a median duration of 2 years. The main symptoms at presentation were loin pain and recurrent urinary tract infections (Table I). Associated conditions were the presence of urinary tract calculi in 8 patients (3 staghorn, 3 renal pelvis, 2 ureteric) with four kidneys showing evidence of hydronephrosis, diabetes mellitus in one patient, hypertension in two patients and renal impairment in four patients. The serum creatinine levels ranged from 70 - 450  $\mu\text{mol/l}$  with a mean of 145  $\mu\text{mol/l}$ .

Urinary tract infections were present in 8 patients with the remaining two patients having a sterile urine (Table II). The intravenous urogram (IVU) showed a nonexcreting kidney in 9 patients and a renal mass in one. The right and left kidneys were equally affected. A dimercaptosuccinic acid (DMSA) radioisotope scan was done in 7 patients and revealed a differential function of less than 10% on the affected side in each patient. The patient with a renal mass on the IVU went on to have an ultrasound and CT scan of her kidneys and this confirmed a solid renal mass. Fig 1 shows a nephrectomy specimen with normal parenchyma completely replaced by fibrous tissue, xanthogranuloma and abscess formation.

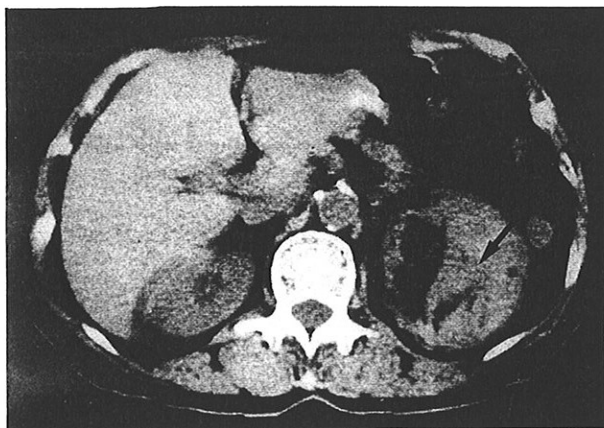
## DISCUSSION

Xanthogranulomatous pyelonephritis is a clinico-pathological entity that is characterised by a chronic granulomatous reaction which destroys renal parenchyma. Grossly, the condition may be easily recognised by focal yellow areas within the

**Fig 1 - Nephrectomy specimen showing nodular appearance of granulomas (arrowed) with interspersed fibrous tissue**



**Fig 2 - CT scan of a patient showing the left kidney replaced by a solid non-enhancing mass (arrow)**



renal parenchyma or be indistinguishable from a carcinoma that invades perirenal tissues. The diagnosis is confirmed histologically by the demonstration of foamy macrophages in clusters, admixed with other chronic inflammatory cells.

The condition is most common in females (75%)<sup>(1,2)</sup> and our own experience parallels this observation. The main age group is 40-60 years but it has also been reported in children<sup>(3)</sup>.

The aetiology of XGPN is unknown although most cases

are associated with a urinary tract infection. This would account for the higher incidence in women. Of our patients, 8 out of 10 had positive urine cultures with *Escherichia coli* and *Pseudomonas* being the most common. Other series have found a preponderance of *Proteus*<sup>(2)</sup> or *E coli*<sup>(4)</sup>. Urinary tract obstruction and urinary calculi are other associated factors. Eighty percent of our patients had urinary calculi and these may have been a nidus for chronic infection or added insult to the kidney by causing obstruction. Abnormalities in lipid metabolism and altered immunological competence have also been suggested to play a role<sup>(2)</sup>.

Most of our patients had suffered symptoms for a long period (median of 2 years) and 90% had a non-excreting kidney on IVU. One patient presented with a solid renal mass while the remainder had diffuse XGPN. Focal disease has been reported in up to 22% of patients,<sup>(5)</sup> being more common in children<sup>(6)</sup>. The importance of focal disease is that it can mimic a renal carcinoma closely, and in our patients this was indeed the case. Preoperative diagnosis is difficult but the presence of foam cells in urine cytology<sup>(7)</sup> and non-enhancing renal masses on CT scan<sup>(5)</sup> may be helpful (Fig 2).

The importance of recognising XGPN as a clinical entity is its ability to infiltrate and destroy renal parenchyma, as well as the fact that it can closely mimic the clinical and histological features of renal carcinoma<sup>(8)</sup>. It is by itself a rarely fatal condition which runs a chronic debilitating course, but may be complicated by life threatening conditions like pyonephrosis or perinephric abscesses. Fistulation is another major complication<sup>(8)</sup>. Failure to recognise the condition may mean that a patient has to suffer a long period of illness before a curative nephrectomy<sup>(9)</sup>.

#### REFERENCES

1. Petronic V, Buturovic J, Isvaneski M. Xanthogranulomatous pyelonephritis. *Br J Urol* 1989; 64:336-8.
2. Tolia BM, Illoreta A, Freed SZ, Fruchtmann B, Bennett B, Newman HR. Xanthogranulomatous pyelonephritis: detailed analysis of 29 cases and a brief discussion of atypical presentation. *J Urol* 1981; 126:437-42.
3. Kural AR, Akaydin A, Oner A, Ozbay G, Solok V, Oruc V, et al. Xanthogranulomatous pyelonephritis in children and adults. *Br J Urol* 1987; 59: 383-5.
4. Malek RS, Green LF, DeWeerd JH, Farrow GM. Xanthogranulomatous pyelonephritis. *Br J Urol* 1972; 44:296-308.
5. Goldman SM, Hartman DS, Fishman EK, Finizio JP, Gatewood OMB, Siegelman S. CT of xanthogranulomatous pyelonephritis. *AJR* 1984; 142:963-9.
6. Yazaki T, Ishikawa S, Ogawa Y, Takahashi S, Nemoto S, Rinsho K, et al. Xanthogranulomatous pyelonephritis in childhood: case report and review of English and Japanese literature. *J Urol* 1982; 127:80-3.
7. Ballesteros JJ, Faus R, Gironells J. Preoperative diagnosis of renal xanthogranulomatosis by serial urinary cytology: preliminary report. *J Urol* 1980; 124:9-11.
8. Parsons MA, Harris SC, Grainger RG, Ross B, Smith JAR, Williams JL. Fistula and sinus formation in xanthogranulomatous pyelonephritis. *Br J Urol* 1986; 58:488-93.
9. Grainger RG, Longstaff AJ, Parsons MA. Xanthogranulomatous pyelonephritis: a reappraisal. *Lancet* 1982; ii:1398-401.