

HEMANGIOMA OF THE ETHMOIDAL SINUSES

L E Loh, K H Ho, A Thoo, C Kwan

ABSTRACT

A report of a rare case of hemangioma of the ethmoidal sinuses with erosion of bony orbital wall and anterior cranial fossa. An outline of the management is presented.

Keywords: Ethmoidal hemangioma, pre-operative embolisation

SINGAPORE MED J 1994; Vol 35: 211-214

INTRODUCTION

Hemangioma of the upper respiratory tract is uncommon, least still is hemangioma of the nasal sinuses. A search of the literature uncovers only sporadic reports of cases of hemangioma of the nasal sinuses. This paper reports a case of ethmoidal hemangioma which necessitates a major surgery, cranio-facial resection, for complete excision.

CASE REPORT

OLK, a 20-year-old Chinese lady, presented in October 1991 with epistaxis in the left side of the nose for few months. Clinical examination revealed a fleshy mass in the middle meatus. The rest of the otolaryngological examination was unremarkable. Her vision was normal.

Computed tomography with contrast enhanced 5 mm thick contiguous coronal slices through the paranasal sinuses was carried out. It revealed a very vascular mass, occupying the region of the left ethmoidal sinuses, causing expansion of the sinuses with bony erosion, medially and superiorly. The medial wall (lamina papyracea) of the ipsilateral orbit was eroded in its posterior extent. Further, there was extension of the mass superiorly to involve the fovea ethmoidalis. The sphenoid sinus and the ipsilateral maxillary sinus exhibited evidence of obstructive sinusitis (Fig 1, 2 and 3).

Biopsy of the mass was undertaken under general anaesthesia. Histology revealed capillary-cavernous hemangioma.

Surgery, cranio-facial resection was planned, preceded by carotid angiography and embolisation the day before.

Department of Otorhinolaryngology
Tan Tock Seng Hospital
345 Jalan Tan Tock Seng
Singapore 1130

L E Loh, MBBS, FRCS, FAMS
Head and Consultant

Department of Neurosurgery
Singapore General Hospital
Outram Road
Singapore 0316

K H Ho, MBBS, FRCS, FAMS
Head and Senior Consultant

Department of Diagnostic Radiology
Singapore General Hospital

A Thoo, BA (Hon), MB B Chir, MA, MRCP, DMRD, FRCR
Senior Consultant

Department of Pathology
Singapore General Hospital

C Kwan, MBBS, FRCPA
Senior Registrar

Correspondence to: Dr L E Loh
3 Mt Elizabeth #14-17
Mt Elizabeth Medical Centre
Singapore 0922

Fig 1 – Vascular mass in ethmoidal sinuses

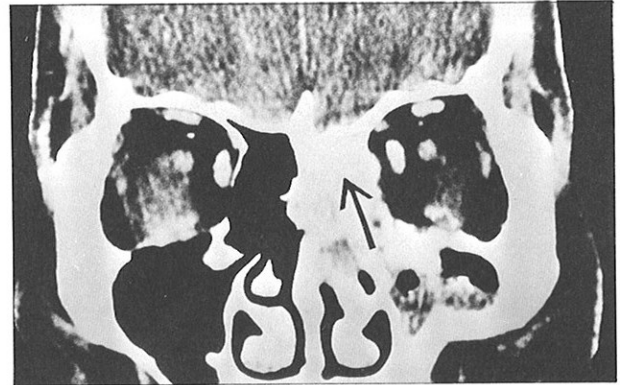
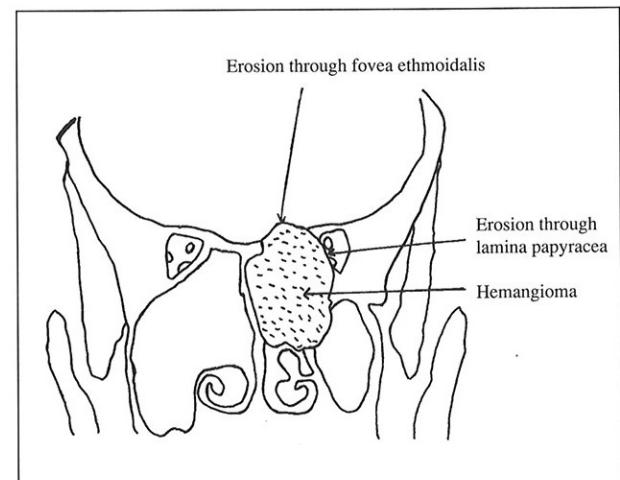


Fig 2 – Erosion of fovea ethmoidalis superiorly and lamina papyracea posteriorly

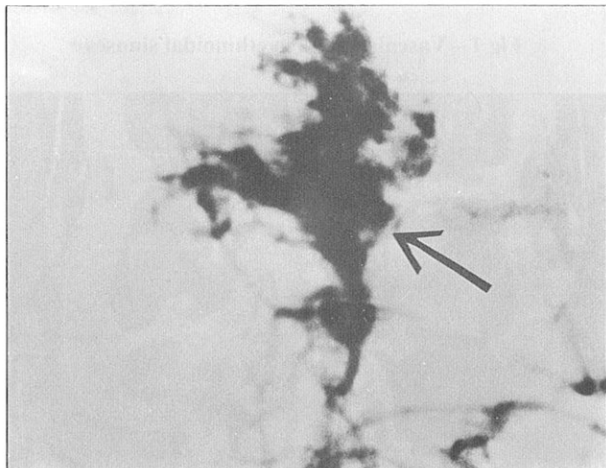


Fig 3 – Illustrative diagram of Fig 2



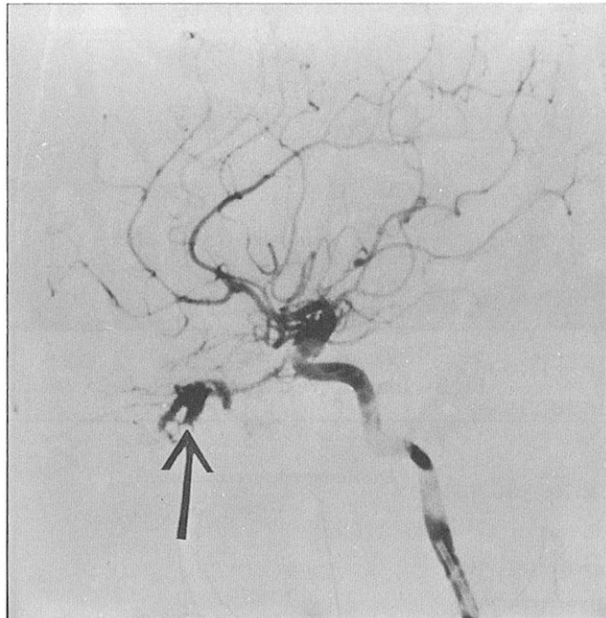
Bilateral external and internal carotid angiography was carried out. The left external carotid angiography revealed a hypervascular mass in the region of the left ethmoidal sinuses with evidence of contrast extravasation. The principal supply was from the left internal maxillary artery, both via its terminal branches and small pedicles arising from its proximal portion. The mass was embolised with gelfoam pledgets followed by occlusion of the internal maxillary artery with 2 x 2 mm and 3 mm steel coils. A 2 mm coil was employed to occlude the hypertrophic branch arising from the left superficial temporal artery (Fig 4).

Fig 4 – Left ECA injection - Pre-embolisation



The left internal carotid injection revealed some contribution from the hypertrophic ophthalmic branch, not amenable to embolic therapy (Fig 5).

Fig 5 – Left ICA injection



The right external carotid injection revealed a similar situation, albeit less pronounced than on the left. The right internal maxillary artery was embolised with 2 x 2 mm and 3 mm coils, preceded by gelfoam embolisation.

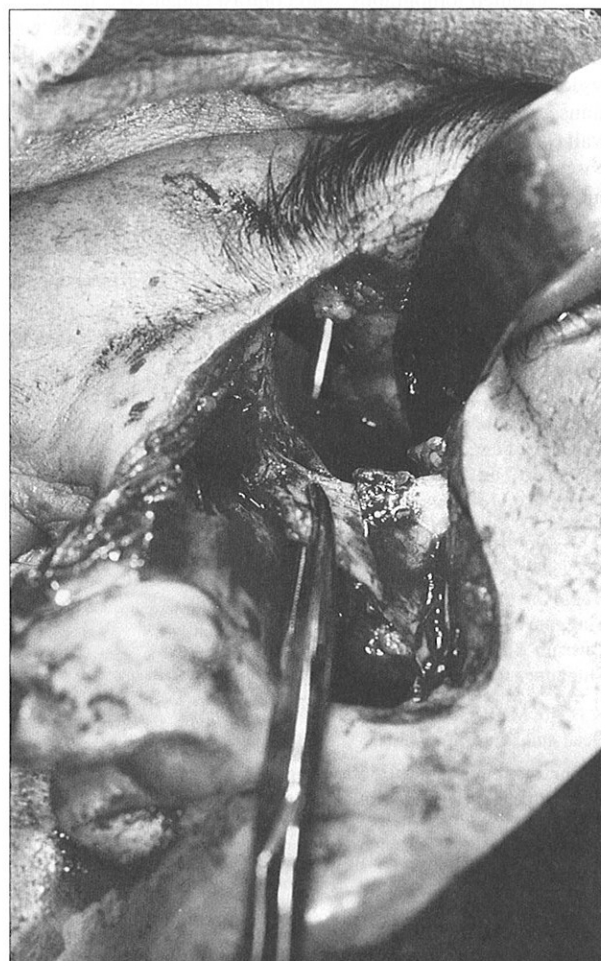
The right internal carotid injection was unremarkable.

Cranio-facial resection of the ethmoidal hemangioma was carried out via frontal craniotomy, ethmoidectomy with its fovea ethmoidalis and medial maxillectomy. Access was gained through bicoronal incision and lateral rhinotomy (Fig 6, 7 and 8).

Fig 6 – Frontal craniotomy – Frontal lobe retracted posteriorly revealing erosion of fovea ethmoidalis

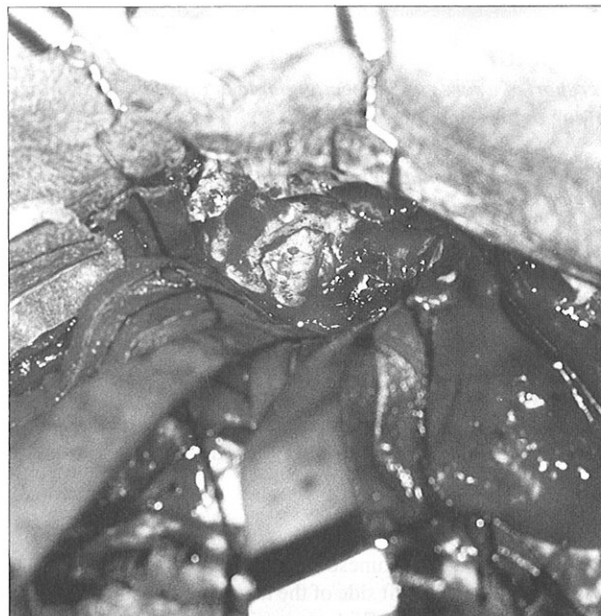

Fig 7 – Specimen removed via lateral rhinotomy



Intraoperatively, the hemangioma had eroded through the fovea ethmoidalis and posterior lamina papyracea. The dura and periorbita were intact. The optic nerve was a few millimetres away from the hemangioma. Orbital content was preserved. Despite pre-operative embolisation, there was continuous oozing through

the surgery. However, one must envisage the torrential bleed without embolisation.

Complete resection of the lesion was achieved. It measured 5 x 3 x 3 cm (Fig 9 and 10).

Fig 8 – Illustrative diagram of Fig 7

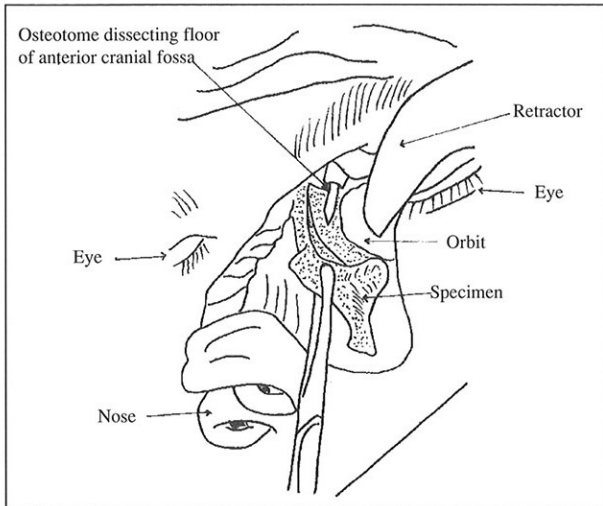


Fig 9 – Specimen

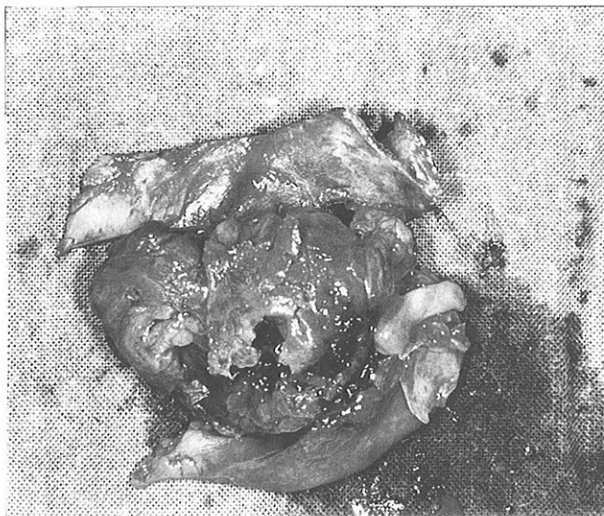
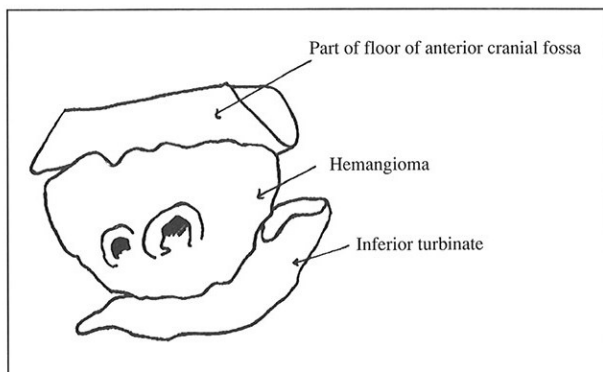


Fig 10 – Illustrative diagram of Fig 9



Microscopically, there were numerous small and cavernous vascular channels lined by flattened endothelium separated by a small amount of fibrous tissue. The vessels infiltrated into

existing lamellar bone. In some areas reactive formation was present around the vessels (Fig 11 and 12).

Fig 11 – The hemangioma is composed of a mixture of small and cavernous channels lined by endothelium

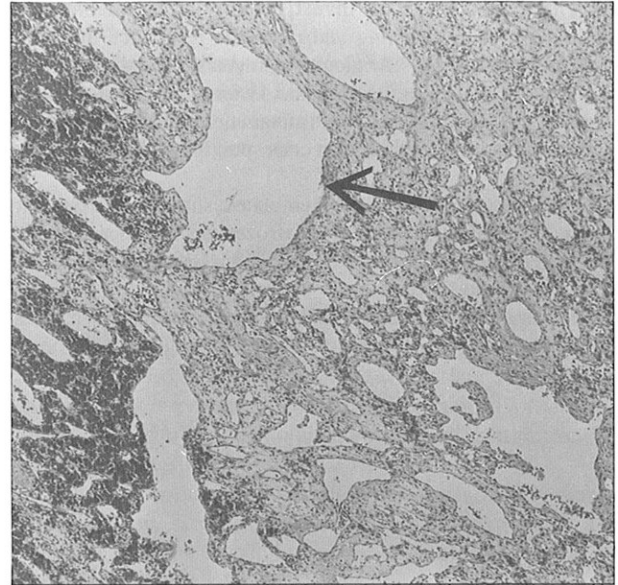
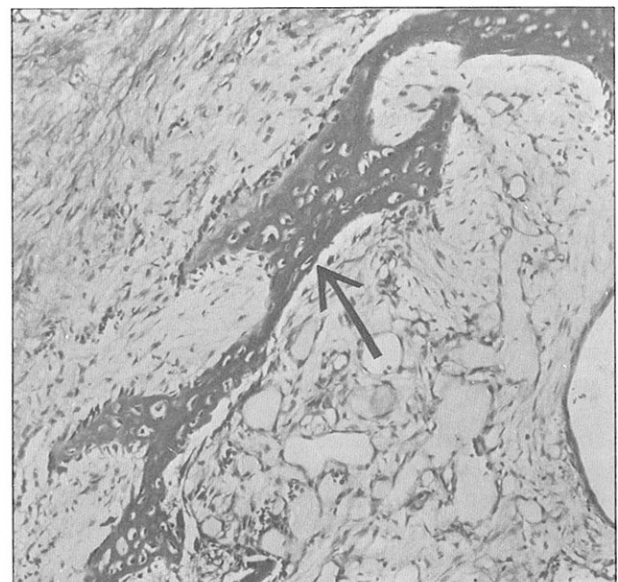

Fig 12 – Infiltration of the hemangioma into bone is seen with reactive new bone formation



DISCUSSION

Hemangioma may develop anywhere in the mucosa of the upper aerodigestive tract. The oral and nasal cavities are the most frequent sites.

Fu et al reported 156 cases of benign non-epithelial tumours. Of these, 38 (24%) are hemangioma. The majority of the cases are located on the nasal septum and turbinates. None in the ethmoidal sinuses⁽¹⁾.

Osborn reported 51 cases of nasal hemangioma. Again the majority are located on the nasal septum⁽²⁾.

A search of the literature uncovers only sporadic reports of hemangioma of the nasal sinuses. It can be seen that hemangioma of the sinuses is rare.

Hemangioma is considered by some people as hamartoma while others consider it benign neoplasm. Although spontaneous

regression can be anticipated in a significant percentage of hemangioma present at birth, in particular in cutaneous hemangioma, hemangioma presenting in adult is less likely to regress. Moreover, it may continue to grow, resulting in pressure necrosis of neighbouring vital organs such as the orbit in ethmoidal hemangioma.

Three modalities of investigations are available, viz angiography, CT scanning and magnetic resonance imaging. Each has its advantages. Angiography reveals the feeding vessels, CT scanning, enhancement of the lesion and its anatomical location and extent, while with magnetic resonance imaging, multiple flow voids in the lesion corresponding to its vascularity is diagnostic.

Pre-operative biopsy, if contemplated, should be carried out under anaesthesia. Pre-operative frozen section histology is useful as in some location the definitive surgery is major such as in this case report.

The treatment of choice remains complete excision with pre-

operative embolisation⁽³⁾. Sporadic success has been reported with other modalities of treatment viz cryosurgery injection of sclerosing agent and embolisation⁽⁴⁾.

ACKNOWLEDGEMENT

The authors wish to express their gratitudes to the Departments of Otolaryngology, Neurosurgery, Diagnostic Radiology and Pathology in Singapore General Hospital for the use of facilities and to the Secretary, Department of Otolaryngology, Tan Tock Seng Hospital, for her help in typing the manuscript.

REFERENCES

1. Fu YS, Perzin KH. Non-epithelial tumours of the nasal cavity, paranasal sinuses and nasopharynx: A clinicopathologic study. *Cancer* 1974; 33: 1275-88.
2. Obsorn DA. Hemangiomas of the nose. *J Laryngol Otol* 1959; 73: 174-8.
3. Biller HF, Krespi YP, Som PM. Combined therapy for vascular lesions of the head and neck with intra-arterial embolisation and surgical excision. *Otolaryngol Head Neck Surg* 1982; 90: 37-47.
4. Weimert TA, Gilmore BB. Multiple head and neck hemangiomas in the adult. A case report and review of the literature. *Otolaryngol Head Neck Surg* 1978; 82: 937-40.