

GIANT URETHRAL CALCULUS

Than Win

ABSTRACT

This is a case report of a 56-year-old Malay male presenting with a giant urethral calculus. The stone measuring 70 X 50 X 40 mm and weighing 45 g was impacted in the posterior urethra. The giant urethral calculus was removed successfully through external urethrotomy.

Keywords : Urethral calculus, perineal urethrotomy, retrograde urethrogram.

SINGAPORE MED J 1994; Vol 35: 414-415

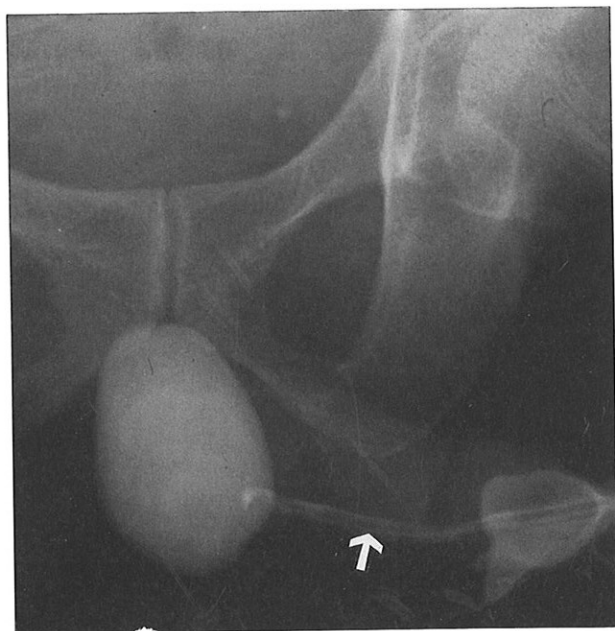
INTRODUCTION

Urethral stones are commonly associated with urinary tract calculi and underlying diverticula. A case is reported of a giant urethral calculus with symptoms of dysuria only. The patient denied ever having acute retention of urine.

CASE REPORT

A 56-year-old Malay male, presented with dysuria off and on of ten years' duration. He was a school teacher. The stone was readily palpable on the floor of the urethra and on rectal examination.

Fig 1 - Retrograde urethrogram reveals the smooth urethra (arrow) and a large calculus which is situated in a urethral pouch.



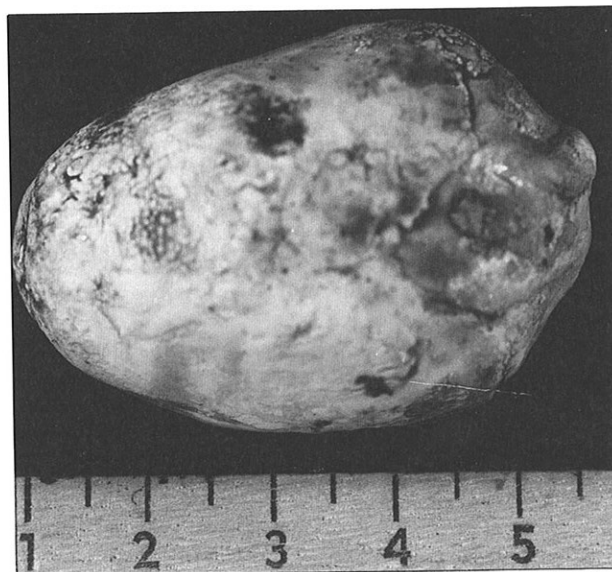Department of Surgery
School of Medical Sciences
Hospital Universiti Sains Malaysia
15990 Kubang Kerian
Kelantan
Malaysia

Than Win, MBBS, M Med Sc (Surgery)
Lecturer

Correspondence to : Dr Than Win
Lot 2644 Jalan Hospital
16150 Kubang Kerian
Kelantan
Malaysia

Retrograde urethrogram (Fig 1) showed a huge calculus situated in the posterior urethra. Associated urethral pathology was not found in a retrograde urethrogram. Intravenous urography showed normal kidneys, ureters and bladder. The urine was sterile. In September 1991 the calculus was removed under spinal anaesthesia by perineal urethrotomy. It measured 70 X 50 X 40 mm and weighed 45.0 g and was found to be impacted in the posterior urethra (Fig 2). A self-retaining catheter was placed in the urethra for ten days. The patient made a rapid and full recovery.

Fig 2 - Giant urethral calculus which presented as a perineal tumour. It measured 70x50x40 mm and weighed 45 g.



DISCUSSION

Urethral stone is a rare clinical entity and usually encountered in men with urethral stricture or diverticulum. They are exceedingly rare in females because of the low incidence of vesical calculi and their shorter urethra. Clinical diagnosis may be suspected if a stony hard mass is palpable on the floor of the urethra. The definitive diagnosis depends upon a plain X-ray film and a retrograde urethrogram. In urethral stone, a high incidence of urinary retention (89%) has been reported⁽¹⁾ but it could also be an uncommon occurrence⁽²⁾. Associated urinary tract calculi may be found⁽³⁾. A giant posterior urethral calculus measuring 72 X 49 X 52 mm associated with a urethral stricture had been reported⁽⁴⁾.

However, in this case report this patient presented with dysuria only. Urethral stricture or diverticulum was not

detected. Follow-up for one year showed no evidence of urethral stricture or recurrent stones. Management of the urethral calculi varied according to the site, size and associated urethral pathology. The treatment of choice for an impacted, large calculus in the posterior urethra is perineal urethrotomy.

REFERENCES

1. Amin HA. Urethral calculi. *Br J Urol* 1973; 45: 192-9.
2. Paulk SC, Khan AU, Makek RS, Greene LE. Urethral calculi. *J Urol* 1976; 116 : 436-9.
3. Sharfi AR. Presentation and management of urethral calculi. *Br J Urol* 1991; 68 : 271-2.
4. Bolukbasi A, Gunus B. Giant posterior urethral calculus. *Br J Urol* 1990; 65 : 301-2.