

# ELECTROCARDIOGRAPHIC CASE

## AN UNCOMMON CAUSE OF SYNCOPE

P P Goh, W S Teo

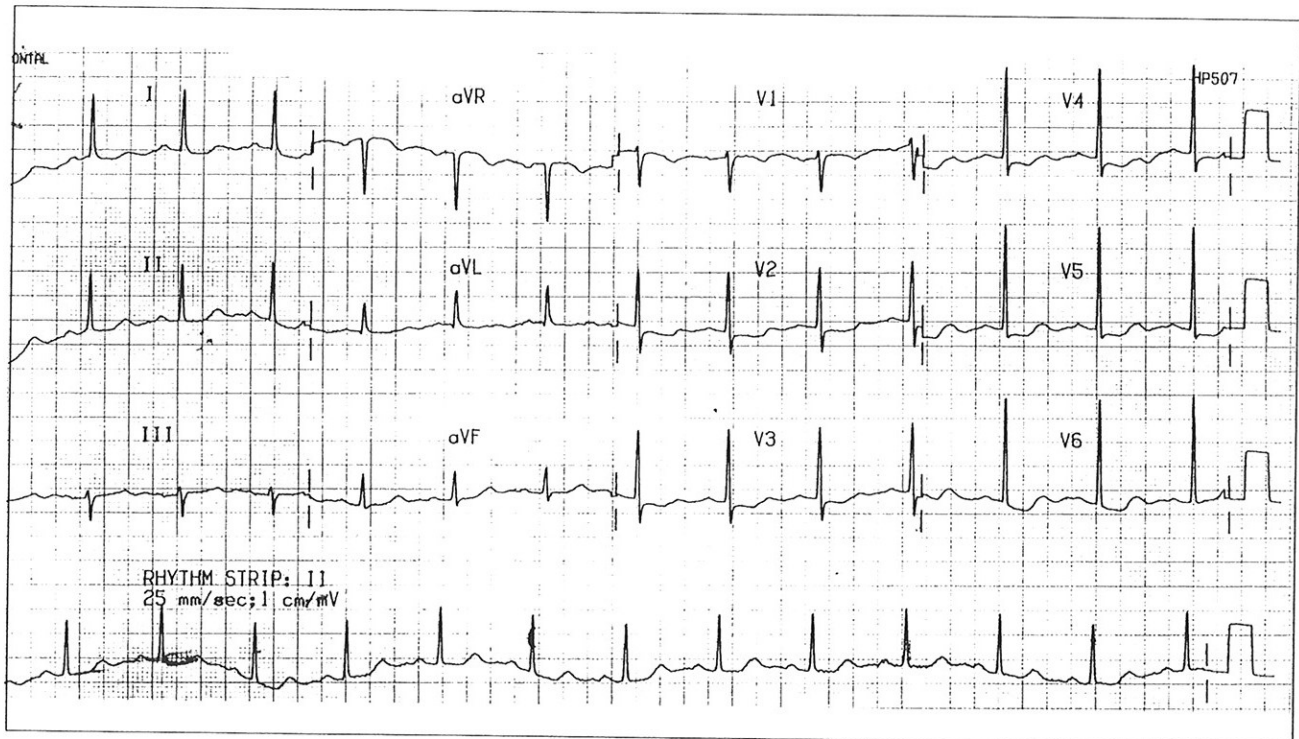
### CASE HISTORY

A 51-year-old lady presented with 6 episodes of palpitations followed by syncope over a 5-month duration. She had no angina or cardiovascular risk factor and no family history of sudden death.

Her resting 12-lead electrocardiogram on initial presentation is shown in Fig 1. What is the cause of her recurrent syncope? (Answer on Page 428)

SINGAPORE MED J 1994; Vol 35: 403 & 428

Fig 1 - 12-lead electrocardiogram at initial presentation



Department of Cardiology  
Singapore General Hospital  
Outram Road  
Singapore 0316

P P Goh, MBBS, MRCP (UK)  
Registrar

W S Teo, MBBS, M Med (Int Med), MRCP (UK), FAMS  
Consultant

Correspondence to: Dr W S Teo