

ELECTROCARDIOGRAPHIC CASE

IRREGULAR BROAD COMPLEX TACHYCARDIA

C Y Lee, W S Teo

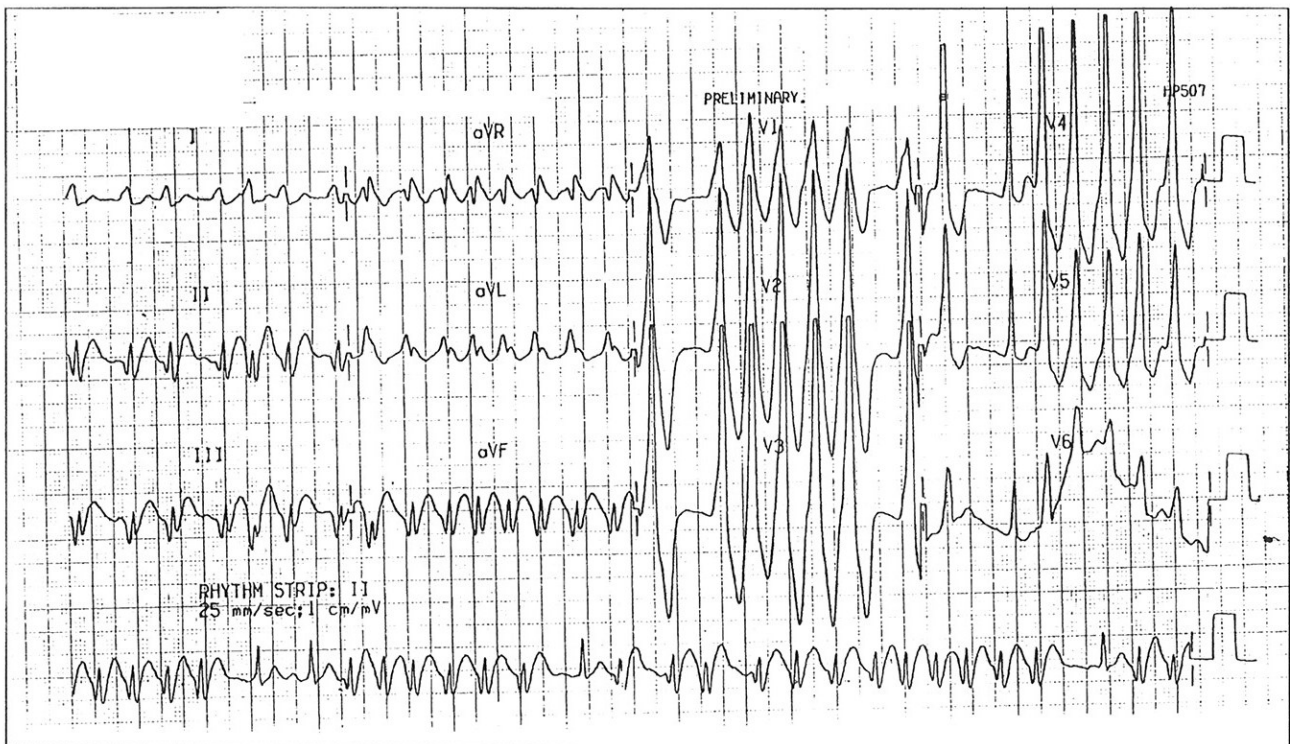
CASE REPORT

A 51-year-old man was admitted with a complaint of palpitations and feeling unwell. He gave a history of recurrent palpitations for around 20 years without any accompanying syncope or presyncope. His blood pressure was 105/78 mmHg.

Fig 1 shows the admitting ECG; Fig 2 shows the ECG after the patient was given intravenous Flecainide. What is your diagnosis and line of management? (Answer on pages 655-656)

SINGAPORE MED J 1994; Vol 35: 635-636 & 655-656

Fig 1 – 12 lead electrocardiogram of the patient at the Accidents and Emergency Department



Department of Cardiology
Singapore General Hospital
Outram Road
Singapore 0316

C Y Lee, MBBS, M Med (Int Med)
Registrar

W S Teo, MBBS, M Med (Int Med), MRCP (UK), FAMS
Consultant

Correspondence to: Dr W S Teo

Fig 2 – 12 lead electrocardiogram of the patient after intravenous Flecainide

