

# FAILED BACK SURGERY SYNDROME: DIFFERENTIATING EPIDURAL FIBROSIS AND RECURRENT DISC PROLAPSE WITH Gd-DTPA ENHANCED MRI

Y F Fan, V F H Chong, S K Tan

## ABSTRACT

*The failed back surgery syndrome (FBSS) is a difficult diagnostic problem. Two of the more common causes of FBSS are epidural fibrosis and recurrent disc prolapse. Forty-five gadolinium-diethylenetriaminepenta-acetic acid (Gd-DTPA) enhanced magnetic resonance (MR) scans were performed on 43 patients to evaluate the effectiveness in differentiating recurrent disc prolapse from epidural fibrosis. Operative findings were available in 11 patients and they confirmed the pre-operative radiological diagnosis of recurrent disc prolapse in 6, epidural fibrosis in 4 and facet joint hypertrophy in 1 patient. Although the number of surgically verified cases is small, our initial experience of 100% diagnostic accuracy reflects the tremendous potential of this investigative tool. Separating epidural fibrosis from recurrent disc prolapse is crucial as patients with the former are expected to benefit from further surgery. Patients with epidural fibrosis, on the other hand, generally do not gain relief from another operation.*

*Keywords: spinal surgery, gadolinium, intervertebral disc, scarring, MR studies.*

SINGAPORE MED J 1995; Vol 36: 153-156

## INTRODUCTION

The failed back surgery syndrome (FBSS) is characterised by varying degrees of pain and functional incapacitation following surgery for low back pain. It has been reported to occur in 10%-40% of patients<sup>(1)</sup>. There are many causes of FBSS and they include recurrent disc prolapse, epidural fibrosis, spinal stenosis, arachnoiditis, meningocele formation, mechanical instability, nerve injury and surgery at the wrong level. FBSS is a difficult diagnostic problem clinically and radiologically. Plain radiographs are seldom helpful and they show only bony changes secondary to laminectomy or spinal fusion. Arachnoiditis can be diagnosed myelographically but differentiating epidural scar and recurrent disc prolapse is difficult<sup>(2)</sup>. Two of the commoner causes of FBSS are scar formation and recurrent disc prolapse. Computed tomography (CT) with intravenous contrast may separate scar and disc with a reported accuracy of 67%-100%<sup>(3,4)</sup>. However, this technique involves a high contrast load and images in only a single plane is possible. Recent development in MR imaging techniques especially with Gd-DTPA has produced encouraging results<sup>(5)</sup>.

## PATIENTS AND METHOD

Forty-five scans were performed on 43 patients with FBSS in a prospective study over a 14-month period. In all patients the initial indication for surgery was intervertebral disc prolapse.

Two patients had 2 scans performed. There were 24 (56%) males and 19 (44%) females and the average age was 41.6 years (range 20-78 years). The interval between surgery and imaging averaged 3.3 years (range 1 month - 14 years).

The patients were examined on a Siemens Magnetom Impact 1.0 tesla scanner. Sagittal spin echo (SE) scans were performed using T1-weighted (500/15; repetition time [TR] msec; echo time [TE] msec) and T2-weighted (TR 2200/20/80) sequences. The slice thickness was 4mm with an interslice gap of 10% (0.4mm). The imaging matrices used were 256x256 and 192x256 for the sagittal and axial sections respectively. Three excitations were used in the T1-weighted images while only one excitation was employed in the T2-weighted sequence. Plain axial and contrast (Magnevist 0.1 mmol/kilogram body weight) scans were also obtained. In the contrast enhanced examinations, scanning was performed immediately after the injection of contrast with no significant delay. Surgical findings were available in 11 patients for radiological correlation.

A diagnosis of recurrent disc is based on the presence of a soft tissue mass which appears to be in contiguity with the parent disc. When the prolapsed disc is large enough, space occupying effect may be seen. It should show no contrast enhancement and of low signal intensity in the T2-weighted sequence. A diagnosis of epidural scar is made in the presence of a soft tissue mass with contrast enhancement. Epidural fibrosis may or may not be associated with space occupying effect. It should also be of low signal intensity in the T2-weighted sequence. Recurrent disc prolapse may be associated with epidural fibrosis. This diagnosis is made in the presence of a non-enhancing soft tissue mass surrounded by an enhancing lesion.

## RESULTS

The MRI findings in all the scans performed are presented in Table I. In 15 patients (33.3%) recurrent disc prolapse was diagnosed. Fig 1a is a sagittal T1-weighted scan showing a low signal intensity lesion in contiguity with the degenerated L4/L5 intervertebral disc. Significant indentation of the thecal sac is noted. Fig 1b is an axial pre-contrast study through L4/L5 showing a soft tissue lesion on the left side with displacement of the thecal sac posteriorly and medially. Following the injection of contrast, the lesion showed no appreciable enhancement

---

Department of Diagnostic Radiology  
Singapore General Hospital  
Outram Road  
Singapore 0316

Y F Fan, MBBS, FRCR  
Consultant

V F H Chong, MBBS, FRCR  
Consultant

Department of Orthopaedic Surgery 'O'  
Singapore General Hospital

S K Tan, MBBS, FRCS, FAMS  
Senior Consultant & Head

Correspondence to: Dr Y F Fan

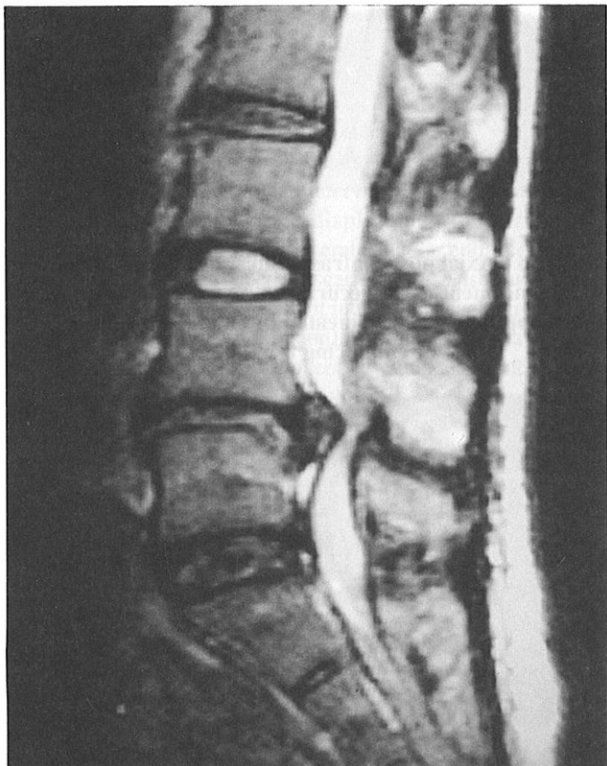---

indicating the presence of a large recurrent disc prolapse.

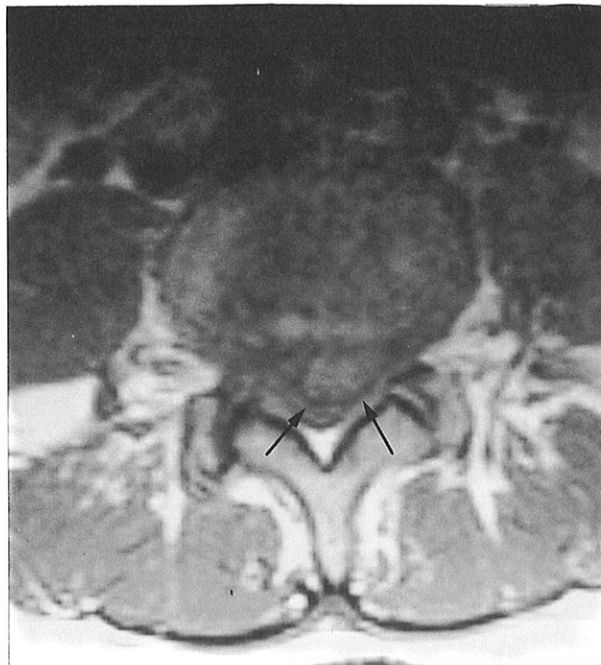
**Table I – MRI diagnosis of failed back surgery syndrome**

Diagnosis	No. of scans	Percentage
Epidural fibrosis	15	33.3%
Recurrent disc prolapse	15	33.3%
Epidural fibrosis and recurrent disc prolapse	8	17.8%
No abnormal soft tissue	2	4.5%
Others	5	11.1%
Total	45	100%

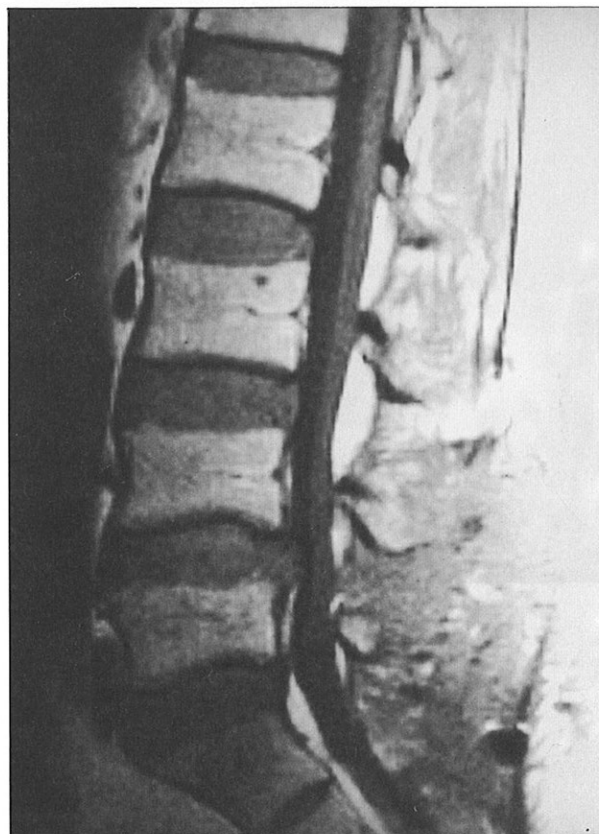**Fig 1a – T1-weighted sagittal scan illustrating a low signal intensity lesion at level L4/L5 with significant space-occupying effect.**



**Fig 1b – Axial T1-weighted scan showing a low signal intensity lesion (arrows) impinging the thecal sac on the left side.**



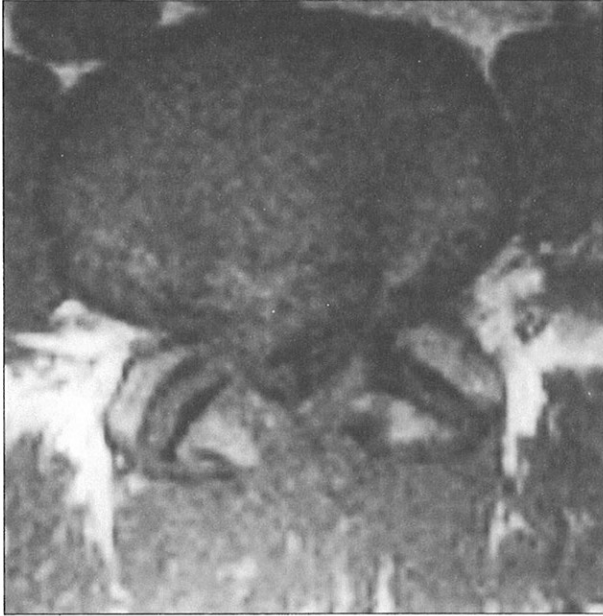**Fig 2a – Sagittal T1-weighted image showing a soft tissue lesion isointense with intervertebral disc impinging the thecal sac at level L4/L5.**



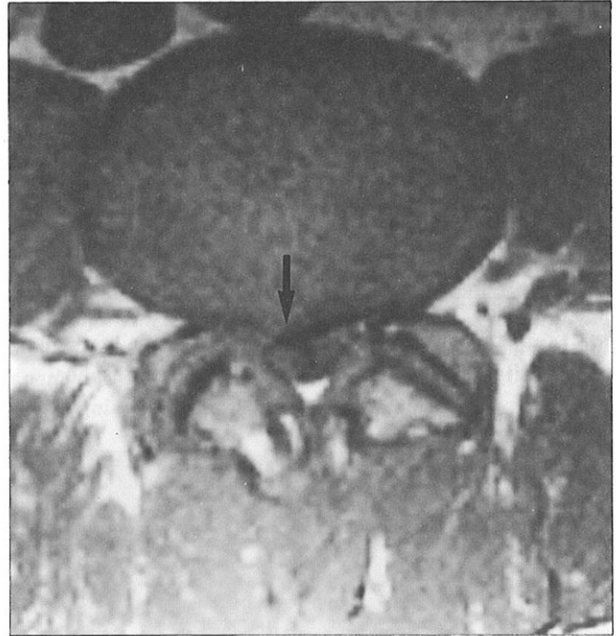
There were another 15 (33.3%) patients with MRI diagnosis of postoperative epidural fibrosis. Fig 2a shows a T1-weighted sagittal scan of a soft tissue mass isointense with intervertebral disc at level L4/L5 impinging the thecal sac. In the T1-weighted axial section (Fig 2b), an isointense mass on the right side of the spinal canal could be seen. No epidural fat planes were evident and the demarcation between this lesion and the thecal sac could not be established. Following the injection of contrast, there was intense enhancement of the epidural scar tissue with good delineation from the displaced thecal sac (Fig 2c).

The diagnosis of recurrent disc prolapse and epidural scarring are not mutually exclusive. Eight (17.8%) patients in this series showed both epidural scarring and recurrent disc prolapse. Fig 3a and 3b (same patient as in Fig 2a, b and c) are axial pre and post contrast images obtained one section superiorly. A right soft tissue lesion with no contrast enhancement is noted indicating the presence of recurrent disc prolapse.

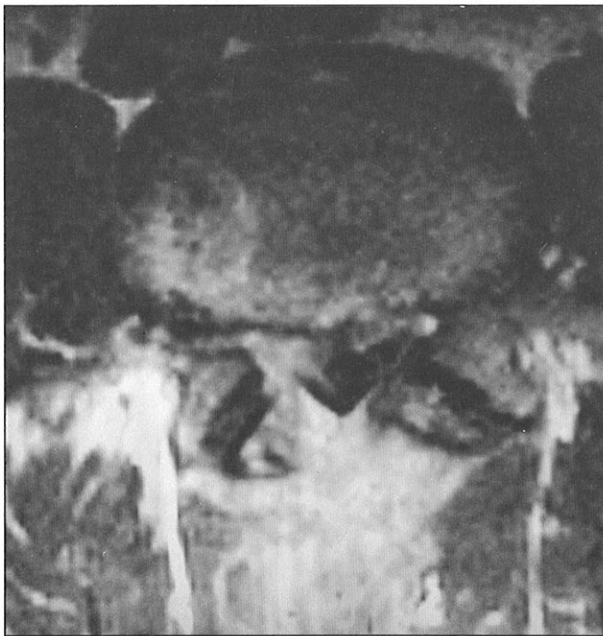
**Fig 2b – Axial T1-weighted image showing the loss of epidural fat planes and the presence of a lesion on the right side of the spinal canal.**



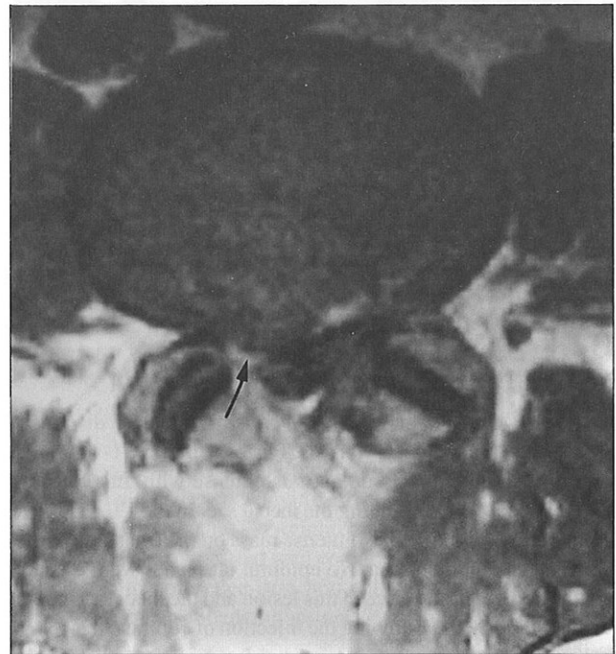
**Fig 3a – T1-weighted axial image one section superior to Figs 2a and b showing a lesion on the right side of the spinal canal (arrow)**



**Fig 2c – Axial post contrast scan demonstrating intense enhancement of epidural scar tissue.**



**Fig 3b – Axial post contrast scan showing no contrast enhancement in the recurrent disc (arrow). The disc appears better delineated by the surrounding enhancing fibrosis.**



Two patients had scans interpreted as normal. There were 5 patients with no evidence of either recurrent disc prolapse or epidural fibrosis. The observations in this group include spinal stenosis due to a combination of facet joint osteophytosis and hypertrophy of the ligamentum flavum, epidural cyst and arachnoiditis.

Operative findings were available in 11 patients and they confirmed the pre-operative radiological diagnosis of recurrent disc prolapse in 6, epidural fibrosis in 4 and facet joint hypertrophy in one patient.

## DISCUSSION

The failed back surgery syndrome is a relatively common disorder. Before the advent of CT and MRI, the differentiation between recurrent disc prolapse and epidural fibrosis was difficult. Although high dose contrast enhanced CT scan showed promising results, the published accuracy varied between 67% and 100%<sup>(3,4)</sup>. This technique is not universally adopted and, in the Singapore General Hospital, seldom employed. Both CT and MR differentiation between disc and fibrosis is based on the vascularity of the tissues concerned<sup>(6,7)</sup>. Intervertebral disc is relatively avascular and therefore contrast enhancement is not expected. On the other hand, the increased vascularity within scar tissue is reflected by contrast enhancement.

Recurrent disc prolapse presents itself as a soft tissue mass within the spinal canal or the intervertebral foramina. If large enough it may demonstrate displacement of nerve roots. Recurrent disc may show peripheral irregular enhancement and this is due to disc wrapped in scar tissue<sup>(8)</sup>. Disc may show a variable amount of enhancement in delayed scans (greater than 30 minutes post contrast infusion). This phenomenon is related to contrast diffusion from adjacent vascularised tissues into the capacious extracellular spaces of the relatively avascular disc. It is, therefore, important to scan the patient as soon as possible after the administration of contrast to avoid possible confusion.

Scar tissue enhances and this observation may be present in patients whose surgery may have taken place more than 20 years ago<sup>(5)</sup>. The peak enhancement of scar tissue is 5-6 minutes after contrast injection. Hence, early scanning for accurate diagnosis is mandatory especially when disc is known to enhance in delayed scans. Although scar is generally believed to demonstrate

retraction, a space occupying effect may also be seen. As such, space occupying effect should not be used as a major discriminator of disc and scar<sup>(3,4,8)</sup>.

Recurrent disc prolapse and epidural fibrosis may coexist and they are not mutually exclusive. This coexistence may be demonstrated by the combination of enhancement characteristics of disc and scar. This is not an uncommon finding and may be seen in up to 55% of cases<sup>(8)</sup>.

In a study of 44 patients with 50 re-operated levels by Hueftle et al<sup>(8)</sup>, Gd-DTPA enhanced MRI demonstrated 96% accuracy in identifying the difference between scar and disc. The results of our initial experience is most encouraging. The number of surgically proven cases are small (n=11) and a 100% diagnostic accuracy does seem disturbing. Further experience will be required to confirm the tremendous value of contrast enhanced MRI in the differentiation of recurrent disc prolapse and postoperative epidural fibrosis.

## CONCLUSION

Before the advent of MRI and the introduction of paramagnetic contrast media, the postoperative lumbar spine was a difficult area to evaluate. Gd-DTPA enhanced MRI is now the method of choice in studying cases of failed back surgery syndrome. Our initial experience appears to be in line with the encouraging results of other investigators.

## REFERENCES

1. Burton CV, Kirkaldy-Willis WH, Yong-Hing K, Heithoff KB. Causes of failure of surgery on the lumbar spine. *Clin Orthop* 1981; 157:191-9.
2. Quencer RM, Tenner M, Rothman L. The postoperative myelogram. *Radiology* 1977; 123:667-79.
3. Teplick JG, Haskin ME. Computed tomography of the postoperative lumbar spine. *AJR* 1983; 141:865-84.
4. Braun IF, Hoffman JC, Davis PC, Landman JA, Tindall GT. Contrast enhancement in CT differentiation between recurrent disk herniation and postoperative scar: prospective study. *AJNR* 1985; 6:607-12.
5. Ross JS, Modic MT. Current assessment of spinal degenerative disease with magnetic resonance imaging. *Clin Orthop* 1992; 279:68-81.
6. Schubiger O, Valvanis A. CT differentiation between recurrent disc herniation and postoperative scar formation: the value of contrast enhancement. *Neuroradiology* 1982; 22:251-4.
7. Weiss T, Treish J, Kazner E, Kohler D, Collmann H, Claussen C. CT of the postoperative lumbar spine: the value of intravenous contrast. *Neuroradiology* 1986; 28:241-5.
8. Hueftle MG, Modic MT, Ross JS, Masaryk TJ, Carter JR, Wilber RG, et al. Lumbar spine: Postoperative imaging with Gd-DTPA. *Radiology* 1988; 167:817-24.