

Paradoxical Enlargement of Tuberculous Brain Abscess during Drug Treatment: A Case Report

S K Ng, X L Zhu, W S Poon

ABSTRACT

This is a case report of a patient suffering from tuberculous (TB) brain abscesses. Despite supervised and appropriate anti-TB chemotherapy, the size of the abscesses paradoxically increased, accompanied by clinical deterioration at 1 month. A second aspiration was performed which yielded a large amount of viable tubercle bacilli. The same drug regimen was continued. This was followed by complete resolution of the lesions in 12 months. Hence TB brain abscess which remains culture and smear positive after four weeks treatment may not represent treatment failure.

Keywords: tuberculous, brain abscesses, paradoxical deterioration

Singapore Med J 2001 Vol 42(7):325-327

INTRODUCTION

Paradoxical enlargement of tuberculoma during anti-tuberculous (TB) treatment is documented⁽¹⁻³⁾ and may not represent treatment failure because hypersensitivity reaction may play an important role. For TB brain abscess, treatment experience is much less⁽⁴⁾ and there is no documented data on when the pus becomes sterile after treatment.

CASE REPORT

A 50-year-old man with known alcoholic cirrhosis presented to a local hospital with left-sided focal convulsion. Computerized tomography (CT) of the brain with intravenous contrast showed ring-enhancing intracerebral lesions (Fig. 1a, b). The three lesions were situated in the right frontal lobe, the left frontal lobe near the corpus callosum and one was near the vertex. Besides the left-sided focal convulsion, he also reported a recent weight loss. He was afebrile and physical examination revealed no organomegaly, abnormal mass or palpable lymph node nor any focal neurological signs. His erythrocyte sedimentation rate was 127 mm/hour and alkaline phosphatase was 198. Chest X ray did not show any evidence of tuberculosis or lung tumor.

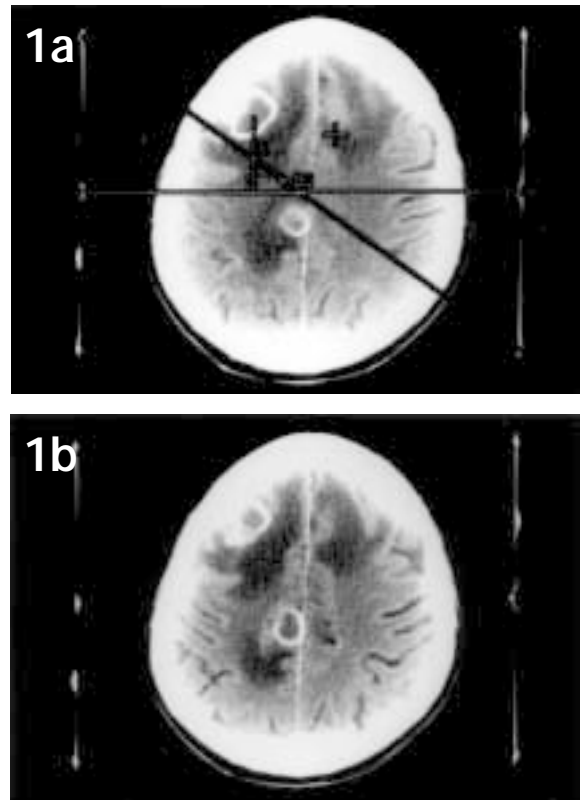


Fig. 1a, b The CT appearance of the TB brain abscesses (ring enhancing lesions) before anti-TB treatment.

CT-guided stereotactic biopsy of the right frontal lesion was carried out which yielded 3 ml of non-foul smelling, yellowish pus. Smear and culture of the pus confirmed the diagnosis of TB brain abscess.

A 4-drug regimen was commenced which include ethambutol 400 mg bd, isoniazid 300 mg qd, pyrazinamide 1.5 g qd and rifampicin 45 mg qd. The above dosage was adjusted taking into account of the patient's liver dysfunction. He showed initial improvement with better general well-being and falling ESR.

However, four weeks after commencement of the anti-TB chemotherapy, he deteriorated with confusion and spastic left hemiparesis. CT brain scan showed paradoxical increase in size of the brain abscesses (Fig. 2a, b). There was also marked surrounding edema. A second ultrasound-guided aspiration was

Division of
Neurosurgery
Department of
Surgery
The Chinese
University of
Hong Kong
Prince of Wales
Hospital
Shatin, New
Territories
Hong Kong

S K Ng, FRCS
Medical Officer

X L Zhu, FRCS
Senior Medical Officer

W S Poon, FRCS
Professor

Correspondence to:
Dr W S Poon
Tel: (852) 2632 2624
Fax: (852) 2637 7974

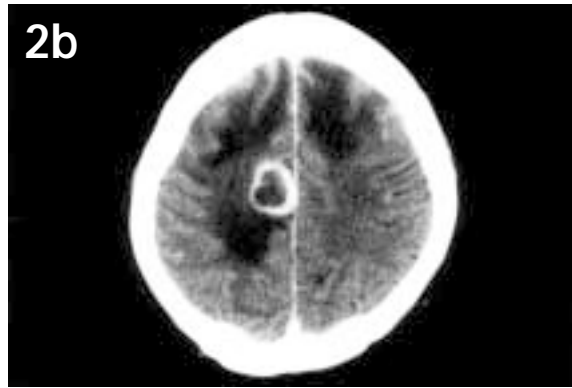
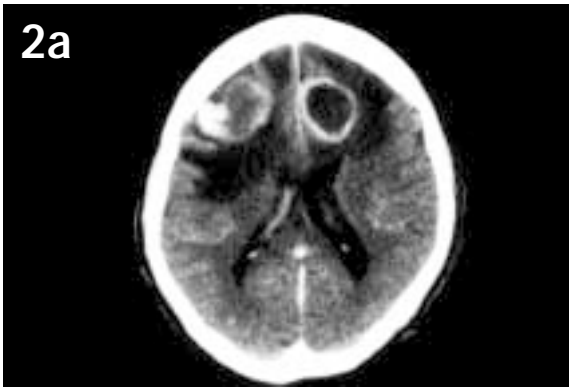


Fig. 2a, b Increase in size of the abscesses at 1 month after anti-TB chemotherapy.

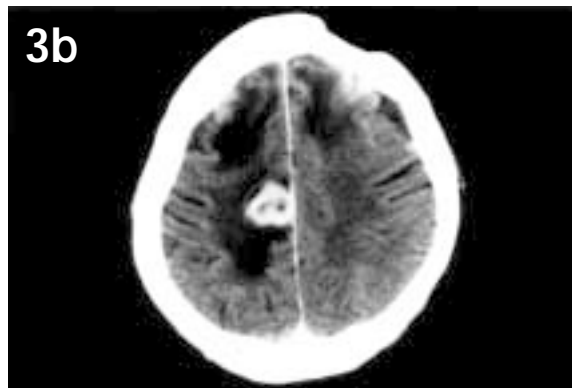
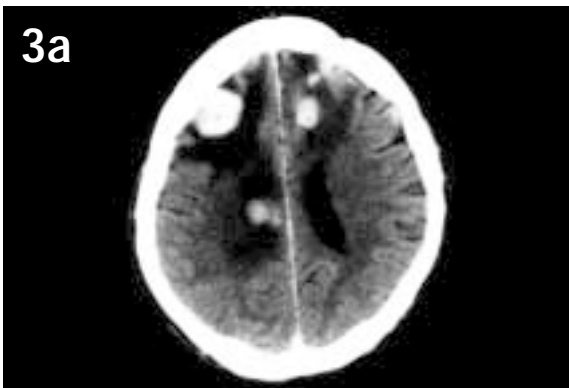


Fig. 3a, b The abscesses decreased in size and became homogeneously enhanced at 3 months after treatment.

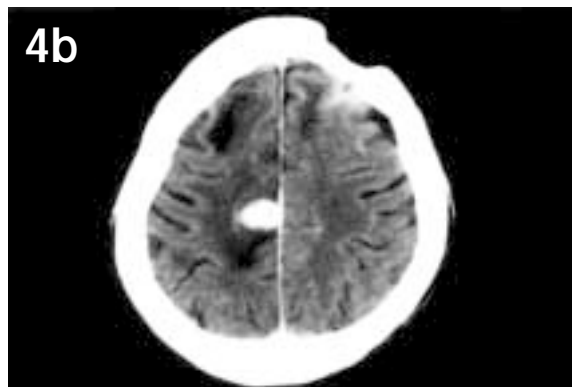
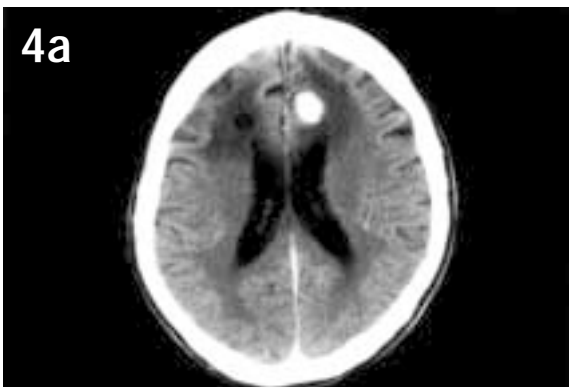


Fig. 4a, b Further reduction in size of the intracranial lesions at 5 months after treatment.

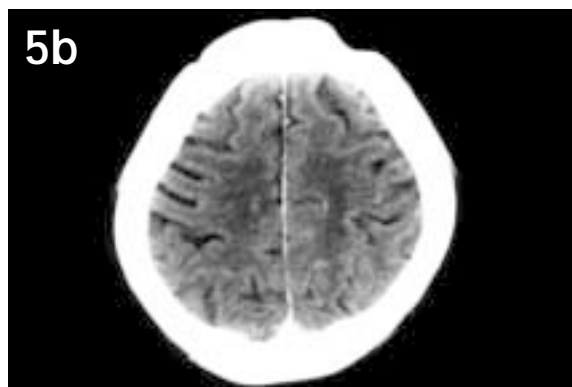
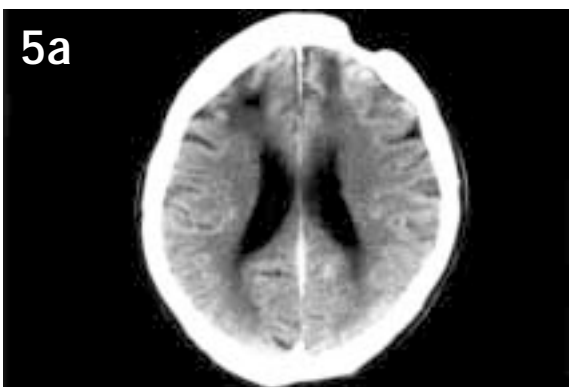


Fig. 5a, b Disappearance of the lesions at 1 year after treatment.

performed to alleviate the raised intracranial pressure. 15 ml pus was aspirated which contained large numbers of viable TB bacilli (smear and culture positive). Both the first and second specimens were proven to be sensitive to the drugs prescribed. Thus the same regimen was continued. The patient was then transferred to the convalescent hospital for active rehabilitation. Serial follow-up CT brain scans showed reduction in size of the lesions (Fig. 3 and 4) and the pattern of contrast enhancement became homogeneous. At one year, his activities of daily living were totally independent and he was able to walk unaided on level ground with the lesions completely resolved on CT scans (Fig. 5).

DISCUSSION AND CONCLUSION

Tuberculous brain abscess is rare and treatment experience is limited. This case demonstrated that paradoxical enlargement of the lesion during a course of medical treatment is possible. Even when this is associated with viable organisms at four weeks after treatment, this does not represent treatment failure.

There is no consensus on the standard treatment of TB brain abscess. Some perform surgical excision in addition to chemotherapy⁽⁴⁾. But this may be difficult

and would be likely to cause significant morbidity and mortality for those with multiple deep-seated abscesses. Some attempt intralesional anti-TB chemotherapy but multiple TB brain abscesses developing along the path of the catheter has been reported⁽³⁾. In our case, combined medical therapy and repeated aspiration of the enlarging abscess was found to be effective⁽⁵⁾.

ACKNOWLEDGEMENT

We would like to thank Ms Shirley Chiu for her kind clerical support.

REFERENCES

1. Chambers ST, Hendrickse WA, Record C, Rudge P, Smith H: Paradoxical expansion of intracranial tuberculoma during chemotherapy. *Lancet* 1984; 2:181-4.
2. Afahani B, Lieberman JM: Paradoxical enlargement or development of intracranial tuberculomas during therapy: case report and review. *Clin infectious disease* 1994; 19(6):1092-9.
3. de Castro CC, de Barros NG, de Sousa Campos ZM, Cerri GG: CT scans of cranial tuberculosis: *Radiologic Clinics Of North America* 1995; 33(4):753-67.
4. Ildan F, Gursoy F, Gul B, Boyar B, Kilic C: Intracranial abscess mimicking malignant glioma. *Neurosurg. Rev.* 1994; 17:317-20.
5. Tang ESC, Chau A, Fong D, Humphries MJ: The treatment of multiple intracranial tuberculous abscesses: a case report. *Journal of Neurology* 1991; 238:183-5.