



Permit No MITA (P) 265/09/00
ISSN 0037 - 5675

JOURNAL OF THE SINGAPORE
MEDICAL ASSOCIATION

Editor

Dr C Rajasoorya

Deputy Editor

A/Prof Sonny Wang Yee Tang

Corresponding Editors

Prof Azrul Azwar (Indonesia)
Prof Myo Myint (Myanmar)
Prof Neil Pride (UK)
Prof Tan Chong Tin (Malaysia)
Prof Teh Bin Tean (USA)
Prof Victor Yu (Australia)

Editorial Board

A/Prof Ho Nai Kiong
Prof Kua Ee Heok
Dr Kenneth Lyen
Dr Denis Nyam
Dr Wilfred C G Peh
Dr Paul Ananth Tambyah
A/Prof Luke Tan Kim Siang
Dr Jackie Tan Yu Ling

Ex-Officio

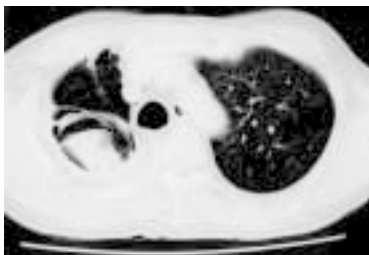Prof Low Cheng Hock
Dr Yue Wai Mun

Editorial Assistants

Chua Gek Eng
Dr Tham Wai Fong, Eileen

Editorial Address

Dr C Rajasoorya, Editor
Singapore Medical Journal
Singapore Medical Association
2 College Road
Singapore 169850



Cover Picture:
CT of the thorax shows a crescent-shaped cleft of air surrounding a well-defined pulmonary nodule. There is adjacent lung scarring.
(Refer to page 390-393)

Lupus the Great Mimic: Gastrointestinal Manifestations

H H Chng

Systemic lupus erythematosus (SLE) is a fascinating multi-systemic autoimmune connective tissue disease. Its many varied presentations and manifestations are often a challenge to the Rheumatologist in both diagnosis and management and not infrequently, other specialists have to be called upon for assistance.

This disease commonly affects the gastrointestinal (GI) system. In 1895, William Osler was the first to emphasize that GI manifestations may overshadow other manifestations of the disease and mimic any other type of abdominal condition⁽¹⁾. Just over a hundred years later, in a comprehensive review of the gastrointestinal manifestations of SLE, Sultan and co-authors also concluded that SLE is a great mimic of many GI conditions⁽²⁾. The three cases of different GI involvement of lupus reported in this issue of the journal by Luman and co-authors illustrate this⁽³⁾.

Dubois and Tuffanelli in their study of 520 SLE patients reported 53% of their patients had nausea and vomiting, 49% anorexia and 19.2% abdominal pain⁽⁴⁾. Diarrhoea was reported in 25% of Fries and Holman's series of 184 lupus patients⁽⁵⁾. These symptoms may be due to SLE disease activity, side effects of medications, stress related mucosal disease (gastritis) or any intercurrent illness (such as an infective gastroenteritis). Non-steroidal anti-inflammatory drugs (NSAIDs), corticosteroids, hydroxychloroquine, azathioprine, methotrexate, mycophenolate mofetil and cyclophosphamide are drugs used in the treatment of active lupus and all may cause such symptoms. Lupus patients often have other associated autoimmune connective tissue disorders and these too may affect the GI tract. Abdominal symptoms of bowel ischaemia, infarction or perforation in a lupus patient may rarely be the result of mesenteric artery thrombosis due to secondary antiphospholipid syndrome. Sjogren's syndrome which occurs in about 20% of lupus patients may also account for the complaints of nausea, dysphagia and epigastric pain.

Table I lists the gastrointestinal manifestations of SLE. The most common GI lesion occurs in the oral cavity while rectal involvement is rare probably because of its rich and dual source of blood supply. The true frequency of inflammatory bowel diseases (IBD); ulcerative colitis, Crohn's disease and celiac disease in patients with lupus is not known and larger studies are required to assess this. It should be kept in mind that drugs used in the treatment of IBD, sulphasalazine, tetracycline and trimethoprine-sulphur may induce lupus^(2,6).

The main gastrointestinal complication that may potentially cause severe morbidity and mortality is gastrointestinal vasculitis. It commonly presents with symptoms of abdominal pain, nausea, vomiting and diarrhoea as in case 1 of Luman et al's report of three cases of GI manifestations⁽³⁾.

Department of
Rheumatology,
Allergy &
Immunology
Tan Tock Seng
Hospital
11 Jalan Tan
Tock Seng
Singapore 308433

H H Chng, MBBS,
MMed (Int Med),
FRCP (Glasg), FAMS
Clinical Associate
Professor
Tel: (65) 357 7822
Fax: (65) 357 7837
Email: hiok_hee_chng@
notes.ttsh.gov.sg

Table 1. Gastrointestinal manifestations of systemic lupus erythematosus.

SITE	MANIFESTATION
Oral Mucosa	: ulcers, erythematous lesions
Esophagus	: dysmotility with dysphagia & acid reflux, vasculitis
Stomach	: dysmotility with dyspepsia and gastric outlet obstruction, vasculitis
Large & small intestine	: vasculitis with ischaemia, infarction, perforation, ulceration & haemorrhage, thrombosis, dysmotility with pseudo-obstruction, malabsorption, protein losing enteropathy, pneumatosis cystoides intestinalis, inflammatory bowel disease, bacterial overgrowth.
Liver	: hepatomegaly, non-specific transaminitis, steatosis, acute hepatitis, chronic active hepatitis, chronic persistent hepatitis, granulomatous hepatitis, cirrhosis.
Pancreas	: pancreatitis.
Gall bladder	: acalculus cholecystitis.
Serositis	

These GI vasculitic lesions may progress along a continuum. Depending on the extent and duration of vessel inflammation, clinical signs vary from that mimicking a mild gastroenteritis to an acute abdomen with distension, guarding and rebound tenderness requiring urgent surgical intervention for bowel infarction, perforation or rarely, associated complication of intra-abdominal abscess. Prognosis is good with early diagnosis and the institution of corticosteroids and if necessary, immunosuppressants^(2,7,8). Clinically evident GI vasculitis has been reported in the literature to be of low incidence (0.2-2%)^(9,10). The majority of cases reported to date had features of acute abdomen and high mortality. In our experience however, gastrointestinal vasculitis is probably much more common in active lupus than previously recognised and early vasculitis may present very much like an acute gastroenteritis. We recently reviewed 20 SLE patients who were admitted to our department with acute gastrointestinal symptoms and treated as GI vasculitis with corticosteroids⁽⁷⁾. The majority had complained of abdominal pain (90%), diarrhoea (75%) and vomiting (70%). As a result of early diagnosis and treatment, only one patient underwent laparotomy. At laparotomy, this patient was found to have patchy ischaemia in the small bowel consistent with vasculitis. None died because of the GI complications.

Case 2 reported by Luman and co-authors⁽⁹⁾ in this journal illustrates a rare GI manifestation of SLE the pathogenic mechanism of which is still unclear. Chronic intestinal pseudo-obstruction (CIPO) is defined as the presence of clinical features suggestive of intestinal obstruction but without organic obstruction, namely absence of bowel sounds, presence of multiple fluid levels on plain abdominal X-rays and the exclusion of an organic obstruction by imaging or surgical procedure. Mok and co-authors recently reported their experience with 6 patients and reviewed 12 other cases from the English literature⁽¹¹⁾. As in the case reported by Luman et al, 9 of these 18 patients had CIPO as the initial presentation of SLE and hence diagnosis and therapy with corticosteroids are often delayed. CIPO may be a late manifestation of GI vasculitis representing one end of the continuum of vasculitic process with visceral smooth muscle damage and resultant dysmotility. The very frequent association of CIPO with ureterohydronephrosis (UHN) further suggests vasculitis as an etiology of CIPO. Six of 12 cases of associated CIPO and UHN reviewed by Mok et al had documented histological features of chronic interstitial cystitis,

Its many varied presentations and manifestations are often a challenge to the Rheumatologist in both diagnosis and management and not infrequently, other specialists have to be called upon for assistance.

a condition associated with immune complexes. Other postulated causes of CIPO are smooth muscle dysmotility due to autoantibody or other primary myogenic causes or a neurogenic pathology. CIPO is reversible when treated early with adequate doses of corticosteroids with or without immunosuppressants as maintenance therapy⁽⁸⁾ and Octreotide may also be considered⁽¹²⁾.

Acute abdomen in SLE is a challenging diagnostic and therapeutic problem. It should be borne in mind that in patients who are already on high dose corticosteroids abdominal symptoms and signs may be masked. The presence of other features of active SLE strongly suggests the gastrointestinal symptoms are due to lupus. The SLE disease activity index (SLEDAI) score was found to be useful in Medina et al's series of 51 patients with acute abdomen⁽⁸⁾. In this series of lupus patients, a SLEDAI score of below 5 was a strong indicator that the abdominal complication was not due to SLE. In their subgroup of 19 patients with active SLE and vasculitis, the mean SLEDAI score was 15.4 (range 13-24) which was higher than that of patients with evidence of active SLE but non-SLE related acute abdomen (SLEDAI score 8.2, range 5-11). A careful history, clinical examination and appropriate use of investigations is the best approach to the evaluation of acute abdomen in any SLE patient (Fig. 1). Patients who are ill should be observed closely and exploratory laparotomy should not be delayed especially if there is progression of clinical symptoms despite augmented medical treatment. With a systematic approach, we could perhaps look forward to a reduced morbidity and mortality in the SLE patient presenting with gastrointestinal complaints. **SMD**

Patients who are ill should be observed closely and exploratory laparotomy should not be delayed especially if there is progression of clinical symptoms despite augmented medical treatment.

Abdominal pain, vomiting, diarrhoea

Look for clinical evidence of active disease

Investigations: FBC, platelets, ESR, CRP, C₃, C₄, anti-dsDNA Ab, ACA, LAC, U/E/Cr/S, LFT, amylase, urine FEME, blood C/S if febrile, stool C/S if diarrhoea, stool occult blood, AXR (erect & supine)

Special tests: Abdominal CT scan, abdominal U/S, mesenteric angiogram, upper GI series, endoscopy, manometry where appropriate

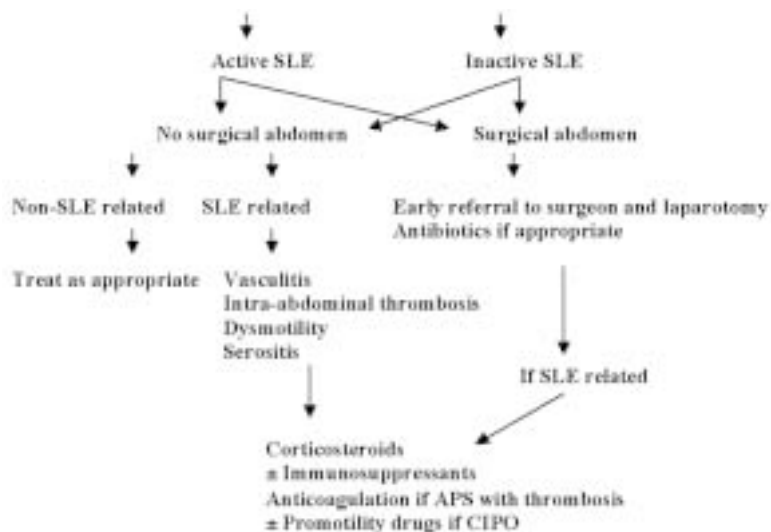


Fig 1. Approach to acute abdomen in SLE.

REFERENCES

1. Osler W. On the visceral complications of erythema exudativum multiforme. Am J Med Sci 1895; 110:629-45.
2. Sultan SM, Ioannou Y, Isenberg DA. A review of gastrointestinal manifestations of systemic lupus erythematosus. Rheumatology 1999; 38:917-32.
3. Luman W, Chua KB, Cheong WK, Ng HS. Gastrointestinal manifestations of systemic lupus erythematosus. Singapore Med J 2001; 42(8):380-4.
4. Dubois E, Tuffanelli D. Clinical manifestations of systemic lupus erythematosus. Computer analysis of 520 cases. J Am Med Assoc 1964; 190:104-11.
5. Fries J, Holman HR. Systemic lupus erythematosus: a clinical analysis. Philadelphia: WB Saunders, 1975.
6. Gunnarsson I, Kanerud L, Pettersson E, Lundberg I, Lindblad S, Ringertz B. Predisposing factors in sulphasalazine-induced systemic lupus erythematosus. Br J Rheumatol 1997; 36:1089-94.
7. Lian TY, CJ Edwards, Chng HH. A study of a cohort of Lupus patients with acute gastrointestinal manifestations of active disease. June 2001 EULAR Conference [abstr].
8. Medina F, Ayala A, Jara L, Becerra M, Miranda J, Fraga A. Acute abdomen in systemic lupus erythematosus: the importance of early laparotomy. Am J Med 1997; 103:100-5.
9. Drenkard C, Villa AR, Reyes E, Abello M, Alarcon-Segovia D. Vasculitis in systemic lupus erythematosus. Lupus 1997; 6:235-42.
10. Zizic TM, Classen JN, Stevens MB. Acute abdominal complications of systemic lupus erythematosus and polyarteritis nodosa. Am J Med 1982; 73:525-31.
11. Mok MY, Wong RWS, Lau CS. Intestinal pseudo-obstruction in systemic lupus erythematosus: an uncommon but important clinical manifestation. Lupus 2000; 9:11-8.
12. Perlemuter G, Cacoub P, Chaussade S, et al. Octreotide treatment of chronic intestinal pseudo-obstruction secondary to connective tissue diseases. Arthritis Rheum 1999; 42:1545-49.

ERRATUM

In the article "Clinics in Diagnostic Imaging (63)" published in Vol 42 Issue 7 July 2001, the address for W C G Peh should be

**Department of Diagnostic Radiology
Singapore General Hospital
Outram Road
Singapore 169608**

We are sorry for omission.

Publisher

Singapore Medical Journal
Level 2, Alumni Medical Centre
2 College Road
Singapore 169850
Tel: 223-1264
Fax: 224-7827
URL <http://www.sma.org.sg>

Design and Advertising

Lancer Communications Pte Ltd
69 Spottiswoode Park Road
Singapore 088659
Tel: 324 4337
Fax: 324 4661
Email: studio@lancer.com.sg

For advertising placement, call

- Charlie Teo at 324-4337

Printed by Entraco Printing Pte Ltd

The Singapore Medical Journal is published monthly by the Singapore Medical Association. All articles published, including editorials, letters & book reviews represent the opinion of the authors and do not reflect the official policy of the SMA or Institution with which the authors is affiliated unless this is clearly specified. The Publisher cannot accept responsibility for the correctness or accuracy of the advertisers' text and/or claim or any opinion expressed. The appearance of advertisements in the Journal does not necessarily constitute an approval or endorsement by the SMA of the product or service advertised. The contents of this publication are not to be quoted in the press without permission of the Editor.