

# Medical Management of Cervical Pregnancy – A Report of Two Cases

S Chew, C Anandakumar

## ABSTRACT

**Cervical ectopic pregnancy is a rare life-threatening condition that can be managed conservatively. In this report, the authors describe the use of systemic methotrexate and prostaglandin (sulprostone) in the management of two cases of viable cervical pregnancy. Both cases were successfully treated without the need for surgical intervention.**

**Keywords:** Cervical pregnancy, medical treatment, methotrexate, prostaglandins

*Singapore Med J 2001 Vol 42(11):537-539*

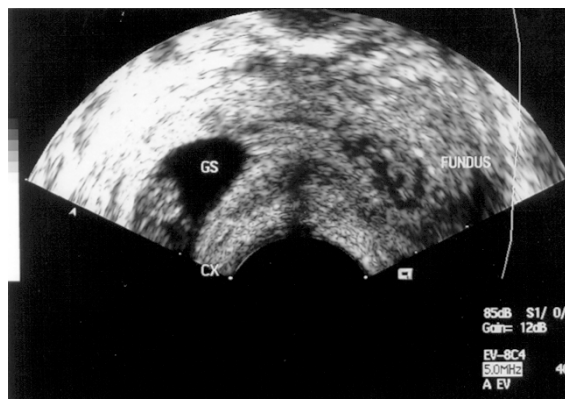
## INTRODUCTION

In the past, cervical ectopic gestation would often present with life threatening haemorrhage and this would frequently require an emergency hysterectomy. However, with the aid of early ultrasound diagnosis and with promising medical therapy, conservative non-surgical management of this entity is now possible. This short report will now describe the successful use of methotrexate and sulprostone (Nalador®, Schering Pharma) in two patients with cervical pregnancy. As far as we know, this is the first report of systemic prostaglandins being used for the conservative management of viable cervical pregnancies.

## CASE REPORTS

### Case 1

A 34-year-old subfertile patient was undergoing her second IVF cycle at our centre when she conceived. At six weeks' gestation, a transvaginal ultrasound scan done initially showed an empty uterine cavity with a foetal gestational sac that was noted to be at the level of the isthmus. As the diagnosis of cervical pregnancy was still doubtful at this time, a repeat viability scan was scheduled three weeks later. Unfortunately, the patient presented three days prior to her scheduled scan (at eight weeks and five days of gestation) with an episode of light vaginal bleeding. A repeat transvaginal scan then revealed a viable cervical pregnancy with a crown-rump length (CRL) of



**Fig. 1** Ectopic pregnancy at eight weeks and five days amenorrhoea with a gestational sac (GS) seen in the cervical canal.

19 mm (Fig. 1). She was admitted the same day and her quantitative serum  $\beta$ -hCG (human chorionic gonadotrophin) level was 66,143 IU/L. Intravenous methotrexate 50 mg (with intramuscular folinic acid 12.5 mg rescue) was administered. This was combined with three intravenous doses of sulprostone 500 micrograms (Nalador®, Schering Pharma.) given eight hours apart. The following day, the patient experienced vaginal bleeding with clots but her vital signs remained stable. Thereafter, only vaginal spotting was noted. However, her haemoglobin levels dropped from 13.7 gm% to 9.9 gm and she was transfused with two units of blood. A repeat scan performed five days after starting chemotherapy revealed only a 3 cm complex mass in the cervix with no more foetal heart activity. The serum  $\beta$ -hCG level had also by then dropped to 10,895 IU/L. Subsequent serum  $\beta$ -hCG levels done serially continued to show a steady decline. By three weeks post-chemotherapy, the serum  $\beta$ -hCG level was 37.2 IU/L. The patient was finally discharged from the ward 18 days after admission. The patient has since undergone another IVF cycle with us but has failed to conceive.

### Case 2

A 30-year-old G1P0 at seven weeks' gestation was referred to our centre by her gynaecologist for a cervical pregnancy that was suspected on pelvic scan.

Department of  
Obstetrics and  
Gynaecology  
National University  
Hospital  
5 Lower Kent  
Ridge Road  
Singapore 119074

S Chew, MBBS,  
MRACOG  
Senior Lecturer

C Anandakumar,  
MBBS, MRCOG  
Associate Professor

**Correspondence to:**  
Dr Stephen Chew  
Tel: (65) 772 4276  
Fax: (65) 779 4753  
Email: obgchews@  
nus.edu.sg

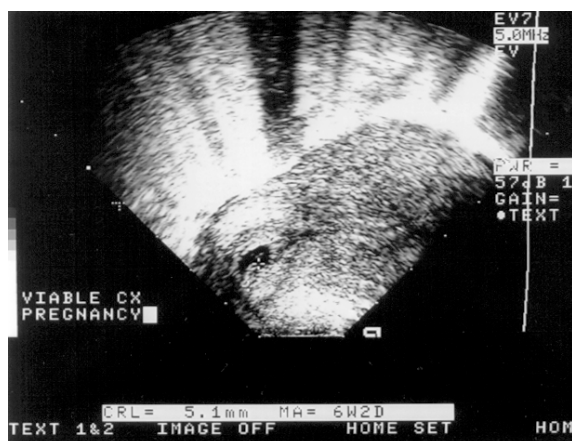


Fig. 2 Viable cervical ectopic pregnancy at seven weeks' gestation.

The patient had previously experienced vaginal spotting for a day, associated with lower abdominal cramps. On admission, her vital signs were stable and a transvaginal ultrasound scan showed a viable cervical pregnancy with a CRL of 6mm (Fig. 2). A quantitative serum  $\beta$ -hCG level done on admission was 2,456 IU/L. Her haemoglobin was 13.1 gm%. She was started on intravenous methotrexate (MTX) 20 mg (one dose) and Nalador 500 micrograms, eight hourly (three doses). She was also covered with intravenous antibiotics (Ampicillin/Gentamicin) because of a medical history of mitral valve prolapse.

One day after starting chemotherapy, the patient experienced light vaginal bleeding and passed out a clot. This was sent for histopathological examination but revealed only necrotic decidual tissue. Thereafter, the patient only had vaginal staining and a repeat transvaginal scan (done six days after starting chemotherapy) showed no more gestational sac in the cervical canal. Her serum  $\beta$ -hCG level done on the same day was 148 IU/L. Haemoglobin was 12.1 gm%. The patient was discharged six days after admission and remained well during her outpatient follow-up visits. The patient serum  $\beta$ -hCG done nine days after starting chemotherapy was 27.7 IU/L.

## DISCUSSION

The key to successful conservative management of a cervical pregnancy is still early diagnosis and in both our patients, this was made before nine weeks of gestation using transvaginal ultrasonography. In addition, conservative treatment of this condition is also more likely to succeed before 12 weeks of gestation because of less trophoblastic infiltration into the cervical walls<sup>(1)</sup>.

Farabow et al<sup>(2)</sup> was the first to report the use of MTX for cervical pregnancy.

In general, various other workers have also reported the use of both high (>150 mg)<sup>(3)</sup> and low (<150 mg)<sup>(4)</sup>

doses of MTX in their protocols. In addition, MTX can also be administered systemically (intravenous/intramuscular)<sup>(5)</sup> or as local intra-amniotic injections<sup>(6)</sup>. In our centre, we only use single low dose (20 - 50 mg) intravenous MTX injections and this is combined with three doses of a prostaglandin infusion (Nalador 500 micrograms).

Hung et al<sup>(7)</sup> analysed some prognostic factors affecting the outcome of conservative MTX treatment. They found that MTX therapy in the presence of cervical pregnancies with: 1) serum  $\beta$ -hCG levels greater than 10,000 IU/L, 2) a gestational age  $\geq$  9 weeks amenorrhoea, 3) positive foetal cardiac activity or, 4) a crown-rump length greater than 10mm, were generally associated with higher failure rates. Although the patient in Case 1 had three poor prognostic factors ( $\beta$ -hCG > 10,000 IU/L, positive fetal heart and CRL (10 mm), conservative MTX therapy was still successful. However, that patient did experience significant vaginal bleeding after MTX therapy and actually required a blood transfusion. In contrast, the patient in Case 2 had lower serum  $\beta$ -hCG levels and although the foetal heart was positive, the patient responded very well to MTX treatment and did not have significant post-MTX vaginal bleeding. Despite having viable cervical ectopic pregnancies, both our cases were still successfully treated with systemic therapy (MTX and Nalador).

## THE ROLE OF PROSTAGLANDINS

Prostaglandins have already been used in the medical treatment of tubal ectopic pregnancies. However, here the use of prostaglandins in cervical pregnancies has only been reported by a few authors<sup>(1,8)</sup>. Dall et al<sup>(1)</sup> reported the use of prostaglandin, both systemically and intra-amniotically, in a patient with a nine-week-old cervical pregnancy. This was combined with dilatation and curettage but the patient still required a hysterectomy because of intractable bleeding. Spitzer et al<sup>(8)</sup> subsequently described three cases of first trimester cervical pregnancy that were successfully treated with curettage and local prostaglandin instillation. In their first case, 10 mg of prostaglandin F2 (Minprostin; Upjohn) was injected under transvaginal ultrasound guidance, into the site of cervical implantation. The other two patients reportedly had 12.5 - 25 micrograms of sulprostone instilled intra-cervically. All three cases were thus successfully managed without having to resort to a hysterectomy.

In our series, both patients received intravenous sulprostone 500 micrograms (three doses) with no untoward side effects. As far as we know, this is the first report of systemic prostaglandins being used for the conservative management of viable cervical pregnancies.

Although both of our patients were able to preserve their fertility, none have so far conceived after nearly a year following the successful treatment of their cervical pregnancies. In fact, the conception rate after the successful treatment of cervical pregnancy has generally been low, and only a handful of pregnancies have subsequently been reported in the literature<sup>(8)</sup>.

#### REFERENCES

1. Dall P, Pfisterer J, du Bois A, Wilhelm C, Pfeleiderer A. Therapeutic strategies in cervical pregnancy. *Eur J Obstet Gynaecol Reprod Biol* 1994; 56:195-200.
2. Farabow W, Fulton J, Fletcher V Jr, Velat CA, White JT. Cervical pregnancy treated with methotrexate. *N C Med J* 1983; 44:91-3.
3. Hung TH, Jeng CJ, Yang YC, Wong KG, Lan CC. Treatment of cervical pregnancy with methotrexate. *Int J Gynaecol Obstet* 1996; 53:243-7.
4. Jurkovic D, Hackett E and Campbell S. Diagnosis and treatment of early cervical pregnancy: a review and a report of two cases treated conservatively. *Ultrasound Obstet Gynecol* 1996; 8:373-80.
5. Yankowitz J, Leake J, Huggins G, Gazaway P, Gates E. Cervical ectopic pregnancy: review of the literature and report of a case treated by single-dose methotrexate therapy. *Obstet Gynecol Surv* 1990; 45:405-14.
6. Timor-Tritsch IE, Monteagudo A, Mandeville EO, Peisner DB, Anaya GP, Pirrone EC. Successful management of viable cervical pregnancy by local injection of methotrexate guided by transvaginal ultrasonography. *Am J Obstet Gynecol* 1995; 170:737-9.
7. Hung TH, Shau WY, Hsieh TT, Hsu JJ, Soong YK, Jeng CJ. Prognostic factors for an unsatisfactory primary methotrexate treatment of cervical pregnancy: a quantitative review. *Human Reproduction* 1998; 13:2636-42.
8. Spitzer D, Steiner H, Graf A, Zajc M and Staudach A. Conservative treatment of cervical pregnancy by curettage and local prostaglandin injection. *Human Reproduction* 1997; 12:860-6.