

# A 12-Year Experience in the Surgical Management of Vesicovaginal Fistulae

M H Kam, Y H Tan, M Y C Wong

## ABSTRACT

**Introduction:** Vesicovaginal fistulae are largely iatrogenic and represent therapeutic dilemmas in surgical approach and timing of repairs.

**Aim:** We have reviewed our surgical management of vesicovaginal fistulae over a 12-year period to determine whether the outcome is dependent on surgical approach and timing of repair.

**Patients and Methods:** From January 1990 to September 2001, 23 patients were referred to our department of whom 20 have retrievable records. Fourteen of these 20 patients had gynaecological operations as the primary cause for their fistulas whilst the remaining six had varied causes ranging from forceps delivery to recurrent pelvic malignancies.

**Results:** Of 20 patients, four underwent transvaginal repair, seven transvesical repair, eight supravaginal repair and one required an ileal conduit diversion. There was an 85% success after first repair with only three fistula recurrences, two of whom underwent a successful second repair and one was treated conservatively and successfully with urethral catheterisation. There were no further recurrences at mean follow-up of 23 months for our cohort. Earlier repair seemed to be associated with a higher recurrence rate (33% of six patients within six weeks) compared with delayed operations (7% of remaining 14 operated after six weeks).

**Conclusion:** Vesicovaginal fistulae can be successfully managed surgically. Although the type of approach did not affect outcome, the timing of the repair may affect the success of the operation.

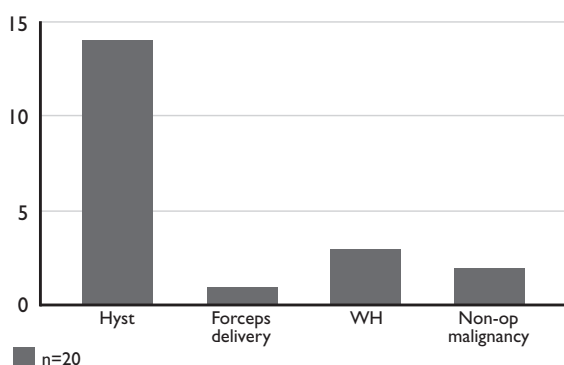
**Keywords:** Vesicovaginal, fistula, genitourinary, iatrogenic, surgical management

Singapore Med J 2003 Vol 44(4):181-184

## INTRODUCTION

Vesicovaginal fistula is rare and its main impact lies in the social distress that results from the persistent

Fig. 1 Etiology of Vesicovaginal Fistula.



leakage of urine. The overwhelming majority of vesicovaginal fistulae, result from iatrogenic causes, the most common being hysterectomy<sup>(1-5)</sup>. There are, however, other etiologies, including pelvic surgeries, pelvic malignancies and trauma, radiation necrosis as well as obstetric trauma<sup>(2,6-9)</sup>.

Two major issues predominate in any discussion of vesicovaginal fistula, namely, the timing of repair and the surgical approach used. In most instances, similar results were obtained whichever approach was used<sup>(2)</sup>. There seemed to be no real difference in either early or late repair<sup>(1-5)</sup>. In selected cases, urinary diversion may be required as a treatment of choice<sup>(10)</sup>.

The objective of this study is to retrospectively review our clinical experience in the surgical management of vesicovaginal fistulae over the past 12 years, with the intention of determining the outcome based on different surgical approaches and timing of repair.

## PATIENTS AND METHODS

A total of 23 patients were referred to the hospital for management of vesicovaginal fistula from January 1990 to September 2001, of whom 20 records could be retrieved. The mean age of our cohort was 50 years (range: 21-73 years) and the mean follow-up period was 23 months (range: one to 79 months).

The commonest cause of a fistula in our group remained hysterectomy for uterine fibroids, which made up 14 of the 20 cases (70%). The other causes included one case of assisted forceps delivery, three Wertheim's hysterectomies and two non-operative

Department of  
Urology  
Singapore General  
Hospital  
Outram Road  
Singapore 169608

M H Kam, MBBS  
Medical Officer  
(Trainee)

Y H Tan, MBBS,  
MMed (Surg)  
FRCS (Edin)  
Registrar

M Y C Wong,  
FRCS (Edin),  
MMed (Surg),  
FAMS (Urology)  
Senior Consultant

**Correspondence to:**  
M Y C Wong  
Tel: (65) 6321 4693  
Fax: (65) 6227 3787  
Email: gurwyc@  
sgh.com.sg

**Table I. Diagnostic Investigations performed.**

	Methylene Blue	3-swab test	Cystogram	Cystoscopy	Vaginoscopy/ Speculum	IVU	RPG
Fistula detected	6	4	6	11	5	2	3
Not detected	2	0	1	6	1	8	0
Total Number undergoing test	8	4	7	17	6	10	3

recurrent pelvic malignancies (Fig. 1). There were 12 patients who presented at less than six weeks post-operatively, and six who presented between two to 24 years post-operatively. The patient who presented at 24 years actually presented with overflow incontinence from a neurogenic bladder and the fistula was detected only incidentally on cystoscopy.

The majority of our patients (16 out of 20) complained of persistent leakage of urine. Of the remaining four, there were three cases of incidental detection of vesicovaginal fistula, and one patient complained of right flank pain from a right hydronephrosis. This had resulted from a small fistula adjacent to a stricture at the lower third of the right ureter, and required a concomitant ureteric reimplantation at the time of transabdominal repair.

There were six patients who had failed an initial trial of catheterisation instituted by the attending gynaecologists and of these, four had unsuccessful first repairs elsewhere before being referred to our centre. These four repairs included three transvaginal and one transvesical repair.

There were a variety of investigations carried out in the diagnosis of vesicovaginal fistula in our cohort. The commonest was cystoscopy which picked up 11 of 17 vesicovaginal fistulae. The others included introduction of methylene blue into the bladder, the three-swab test, a formal cystogram, vaginoscopy/speculum examination, and an intravenous urogram or retrograde pyelogram for detection of concomitant ureterovaginal fistulae (Table I).

## RESULTS

All 20 patients in the group were managed surgically at our centre. Of these, four underwent transvaginal repair, seven transvesical, extraperitoneal repair and eight supravescical, intraperitoneal repair. One patient presented with a large fistula secondary to recurrent carcinoma of the cervix, with metastasis to the sacrum, and underwent an ileal conduit diversion. There was an 85% success in the first repair with only three patients (15%) presenting with fistula recurrence post-operatively, two of whom required a successful second repair (Table II). None of the four patients who failed first repair before referral to our institution had recurrence after our repair. All patients had no subsequent recurrences at mean follow-up of 23 months.

**Table II. Outcome of Repair.**

Type of Repair	Number Operated	Failure	Success
Transvaginal	04	01	03
Transvesical	07	01	06
Supravescical	08	01	07
Ileal Conduit	01	Nil	01
Total	20	03	17

**Table III. Timing of Repair.**

Timing of Repair	Number Operated	Recurrence
<3 months	11	02
(a) <6 weeks	(a) 06	(a) 02
(b) 6 weeks to 3 months	(b) 05	(b) nil
3 to 6 months	05	nil
>6 months	04	01

The timing of repair was divided into two categories. The majority of our patients had an early repair (less than six months). Of these, six underwent repair less than six weeks after the initial hysterectomy, while five had the repair between six weeks to three months, and a further five at three to six months. There were only four patients who had a late repair at six months and beyond (Table III).

Interestingly enough, there were two recurrences among the six patients who were operated in under six weeks (33%), while only one out of the remaining 14 who had the repair more than six weeks later (7%), had a recurrence.

Interposition flaps were used in only six patients. One patient had a Martius labial fat pad interposed at the time of transvaginal repair, while two of seven transvesical and three of eight supravescical repairs had omentum interposed between bladder and vagina. All six patients with interposition flaps had no recurrence.

There were four patients with post-operative complications. These included a case of incisional hernia, one patient with wound infection which resolved with antibiotics and two patients with post-operative ileus requiring prolonged hospital stay. Post-operative hospital stay ranged from a mean of six days (range: two to 12 days) for transvaginal repair

to a mean of 14 days (range: four to 25 days) for supravescical repair. Post-operative bladder drainage ranged from 12 days (range: seven to 19 days) for transvaginal repairs to 21 days (range: eight to 69 days) for supravescical repairs. 11 patients had a post-operative cystogram performed prior to urethral catheter removal.

## DISCUSSION

With regards to etiology, our series presented here compares favourably with others in the literature. Goodwin reported that 75% of his cases were of gynaecological origin<sup>(1)</sup>, and more recently, Lee reported 82% resulted from such gynaecological surgery, and only 8% from obstetric complications<sup>(11)</sup>. This is consistent with 70% of cases secondary to gynaecological surgery and 5% due to obstetric complications in our series.

Most gynaecologists seem to favour the transvaginal repair<sup>(5,12,13)</sup> while urologists prefer the transabdominal repair<sup>(3,4,14)</sup>. The transvaginal repair, being a less invasive repair has obvious advantages in terms of cosmesis and patient discomfort. It also ensures that the repair is performed outside of a recently operated pelvis. In addition, there is a reduction in length of post-operative hospitalisation as well as peri-operative bleeding<sup>(15)</sup>. This has been borne out in our study. The disadvantage of this approach is the limited access. The abdominal approach, however, has its strengths in the optimal exposure of the fistula as well as intraoperative assessment of complex fistulae or cases with concomitant ureteral obstruction. These may ultimately require interposition of omentum or even ureteric reimplantation or urinary diversion. This is seen in three of the cases in this series.

The approach used depends very much on the preference and experience of the surgeon. Suffice it to say that whatever the approach, whether transvaginal or abdominal, the results are similar<sup>(2,5)</sup>. All three recurrences in our group represented different types of repair, one each in transvaginal, transvesical (extraperitoneal) and supravescical (intraoperative) repairs. There was no observable difference in outcome when compared between the various surgical approaches. As such, the more important determinants of a successful repair are the principles of a tension-free repair, adequate blood supply, prevention of infection and adequate post-operative bladder drainage.

The use of interpositional grafts is likely to contribute towards better outcome though this has not been substantiated in controlled studies. These grafts include omental flaps<sup>(16,17)</sup>, peritoneal flaps<sup>(18,19)</sup> and Martius labial fat pads<sup>(20-22)</sup>. In our experience, all

six patients with interpositional flaps had no recurrence, while all three recurrences out of 20 were repaired in two layers with no interpositional flaps.

Timing of repair warrants some discussion as authors have expressed differing opinions regarding the most favourable time for undertaking such repair. Traditionally, the dogma of waiting more than six months for healing of tissues from the previous operation is not often practised in this age. This is especially true for simple post-hysterectomy fistulas, which are more frequently the cause rather than post-partum or malignant fistulas. Moreover, the patient's distress usually warrants earlier intervention. Literature suggests that some surgeons are favouring earlier repair in view of the social distress caused by the persistent leakage from a vesicovaginal fistula. Some suggest that the repair should not be delayed more than three months after the initial gynaecological operation as there was no added benefit<sup>(4,11,15)</sup>. Langkilde et al, in his study of 13 patients operated within three months of the iatrogenic lesion, reported no recurrence or increased morbidity<sup>(2)</sup>.

In our series, however, two of 11 patients operated within three months had a recurrence. Both patients presented with fistulas after total hysterectomies for uterine fibroids and were operated within four weeks of the iatrogenic lesion. This earlier repair seemed to be associated with a higher recurrence rate (33% of six patients operated within six weeks) compared with delayed operations (7% of remaining 14 operated after six weeks). This may be due to unresolved inflammation or oedema resulting in poor wound healing after the repair. As such, it is the practice at our institution to delay operations till at least six to eight weeks before undertaking primary repair.

All three recurrences in our series presented within one month of primary repair. All three primary repairs had been carried out at our centre. Two had persistent leakage of urine at one month follow-up while one had the communicating fistula visualised on post-operative cystogram. Both the symptomatic cases underwent abdominal (transvesical) repair and were continent at one year follow-up. The other patient was successfully managed with prolonged urethral catheterisation for 18 days. She was continent at four months follow-up.

The four patients who had unsuccessful first repairs before being referred to our urology centre had subsequent successful repairs in our hands. Thirteen patients who underwent first repairs at our urology centre were continent at follow-up and all three with recurrences had good outcome subsequently. Thus, in totality, all 20 of our patients were successfully managed surgically.

The inherent limitations of our data are in the small population size and its retrospective nature, resulting in the inability to draw any firm conclusions. Nevertheless, our experience may hopefully serve as a guide for future management of this uncommon urogynaecological problem.

### CONCLUSION

The cause of vesicovaginal fistulas still remains largely iatrogenic. Patients thus afflicted with a very socially distressing condition at a relatively young age, would naturally be keen for an early repair. This may be carried out at six to eight weeks in simple cases, though an earlier repair did not provide a better outcome in our series. The type of approach depends on the varied preference and experience of the surgeon, with different approaches offering equally good results at our institution. The principles of fistula repair and case selection remain important determinants of outcome. Use of interposition grafts may be associated with better outcome, and should certainly be considered in the repair of large, complex fistulas. Urinary diversion is still viable for a select group of patients. Nevertheless, most vesicovaginal fistulas are readily amenable to surgical repairs with good outcome.

### REFERENCES

- Goodwin WE, Scardino PT. Vesicovaginal and ureterovaginal fistulas: a summary of 25 years of experience. *J Urol* 1980; 123:370-4.
- Langkilde NC, Pless TK, Lundbeck F, Nerstrom B. Surgical repair of vesicovaginal fistulae: A ten-year retrospective study. *Scand J Urol Nephrol* 1999; 33:100-4.
- O Connor VJ. Review of experience with vesicovaginal fistula repair. *J Urol* 1980; 123:367-9.
- Blandy JP, Badenoch DF, Fowler CG, Jenkins BJ, Thomas NW. Early repair of iatrogenic injury to the ureter or bladder after gynaecological surgery. *J Urol* 1991; 146:761-5.
- Blaivas JG, Heritz DM, Romanzi LJ. Early versus late repair of vesicovaginal fistulas: vaginal and abdominal approaches. *J Urol* 1995; 153:1110-2.
- Arrowsmith SD. Genitourinary reconstruction in obstetric fistulas. *J Urol* 1994; 152:403-6.
- Krause S, Hald T, Steven K. Surgery for urologic complications following radiotherapy for gynaecologic cancer. *Scand J Urol Nephrol* 1987; 21:115-8.
- Mraz JP, Sutory M. An alternative in surgical treatment of post-irradiation vesicovaginal and rectovaginal fistulas: the seromuscular intestinal graft (patch). *J Urol* 1994 Feb; 151(2):357-9.
- Mattingly RF. Acute operative injury to the urinary tract. *Clin Obstet Gynecol* 1978; 5:123-49.
- Jones CR, Woodhouse CRJ, Hendry WF. Urological problems following treatment of carcinoma of the cervix. *Br J Urol* 1984; 56:609-13.
- Lee RA, Symmonds RE, Williams TJ. Current status of genitourinary fistula. *Obstet Gynaecol* 1988; 72:313-9.
- Elkins TE. Surgery for the obstetric vesicovaginal fistula: a review of 100 operations in 82 patients. *Am J Obstet Gynaecol* 1994; 170:1108-20.
- Tancer ML. Observations on prevention and management of vesicovaginal fistula after total hysterectomy. *Surg Gynecol Obstet* 1992; 175: 501-6.
- Bissada NK, McDonald D. Management of giant vesicovaginal and vesicourethrovaginal fistulas. *J Urol* 1983; 130:1073-5.
- Wang Y, Hadley HR. Nondelayed transvaginal repair of high lying vesicovaginal fistula. *J Urol* 1990; 144:34.
- Kiricuta I, Goldstein AMB. The repair of extensive vesicovaginal fistulas with pedicled omentum: a review of 27 cases. *J Urol* 1972; 108:724-7.
- Turner-Warwick RT, Wynne EJC, Handley-Ashken M. The use of the omental pedicle graft in the repair of and reconstruction of the urinary tract. *Br J Surg* 1967; 54:849-53.
- Eisen M, Jurkovic K, Altwein J-E, Schreiter F, Hohenfellner R. Management of vesicovaginal fistulas with peritoneal flap interposition. *J Urol* 1974; 112:195-8.
- Raz S, Bregg KJ, Nitti VW, Sussman E. Transvaginal repair of vesicovaginal fistula using a peritoneal flap. *J Urol* 1993; 150:56-9.
- Elkins TE, Delancey JOL, McGuire EJ. The use of modified Martius graft as an adjuvant technique in vesicovaginal and rectovaginal fistula repair. *Obstet Gynaecol* 1990; 75:727-33.
- Patil U, Waterhouse K, Laungani G. Management of 18 difficult vesicovaginal and urethrovaginal fistulas with modified Ingelman-Sundberg and Martius operations. *J Urol* 1980; 123:653-6.
- Margolis T, Elkins TE, Seffah J, Oparo-Addo HS, Fort D. Full thickness Martius grafts to preserve vaginal depth as an adjunct in the repair of large obstetric fistulas. *Obstet Gynaecol* 1994; 84:148-52.