

# Dilated Common Bile Duct in Opium Addicts with and without Biliary Symptoms – Implication for Research in AIDS Cholangiopathy

SY Chuah, C K Leong, CW Pang

## ABSTRACT

**Background:** Opium addicts (OA) with no biliary symptoms have been shown to have dilated common bile duct (CBD). Endoscopic retrograde cholangio-pancreatography (ERCP) without biliary drainage in such asymptomatic OA is hazardous. Hence it is not indicated unless there are clear clinical and laboratory evidences of biliary stasis.

**Aims:** To show that even when matched with controls with the same clinical diagnosis of the biliary system, OA still have significantly larger CBD diameters and that OA with biliary symptoms should be treated no differently from non-OA with biliary symptoms.

**Method:** Seven OA (all Chinese males), four of whom had undergone ERCP (three for CBD stones and one for ampullary carcinoma), were compared, using t-test, to 7 age, sex, race and diagnosis-matched controls, four of whom had also undergone ERCP (three for CBD stones and one for ampullary carcinoma). When ERCP was not done, ultrasonography was used to assess the biliary system and measure the CBD diameter. **Results –** The mean (SD) CBD diameters of OA and controls were 15.7 mm (5.65) and 8.3 mm (5.95) respectively ( $t=2.399$ ,  $p=0.032$ ). The mean (SD) weight of OA and controls were 55.8 kg (9.22) and 57.3 kg (9.21) respectively ( $t=-0.305$ ,  $p=0.763$ ). Only two of the seven OA were born in China, the remaining five in Malaysia.

**Conclusions:** OA do get CBD pathology like non-OA and if indicated there should be no qualms about performing ERCP in them. When matched for age, sex, race and clinical diagnosis, OA still have a significantly larger CBD despite no difference in body weight.

**Keywords:** common bile duct, opium addicts, AIDS

## INTRODUCTION

Opium consumption amongst the Chinese is a legacy of the 1840 Anglo-Chinese Opium War. Sporadic cases of opium addiction can still be found among Chinese living in Southeast Asia even though some were not born in China. Opium addicts (OA) with no biliary symptoms have been shown to have dilated common bile duct (CBD)<sup>(1)</sup>.

Diagnostic endoscopic retrograde cholangio-pancreatography (ERCP) without biliary drainage is hazardous in such OA. In the study by Yap, et al, four of their 16 asymptomatic OA had ERCP. All four had no structural lesions found, two had contrast retention for >1 hour, one with contrast retained for >6 hours died after emergency surgery for acalculous cholecystitis. Another three OA had biliary scintigraphy, all of which showed delayed transit ranging from 90 to 300 minutes.

Despite the common occurrence of gallstones<sup>(2,3)</sup>, none of Yap's 16 OA had biliary pathology. This leaves a couple of questions unanswered. Are OA less likely to get biliary disease? Should OA with biliary symptoms be treated any differently from non-OA with biliary symptoms? We carried out a study to confirm that even when matched with controls with the same clinical diagnosis with regards to the biliary system, OA still have larger CBD diameters than non-OA and to show that in the presence of biliary symptoms, OA should be treated no differently from non-OA. The finding of dilated CBD in OA has serious implication for research in the area of AIDS cholangiopathy.

## PATIENTS AND METHODS

Seven OA (all Chinese males), four of whom had undergone ERCP (three for CBD stones and one for ampullary carcinoma), were compared, using t-test, to 7 age, sex, race and diagnosis-matched controls, four of whom had also undergone ERCP (three for CBD stones and one for ampullary carcinoma). The three OA who did not undergo ERCP had no CBD stones and were matched with three controls who also had no CBD stones and did not undergo ERCP.

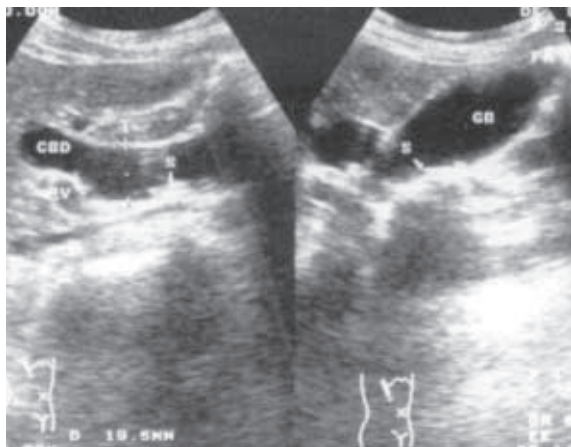
Hospital Pantai  
Ayer Keroh  
2418-1, km 8,  
Lebuh Ayer Keroh  
75450 Melaka  
Malaysia

S Y Chuah,  
MBBCh (Wales),  
MRCP (UK)  
Consultant  
Gastroenterologist

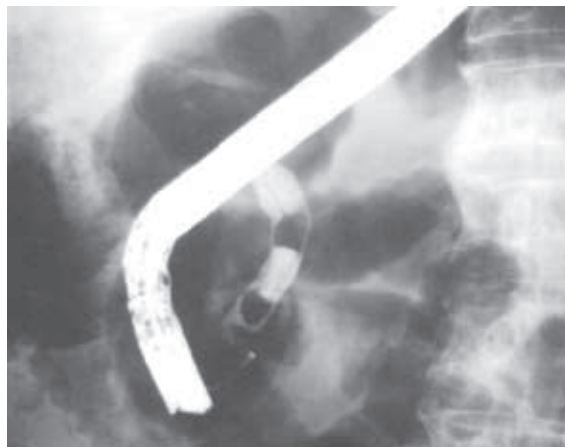C K Leong,  
MBBS, FRCS  
Consultant Surgeon

C W Pang, MBBS,  
MRCP (UK)  
Consultant  
Gastroenterologist

**Correspondence to:**  
Dr S Y Chuah  
Tel/Fax: 06-231 8503  
Email: chuahsy@  
pc.jaring.my



**Fig. 1a** Ultrasonogram of Case 1 at presentation shows a dilated CBD (19.5 mm diameter) and small CBD stones.



**Fig. 1b** Cholangiogram of Control 1 shows a marginally dilated CBD (11.4 mm diameter) and 2 CBD stones.

**Table I. Comparison in CBD diameter between OA and age and sex-matched controls from the same racial group, with the same clinical diagnosis of the biliary tree.**

Cases	CBD			Controls	CBD		
	diameter	Wt (kg)	Ages		diameter	Wt (kg)	Age
LKS	19.5 mm	44.5	71	LBK	11.4 mm	74.0 *	71
LWK	14.2 mm	68.0	69	B	1.8 mm	52.5	69
THP	18.9 mm	57.0	64	LKT	12.6 mm	65.0 *	64
THC	22.7 mm	46.5	67	LCK	14.0 mm	52.5 *	67
PSF	8.3 mm	57.5	63	GCO	2.5 mm	57.0	63
CAS	18.2 mm	50.5	69	CYC	14.0 mm	47.0 *	71
NKM	8.3 mm	66.5	46	TTC	1.7 mm	53.0	46
Mean	15.7 mm	55.8	64.14		8.3 mm	57.3	64.43
s.d.	5.65 mm	9.22	8.49		5.95 mm	9.21	8.72
Significance:	CBD diameter	- t = 2.399	p = 0.032				
	Weight	- t = -0.305	p = 0.763				
	Age	- t = -0.062	p = 0.950				

\* indicates pairs who had ERCP.

The controls were selected at random prospectively. When ERCP was not done, ultrasonography was used to assess the biliary system and measure the CBD diameter. ERCP was performed in the standard manner using an Olympus TJF 130 duodenoscope by the first author.

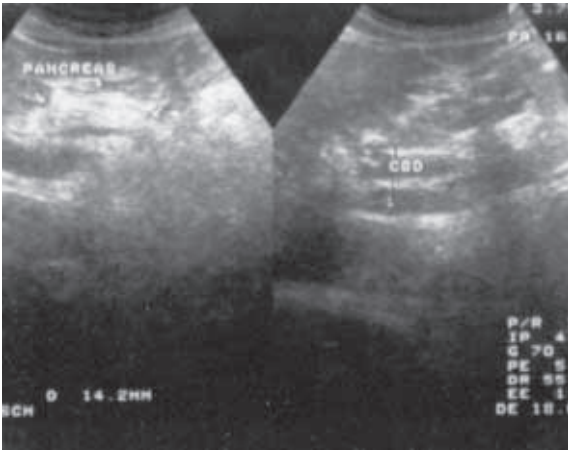
## RESULTS

The mean (SD) CBD diameters of OA and controls were 15.7 mm (5.65) and 8.3 mm (5.95) respectively ( $t=2.399$ ,  $p=0.032$ ) (Table I). The mean (SD) weight of OA and controls were 55.8 kg (9.22) and 57.3 kg (9.21) respectively ( $t=-0.305$ ,  $p=0.763$ ) (Table I). Only two of the seven OA were born in China, the remaining five were born in Malaysia.

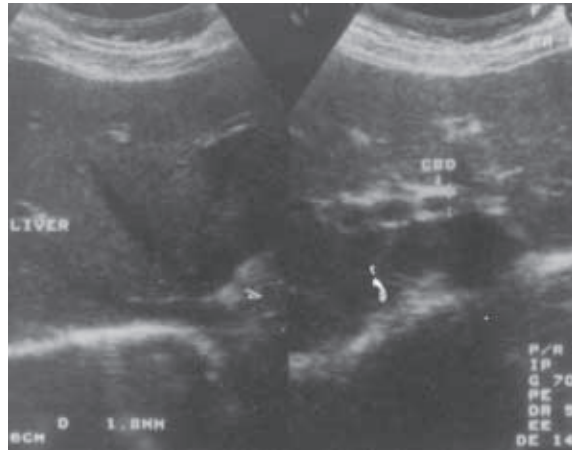
## CASE I

LKS was 71 when he first presented in September 1994 with epigastric pain. Despite normal liver enzymes, ERCP was done as ultrasonography revealed

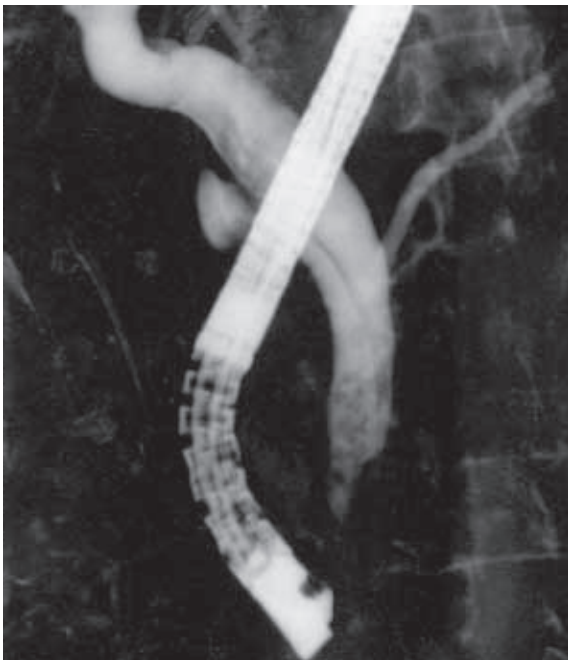dilated CBD (19.5 mm diameter) and small CBD stones (Fig. 1a). His first ERCP, however, failed to reveal any stones. Nevertheless a sphincterotomy was done. His next two ERCP were done in December 1995 for epigastric pain. Liver enzymes were again normal but multiple CBD stones were extracted and his CBD stented. At his fourth ERCP in mid-1996, the biliary stent was noted to have migrated into the CBD. This resulted in a cholecystectomy with CBD exploration. Almost a year later, he had an episode of acute cholangitis, which was treated conservatively. This was the first time his liver enzymes ever became abnormal. Just over four months later, he had his second episode of acute cholangitis. When he became cholangitic again for the third time almost two years after his first operation, a choledochojunostomy was done. Apart from an admission for subacute intestinal obstruction due to adhesions, he has remained well. He was born in China.



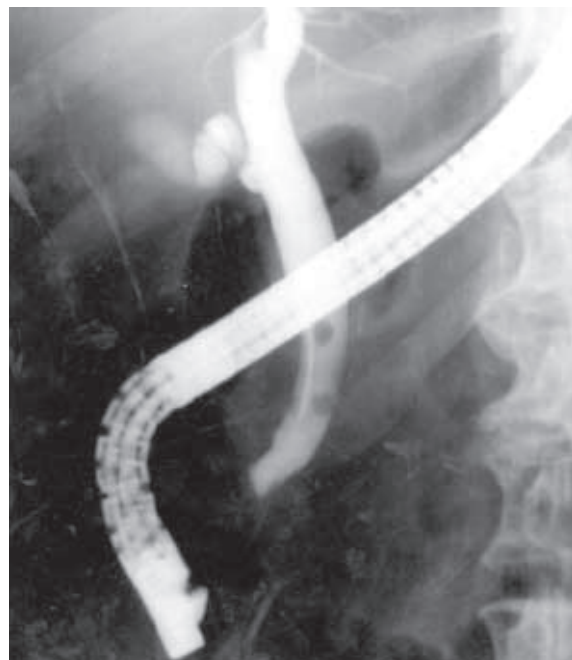
**Fig. 2a** Ultrasonogram of Case 2 shows a dilated CBD of 14.2 mm diameter.



**Fig. 2b** Ultrasonogram of Control 2 shows a CBD diameter of 1.8 mm.



**Fig. 3a** Cholangiogram of Case 3 at his first ERCP shows a dilated CBD of 18.9 mm diameter with multiple small stones within.



**Fig. 3b** Cholangiogram of Control 3 shows a dilated CBD of 12.6 mm diameter with two small stones within.

**CONTROL 1**

LBK was a 71-year-old who had an ERCP for painful obstructive jaundice six months after an open cholecystectomy for a perforated GB with intra-operative drainage of a liver abscess. At ERCP, two stones were extracted. His CBD diameter was 11.4 mm (Fig. 1b).

**CASE 2**

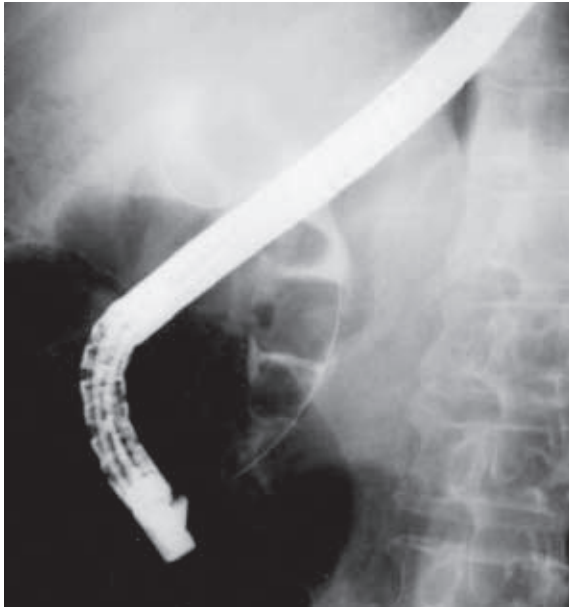LWK was a 69-year-old OA who had a left nephrectomy for staghorn calculus. In the work-up to his operation, he was found to have a dilated CBD (14.2 mm diameter) incidentally (Fig. 2a). As he had no biliary symptoms whatsoever, he refused further investigation. His liver enzymes were normal. He was born in Malaysia.

**CONTROL 2**

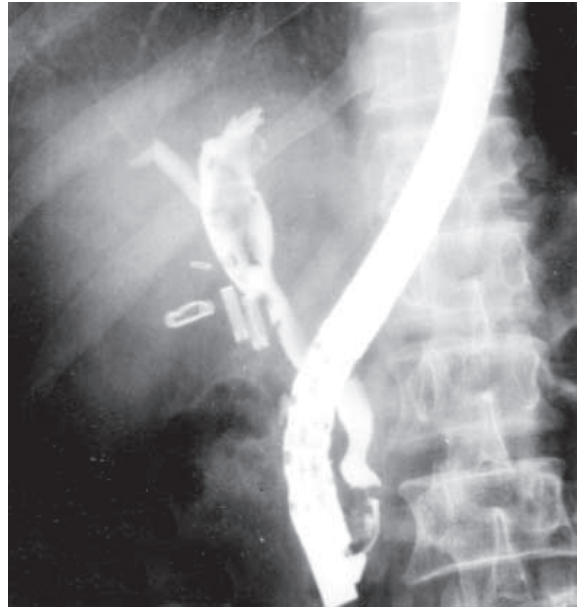
B was a 69-year-old man with hypertension and benign positional vertigo. His CBD diameter, unrelated to the patient's presenting clinical condition, was measured at 1.8 mm (Fig. 2b).

**CASE 3**

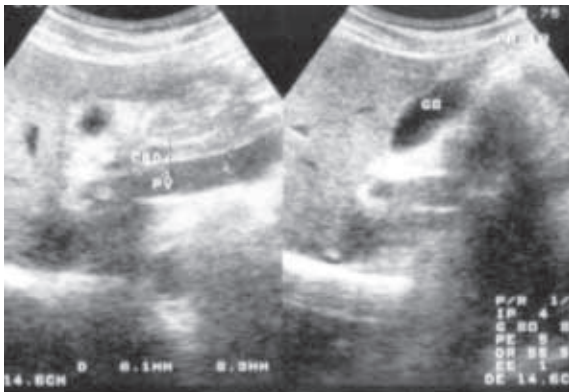
THP was a 64-year-old Malaysian-born OA who had an ERCP for acute cholangitis two months after he was treated for a liver abscess. His CBD diameter was 18.9 mm (Fig. 3a). Multiple small pigment stones were extracted. Laparoscopic cholecystectomy was recommended but he declined. Two and a half years later he had another ERCP, this time for stone impaction. This was followed by a laparoscopic cholecystectomy.



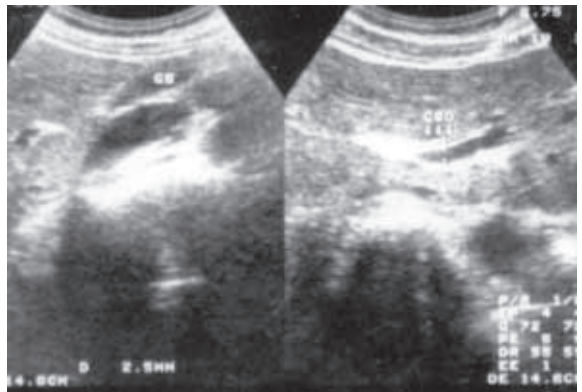
**Fig. 4a** Cholangiogram of Case 4 at his first ERCP shows a dilated CBD of 22.7 mm diameter with three large stones within.



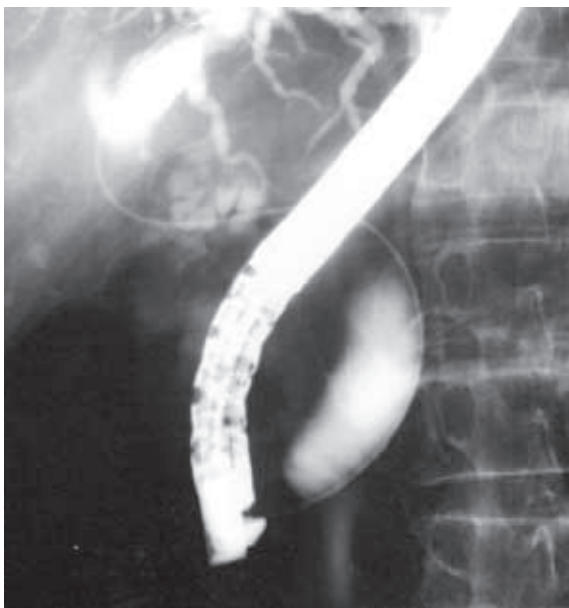**Fig. 4b** Cholangiogram of Control 4 at his first ERCP shows a dilated CBD of 14.0 mm diameter and choledocholithiasis.



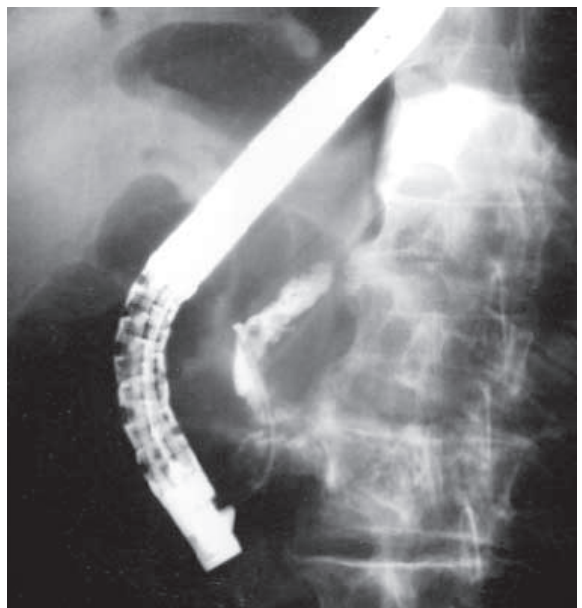
**Fig. 5a** Ultrasonogram of Case 5 shows a dilated CBD of 8.3 mm diameter.



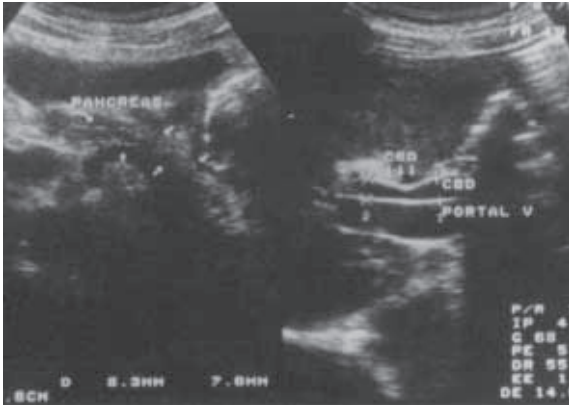
**Fig. 5b** Ultrasonogram of Control 5 shows a CBD diameter of 2.5 mm.



**Fig. 6a** Cholangiogram of Case 6 at his first ERCP shows a dilated CBD of 18.2 mm diameter.



**Fig. 6b** Cholangiogram of Control 6 when his stent was changed six months after his initial ERCP. By then there had been significant tumour in-growth into the distal CBD.



**Fig. 7a** Ultrasonogram of Case 7 shows a dilated CBD of 8.3 mm diameter.

### CONTROL 3

LKT was a 64-year-old man who had ERCP for painful obstructive jaundice. Two small CBD stones were extracted. His CBD diameter was 12.6 mm (Fig. 3b).

### CASE 4

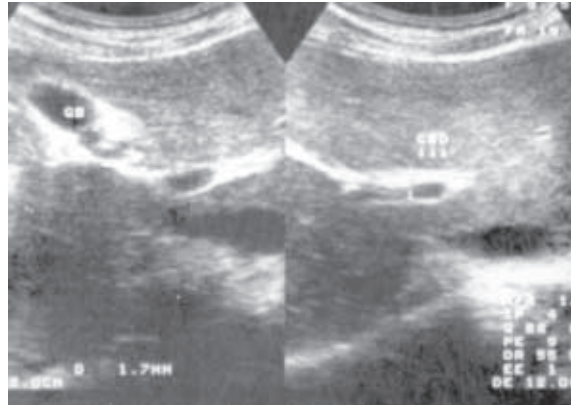
THC was a China-born 67-year-old carrier of hepatitis B virus with cirrhosis, portal hypertension, oesophageal varices, thrombocytopenia and a prolonged prothrombin time who presented with acute cholangitis. ERCP revealed three large stones (Fig. 4a) within a dilated CBD (22.7 mm diameter). In view of his concurrent chronic liver disease, a biliary stent was inserted with no attempts made at stone removal. Eleven months later, his varices were ligated when he presented with haematemesis and melaena. Twenty months after his initial ERCP, he became jaundiced again. Despite stent change, he died of complications of liver cirrhosis a month later.

### CONTROL 4

LCK was a 67-year-old man who presented with a liver abscess more than five years after a laparoscopic cholecystectomy. Ultrasonography revealed a dilated CBD (14.0 mm) and he was referred for ERCP (Fig. 4b). He had two failed ERCP stone extraction six months apart. On both occasions, a stent was inserted as a temporising measure.

### CASE 5

PSF was a 63-year-old Malaysian-born Chinese who started using opium in order to relieve his intractable epigastric pain. Gastroscopy revealed a large pre-pyloric ulcer. Rapid urease test was positive. Despite *Helicobacter pylori* eradication and healing of his ulcer, he has continued to ingest opium. Ultrasonography to elucidate the cause of his epigastric pain revealed a dilated CBD of 8.3 mm diameter (Fig. 5a) but



**Fig. 7b** Ultrasonogram of Control 7 shows a CBD diameter of 1.7 mm.

no gallbladder or CBD stones. The dilated CBD was probably etiologically not related to the patient's presenting complaint.

### CONTROL 5

GCO was a 63-year-old man who had a colonoscopy for recent onset constipation. This was normal. Routine abdominal ultrasonography revealed a CBD diameter of 2.5 mm (Fig. 5b) and no gallstone.

### CASE 6

CAS was a 69-year-old Malaysian-born OA who had ERCP for painless obstructive jaundice. His papilla was swollen and ulcerated. His CBD was dilated along its entire length (18.2 mm diameter) with no filling defect within (Fig. 6a). A Wilson-Cook Cotton-Leung biliary stent was hence inserted. Ampullary biopsy revealed a moderately differentiated adenocarcinoma. He was advised to have a Whipple operation but declined. His biliary stent was changed eight months later.

### CONTROL 6

CYC was a 71-year-old who had an almost identical history. He had an ERCP for painless obstructive jaundice. His papilla was swollen and his CBD was dilated at 14.0 mm diameter with no filling defect within. A 9 cm Wilson-Cook Cotton-Leung biliary stent was inserted. Ampullary biopsy revealed a moderately differentiated adenocarcinoma. He was advised to have a Whipple operation but declined. His biliary stent was changed six months later (Fig. 6b) and he passed away 10 months after the initial diagnosis.

### CASE 7

NKM was a 46-year-old Malaysian-born Chinese who presented with non-specific bilateral subcostal pain. Clinical examination did not reveal any physical abnormalities. He was referred for ERCP

when ultrasonography revealed a dilated CBD of 8.3 mm diameter (Fig. 7a). Other ultrasonographic findings included a hyperechogenic liver with coarse parenchyma suggesting early cirrhosis, splenomegaly of 13.9 cm in size and a normal gallbladder. At presentation on 17 April 2000, his bilirubin, alkaline phosphatase (normal range: 39 to 117 IU/l), aspartate transaminase, alanine transaminase, albumin (normal range: 38 to 51 g/l) and international normalised ratio were 12  $\mu$ mol/l, 172, 61, 82 IU/l, 37 g/l and 1.25 respectively. On further questioning, he volunteered that he was an intravenous drug abuser more than 10 years ago. He weaned himself off intravenous drugs six years ago by consuming opium, which he has since remained hooked on. Hepatitis C virus antibody was positive and hepatitis C cirrhosis was concluded to be the cause of his raised liver enzymes with opium as the cause of his dilated CBD, unrelated to his presenting complaint. His bilirubin, alkaline phosphatase, aspartate transaminase and alanine transaminase were 12  $\mu$ mol/l, 153, 56 and 75 IU/l respectively more than two weeks later on 2 May 2000.

#### CONTROL 7

TTC was a 46-year-old man with non-ulcer dyspepsia. His CBD was 1.7 mm wide (Fig. 7b) with no gallstones in the gallbladder or the CBD.

#### DISCUSSION

Considering the common occurrence of gallstones in various communities<sup>(2,3)</sup>, it was surprising that none of Yap's 16 OA had gallstones. Morphine<sup>(4)</sup> and opioids<sup>(5)</sup> have been shown to cause functional obstruction of the CBD and sphincter of Oddi spasm. Morphine has also been shown to reduce the flow of radiographic contrast into the duodenum<sup>(6,7)</sup>. Stasis has long been thought to be a factor contributing to gallstone formation<sup>(8)</sup>. Morphine and opioids also tend to cause constipation even after a few doses, let alone with chronic usage. Recently constipation has also been recognised as a cause of gallstone disease<sup>(9)</sup>. Therefore one would expect OA to have a higher incidence of gallstones. Our study was not designed to look at the incidence of gallstones in OA. It is unlikely that such a study could be done, as OA are few in number. However it would be possible to look at the incidence of gallstones in drug addicts in general and we await such a study.

Should OA with biliary symptoms be treated any differently from non-OA with biliary symptoms? Our study has shown that even when matched for

the same clinical diagnosis of the biliary tree, OA still have larger CBD diameters than non-OA and in the presence of biliary symptoms, OA should be treated no differently from non-OA when it comes to organic biliary pathology. The indications for ERCP remain the same<sup>(10)</sup> of which a dilated CBD per se is not<sup>(11)</sup>.

What about functional biliary disorders? CBD dilatation in OA is probably because morphine<sup>(4)</sup> and opioids<sup>(5)</sup>, including opium, cause sphincter of Oddi spasm, increasing CBD pressure chronically, resulting in functional obstruction of the CBD. Opioid abusers, in this case OA, are effectively inducing sphincter of Oddi dysfunction (SOD) in themselves, except that their biliary pain may have been dampened by the chronic opioid usage. Although SOD is more frequently diagnosed after cholecystectomy, it can exist in the presence of an intact gallbladder<sup>(12)</sup>. SOD has been classified into types I, II and III<sup>(13,14)</sup>. But unlike SOD where only type I responds predictably to endoscopic sphincterotomy (ES)<sup>(13,15)</sup> for reasons indicated above, a drainage procedure, usually ES, is a must when doing ERCP on OA even when there is no organic biliary pathology detected.

Opium addiction is now less common, but abuse of newer opioids, like heroin, cannabis, marijuana, amphetamines and "Ecstasy" are on the increase. The human immunodeficiency virus (HIV) can be transmitted through the sharing of contaminated needles during intravenous drug abuse. AIDS-related biliary tract disorders are acalculous cholecystitis and the AIDS cholangiopathy syndrome<sup>(16)</sup>. AIDS cholangiopathy includes a spectrum of biliary tract abnormalities of papillary stenosis and/or sclerosing cholangitis, and long extra-hepatic bile duct strictures<sup>(16)</sup>. Features of papillary stenosis in AIDS are CBD >8 mm, contrast material empties in >30 minutes, sphincter of Oddi pressure >40 mmHg and 2 to 4 mm tapering of the distal CBD<sup>(16)</sup>. All seven OA, in our study, had CBD diameter >8 mm with a mean of 15.7 mm. In Yap's study<sup>(1)</sup>, contrast retention was >1 hour in two OA who had ERCP, >6 hours in the patient who died after ERCP and 90 to 300 minutes in another three OA who had biliary scintigraphy. Based on the above findings, we would like to propose that all intravenous drug abusers, be they current or previous, should be analysed separately in all future research on AIDS cholangiopathy, as they are confounding factors.

Opium addict is a dying breed but abusers of newer opioids are not. Much can be learned from old diseases and applied to the new.

## REFERENCES

1. Yap CK, Chong R, Ng HS. Dilated common bile duct in opium addicts: old disease, new observations for the biliary endoscopist [abstract]. *J Gastro Hepatol* 1995; 10 (suppl 3):A96, K127.
2. Heaton KW, Braddon FEM, Montford RA, et al. Symptomatic and silent gallstones in the community. *Gut* 1991; 32:316-20.
3. Khuroo MS, Mahajan R, Zargar SA, et al. Prevalence of biliary tract disease in India: A sonographic study in adult population in Kashmir. *Gut* 1989; 30:201-5.
4. Helm JF, Venu RP, Geenen JE, et al. Effects of morphine on the human sphincter of Oddi. *Gut* 1988; 29:1402-7.
5. Joehl RL, Koch KL, Nahrwold DL. Opioid drugs cause bile duct obstruction during hepatobiliary scans. *Am J Surg* 1984; 147:134-8.
6. Dedrick DF, Tanner WW, Bushkin FL. Common bile duct pressure during enflurane anaesthesia. Effects of morphine and subsequent naloxone. *Arch Surg* 1980; 115:820-2.
7. Chessick KC, Black S, Hoye SJ. Spasm and operative cholangiography. *Arch Surg* 1975; 110:53-7.
8. Pomeranz IS, Shaffer EA. Abnormal gall bladder emptying in a subgroup of patients with gallstones. *Gastroenterology* 1985; 88:787-91.
9. Misciagna G, Leoci C, Guerra V, et al. Epidemiology of cholelithiasis in southern Italy. Part II: Risk factors. *Eur J Gastroenterol Hepatol* 1996; 8:585-93.
10. Gilmore IT. MRCP: examining the obstructed bile duct. *Gut* 1998; 43:597-8.
11. Wilkinson ML. Are dilating bile ducts a cause for concern. *Gut* 1999; 45:637-8.
12. Shaffer EA. Morphine and biliary pain revisited. *Gut* 2000; 46:750-1.
13. Hogan WJ, Geenen JE. Biliary dyskinesia. *Endoscopy* 1988; 20 (suppl 1):179-83.
14. Geenen JE, Hogan WJ, Dodds WJ, et al. The efficacy of endoscopic sphincterotomy after cholecystectomy in patients with sphincter of Oddi dysfunction. *N Engl J Med* 1989; 320:82-7.
15. Rolny P, Geenen JE, Hogan WJ. Post-cholecystectomy patients with objective signs of partial bile outflow obstruction: clinical characteristics, sphincter of Oddi manometry findings, and results of therapy. *Gastrointest Endosc* 1993; 39:778-81.
16. Tanowitz HB, Simon D, Weiss LM, et al. Gastrointestinal manifestations. In: *Management of the HIV-infected patient, Part 1*. *Med Clin North Am* 1996; 80:1395-414.