

# Restenosis In Percutaneous Coronary Intervention – Is Drug-Eluting Stent the Answer?

VYT Lim, Y L Lim

## ABSTRACT

**The long-term success of percutaneous coronary intervention in the treatment of coronary artery disease is hampered by the occurrence of restenosis, which often necessitates repeat hospitalisations or coronary interventions. The advent of drug-eluting stents, particularly those coated with sirolimus and paclitaxel, may be the breakthrough in the battle against restenosis that interventional cardiologists have been waiting for, and we review the currently available evidence for this. Despite the growing enthusiasm, we should not forget that this new technology is still in its relative infancy, and there remain many unanswered questions, particularly about the long-term effect of using these stents.**

**Keywords:** angioplasty, drug-eluting stent, paclitaxel, restenosis, sirolimus

*Singapore Med J 2003 Vol 44(9):482-487*

## INTRODUCTION

Percutaneous coronary intervention (PCI) has revolutionised the treatment of coronary artery disease, which remains one of the major causes of mortality in developed nations throughout the world, including Singapore. It is used to treat patients with both stable angina and acute coronary syndromes, and is also the treatment of choice in acute ST-elevation myocardial infarction. PCI is popular with patients as, compared with coronary artery bypass grafting (CABG), major surgery can be avoided, a shorter hospitalisation is involved, and the initial costs are generally lower. Furthermore, the immediate technical success rate is high, and the procedural mortality and morbidity rate is low.

However, restenosis at the site of angioplasty continues to hamper the long-term success of PCI, with the result that a significant proportion of patients have to undergo repeat revascularisation. Since the first balloon angioplasty was performed in 1977 by Andreas Gruntzig<sup>(1)</sup>, the introduction of coronary stents from the mid-1980s was the last major technical development to significantly improve the result of PCI<sup>(2)</sup>. Compared with

plain old balloon angioplasty (POBA), stenting has been shown to significantly reduce the incidence of restenosis to about 20-30%, as demonstrated by the landmark STRESS and BENESTENT studies<sup>(3,4)</sup>, though the actual rate of restenosis would be higher when stenting is performed in more difficult lesion subsets such as small or diabetic vessels. On the other hand, the era of stenting has brought about a new problem of in-stent restenosis. Over the last decade, much research has been dedicated to finding a way of reducing restenosis, although results were usually disappointing. Only brachytherapy has proved effective in reducing in-stent restenosis, although the technology is expensive, cumbersome and involves the use of radiopharmaceuticals with its concomitant problems and restrictions<sup>(5)</sup>. However, with the advent of drug-eluting stents (DES), we may have the answer that we've been looking for. It's very attraction lies in its simplicity; any interventional cardiologist will be able to use it, with no further training or new equipment required.

## The basis for drug-eluting stents

The pathophysiology of restenosis after angioplasty is basically due to two major components: elastic recoil and excessive neointimal proliferation. Catheter-induced injury results in denuding of the intima and stretching of the media and adventitia. The wound-healing reaction stimulates platelets, growth factor and smooth muscle cell (SMC) activation, followed by SMC and fibroblast migration and proliferation into the injured area. Stenting largely eliminates the mechanical problem of elastic recoil. However, the elimination of exaggerated smooth muscle cell proliferation is far more complicated.

Coating stents with pharmaceutical agents is not a new idea. It has an inherent advantage over systemic administration, with the ability to precisely deliver a much lower dose of the drug to the target area thus achieving high tissue concentration while minimising the risk of systemic toxicity. Some of the commercially available stents are coated with heparin or phosphorylcholine, as studies have shown evidence that these reduce the risk of sub-acute stent thrombosis<sup>(6,7)</sup>.

Division of Cardiology  
Changi General  
Hospital  
2 Simei Street 3  
Singapore 529889

V Y T Lim, MB ChB,  
MRCP (UK)  
Associate Consultant

Centre of  
Cardiovascular  
Therapeutics  
Western Health  
University of  
Melbourne  
Victoria 3011  
Australia

Y L Lim, PhD,  
FRACP, FACC  
Professor & Director

Correspondence to:  
Dr Victor Y T Lim  
Tel: (65) 6850 3562  
Fax: (65) 6260 9173  
Email: victor\_lim@  
cgh.com.sg

**Table I. Summary of current clinical trials involving the use of drug-eluting stents.**

DRUG	CLINICAL TRIALS	LESION TYPE	RESULTS
Sirolimus	FIM <sup>(12,13)</sup> (n=45)	De novo	Inhibition of neointimal hyperplasia at 24 months
	RAVEL <sup>(14)</sup> (n=238)	De novo	RS rate at 6 months: 0% (DES) vs 26.6% (BS)
	SIRIUS <sup>(16)</sup> (n=1100)	De novo	In-segment RS rate at 8 months: 8.9% (DES) vs 36.3% (BS)
	Sousa et al <sup>(18)</sup> (n=25)	In-stent restenosis	RS rate at 1 year: 4% (1 patient)
Paclitaxel	TAXUS I <sup>(23)</sup> (n=61)	De novo	RS rate at 6 months: 0% (DES) vs 10% (BS)
	TAXUS II <sup>(25)</sup> (n=536)	De novo	In-segment RS rate at six months: 5.5% (DES) vs 20.1% (BS) in slow-release stent cohort 8.6% (DES) vs 23.8% (BS) in moderate-release stent cohort
	TAXUS III <sup>(24)</sup> (n=28)	In-stent restenosis	RS rate at 6 months: 16% (4/25 pts with angiographic FU)
	ASPECT <sup>(20)</sup> (n=177)	De novo	RS rate at 6 months: 4% (high-dose DES) vs 27% (BS)
	ELUTES <sup>(22)</sup> (n=192)	De novo	RS rate at 6 months: 3% (high-dose DES) vs 21% (BS)
	SCORE	De novo	Trial stopped early due to high rates of MACE
Dexamethasone	STRIDE <sup>(27)</sup>	De novo	RS rate of 13.3% at 6 months
Everolimus	FUTURE I <sup>(28)</sup>	De novo	RS rate at 6 months: 0% (DES) vs 9.1% (BS)
Actinomycin D	ACTION	De novo	Trial halted due to high restenosis rate

BS: Bare stent, DES: Drug-eluting stent, MACE: Major adverse cardiac event, RS: Restenosis.

It is logical to take this idea to the next step, which is to coat the stent with a biologically active agent that will reduce or prevent exaggerated neointimal proliferation, and thereby, restenosis.

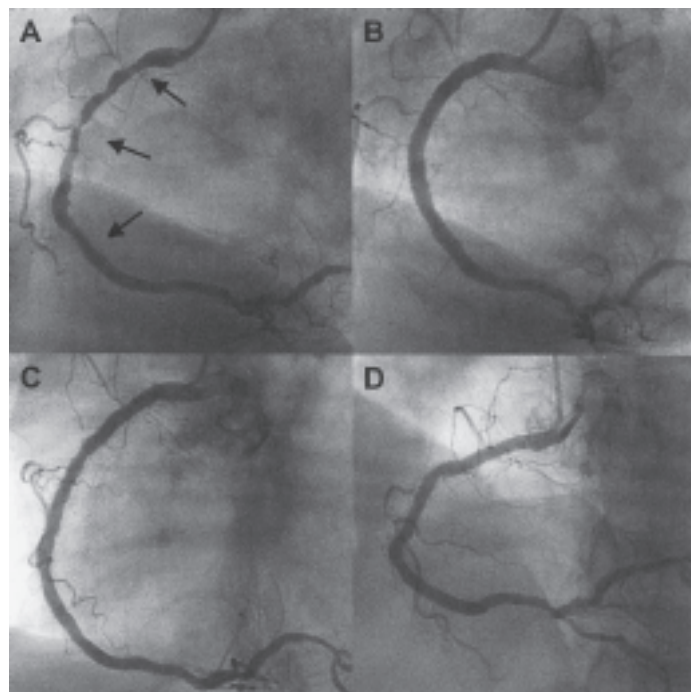
#### Biological agents used in drug-coated stents

A wide variety of biological agents have been, or are being, investigated to determine its potential in countering restenosis (Table I). Two drugs in particular have shown clear benefit in clinical trials – these two are sirolimus and paclitaxel (Fig. 1).

#### Sirolimus

Sirolimus (Rapamycin) is a natural macrocyclic lactone that is a natural fermentation product of *Streptomyces hygroscopicus*, which was originally identified in a soil sample from Rapa Nui (Easter Island). It was a failed antibiotic that was latterly found to have potent immunosuppressant properties, which led to it being used as an oral agent to prevent rejection of renal transplant patients<sup>(8)</sup>. Its evolution to a promising cardiovascular drug came with the discovery that it also had the ability to inhibit cytokine-mediated and growth-factor-mediated proliferation of lymphocytes and smooth muscle cells, thereby acting as a cytostatic agent and reducing neointimal proliferation after PCI, as confirmed in a small clinical study<sup>(9)</sup>.

The Cypher™ sirolimus-eluting stent (Cordis/Johnson & Johnson) is the first commercially available DES in Singapore, and currently has three years follow-up data supporting its safety and efficacy. The First-In-Man (FIM) study, where 45 patients with de novo coronary disease were treated with sirolimus-eluting



**Fig. 1** This patient was one of the first in Singapore to receive a drug-eluting stent. A. Left anterior oblique view of right coronary artery (RCA) shows diffuse significant stenosis from the proximal to mid-segments (indicated by arrows). B. 4 overlapping paclitaxel-eluting stents were deployed with good results. C. Six months' follow-up angiography shows that the stented segments remained widely patent, with only mild in-stent restenosis seen. D. Cranial angulated view of the RCA shows the excellent angiographic appearance at six months.

stent, demonstrated that at up to 24 months, neointimal hyperplasia, as detected by intravascular ultrasound, was virtually absent, and there were no subacute or late thrombosis<sup>(10-13)</sup>. The RAVEL study provided more vigorous data confirming clinical efficacy in reducing restenosis and associated clinical events. In this trial,

238 patients were randomised to receive either a sirolimus-eluting or standard uncoated stent to treat a de novo coronary lesion. At six months, the degree of neointimal proliferation was significantly lower in the sirolimus-stent group, and there was 0% in-stent restenosis compared with 26.6% for the standard-stent group ( $P < 0.001$ ). At one year, there was also a significantly lower rate of major adverse cardiac events (MACE) of 5.8% for sirolimus-stent group, compared with a 28.8% rate in the standard-stent group ( $P < 0.001$ ); this difference was due entirely to a higher rate of percutaneous revascularisation of the target lesion in the standard-stent group. These encouraging results were also maintained in the diabetic sub-group<sup>(14)</sup>. The recently presented two-year follow-up results were positive, with significantly better event-free survival in the DES group (97.5% vs. 86.4% in bare-stent arm) and with no stent thromboses<sup>(15)</sup>.

The most comprehensive study to date is the SIRIUS study, a multicentre randomised trial involving larger patient numbers (1,058 patients) and a more “real world” patient cohort than RAVEL, with a larger proportion (26.4%) of diabetic patients and involving more complex lesions such as small vessels, long lesions and multivessel disease. Angiographic analysis at eight months demonstrated that the use of the Cypher™ stent resulted in significant reduction of in-stent binary restenosis rate by a remarkable 91% (3.2% vs. 35.4% with standard-stent group;  $P < 0.001$ ). However, when the areas 5 mm proximal and distal to the stent margins (peri-stent area) were also analysed, the restenosis rate (here defined as “in-segment restenosis”) was higher at 8.9% with the DES and 36.3% in control group; this is mainly due to increased rate of proximal margin peristent restenosis especially in smaller vessels. The increased peri-stent restenosis with the use of Cypher™ stent could be the result of collateral balloon injury outside the stented area that is not covered with the DES. This problem may be overcome by matching the length of the balloon and the stent, thereby limiting the balloon injury zone, or by using longer lengths of coated stents to cover the diseased segment. The primary endpoint of target vessel failure at nine months (defined as cardiac death, myocardial infarction or target vessel revascularisation) was significantly reduced by 59%, from 21.0% with control to 8.6% with sirolimus<sup>(16)</sup>. The one-year follow-up data showed sustained benefit, with a MACE-free rate of 91.7% in the DES arm, compared with 77.4% in the bare-stent arm<sup>(17)</sup>. A recent small pilot study of 25 patients also demonstrated that the use of sirolimus-eluting stents for the treatment of in-stent restenosis appeared to be safe and feasible; follow-up angiography at one-year showed that only one patient

developed in-stent restenosis, and there were no deaths, stent thromboses or repeat revascularisations<sup>(18)</sup>.

### Paclitaxel

Paclitaxel, originally isolated from the bark of the Pacific yew tree, *Taxus brevifolia*, had been used as an antineoplastic agent to treat several types of cancer, most commonly breast and ovarian cancer. It is regarded as a cytotoxic drug, and its efficacy in reducing neointimal proliferation and restenosis is due to its unique mechanism of action in promoting the assembly of tubulin into extraordinarily stable microtubules, thereby interrupting cellular proliferation, migration and signal transduction<sup>(19)</sup>.

The promise of paclitaxel as an anti-restenotic agent when used as a stent coating had been shown in the results of a few early trials. In ASPECT, a multicentre prospective randomised study involving 177 patients with de novo lesions, the six-month angiographic results showed a significant reduction in binary restenosis in patients who received a high-dose paclitaxel-coated stent (4% vs. 27% in bare stent group;  $P < 0.001$ )<sup>(20)</sup>. Similar results were seen in the ELUTES trial, which recruited 192 patients with de novo lesions. No difference in MACE was seen at six months. At 12 months, there was significant reduction in target vessel revascularisation (5% in the highest dose-density paclitaxel-coated group vs. 16% in bare stent group). There was no late thrombosis or death in the drug-eluting group<sup>(21,22)</sup>. It is important to note that the paclitaxel-eluting stents used in these two trials (made by Cook Inc) are non-polymer-based; some quarters believe that most, if not all, polymers will stimulate some neointimal proliferation in itself.

In contrast, the paclitaxel-stent used in the TAXUS series of trials has a unique polymer carrier that allows a more consistent and predictable paclitaxel release, while maintaining vascular compatibility. The TAXUS I trial, a prospective, randomised, double-blind feasibility trial involving 61 patients with de novo lesions, demonstrated a trend towards reduction in six-months angiographic binary restenosis rate (0% with paclitaxel-coated stent vs. 10% with bare stent;  $P = \text{NS}$ ). At 12 months, the MACE rate was 3% in the TAXUS group and 10% in the control group ( $P = \text{NS}$ )<sup>(23)</sup>. TAXUS III, a small single-arm study assessing the safety and efficacy of using the paclitaxel-coated stent in 28 patients with in-stent restenosis, showed a binary restenosis rate of 16% (four patients) in the 25 patients who underwent a six-month follow-up angiography. However, in three of these patients, the restenoses occurred in an area where there was no local delivery of paclitaxel, for example, the gap between two DES where no overlapping of stents occurred.

Overall, these results were promising with regard to the use of DES in this difficult lesion subset<sup>(24)</sup>.

TAXUS II is the most important trial so far involving paclitaxel-stent. A total of 536 patients worldwide with de novo lesions were randomised to either a bare or paclitaxel-coated stent, in either a slow (Cohort I) or moderate release formulation (Cohort II). At six months, patients who had paclitaxel-stents in both cohorts showed significant improvements in clinical, angiographic and intravascular ultrasound IVUS endpoints compared to controls. The in-stent restenosis rate was reduced from 17.9% to 2.3% in cohort I and from 20.2% to 4.7% in cohort II, in-segment restenosis from 20.1% to 5.5% in cohort I and from 23.8% to 8.6% in cohort II, and MACE rate from 19.5% to 8.5% in cohort I and from 20.0% to 7.8% in cohort II. Again, it was reassuring to see that there was no increased incidence of complications such as stent thrombosis or aneurysm formation in the paclitaxel-stent group<sup>(25)</sup>. The TAXUS™ paclitaxel-coated stent (Boston Scientific Scimed Inc) is now also commercially available in Singapore.

Amidst the trend of positive data for paclitaxel, there were some trials which have not been so encouraging. SCORE, a randomised multicentre study treating de novo lesions, was stopped early after the recruitment of 266 patients as a result of unacceptably high rates of stent thrombosis (9.4%) and myocardial infarction (14.5%) in the DES group. The stent used here (made by Quanam Medical) has a polymer sleeve eluting taxane, a paclitaxel derivative. The reason for the poor results may be due to the particular type of stent used in this study and the high concentrations of taxane used. Another trial using the same type of DES in in-stent restenosis showed that the initial excellent antiproliferative effect at six months was not maintained at 12 months, resulting in delayed occurrence of angiographic restenosis<sup>(26)</sup>. These failures suggest that the exact type of biological agents or polymers used could be crucial; the taxane used in these stents is not the same as the paclitaxel used in the TAXUS™ stents. The DELIVER trial, using the non-polymerised Cook Achieve™ paclitaxel-stent, was also terminated early after suboptimal results showing non-significant reduction in binary restenosis and target vessel failure compared to the bare-stent study arm.

#### **Other biological agents under investigation**

Dexamethasone, an anti-inflammatory agent, is being evaluated as a potential anti-restenotic compound for stent delivery. STRIDE, a pilot, prospective, non-randomised trial in de novo lesions showed a six-month restenosis rate of 13.3%, which was quite acceptable but still relatively high if compared with

the 0% six-month restenosis rate seen in the RAVEL and TAXUS I trial<sup>(27)</sup>. Further trials are required to compare its efficacy with bare stents.

Everolimus, a sirolimus analogue, also appears promising. The six-months follow-up results of the randomised FUTURE I trial evaluating everolimus-coated Challenge™ stent (Biosensors International) showed no binary restenosis in the everolimus arm of the trial, compared with 9.1% in the control patients. In this small trial of 42 patients, there was no significant difference in death or MACE rates<sup>(28)</sup>.

Some biological agents showed disappointing results when evaluated in human population. An example of this is actinomycin D, an antibiotic used for its antiproliferative properties in the treatment of various malignant neoplasms such as Wilms tumour and sarcomas. The ACTION trial involving Actinomycin-D-coated stent (Guidant) was halted early, as there was an unacceptably high restenosis rate in the first 90 patients.

#### **Unresolved issues**

There is no doubt that drug-eluting stents, with its potential to vanquish coronary angioplasty's Achilles heel of restenosis, have caused great excitement not only in the world of interventional cardiology, but also in the world at large. A large proportion of PCI done today are repeat procedures necessitated by the occurrence of restenosis, and the promise of a 'fire and forget' stent, with confidence that a repeat coronary revascularisation is not likely to be required, can only benefit patients. However, we should remember that there are only short- and medium-term data involving mostly simple lesions, with long-term safety and efficacy data currently unavailable. There is some worry about what happens when we interfere with the natural healing process of an artery subjected to mechanical intervention; some animal studies have demonstrated that the anti-proliferative effects are sometimes accompanied by evidence of eventual intimal inflammation, fibrin degradation and plaque haemorrhage.

Toxic effects from the anti-proliferative drugs used, such as neutropenia, are theoretically possible but have not been seen so far, probably because the dosage used are far smaller than those used in cancer therapy. There is a concern regarding late stent thrombosis, as the anti-proliferative drugs will tend to delay endothelialisation of the stent surface, but this does seem to be rare. There was a recent report of a case of late stent thrombosis occurring as an acute event; this occurred in a patient seven months after implantation of a paclitaxel-eluting stent, soon after the cessation of ticlopidine therapy, even though aspirin was continued<sup>(29)</sup>. The one-year SIRIUS data also showed a 0.4% incidence of stent thromboses

in patients receiving the Cypher™ stents, after three months of combined antiplatelet therapy<sup>(17)</sup>. On the other hand, the FIM trial with sirolimus-eluting stent showed no cases of late thrombosis up to 35 months follow-up<sup>(41)</sup>. A longer period of combined anti-platelet therapy is recommended when DES is used. Aspirin should be continued indefinitely if possible, and clopidogrel (or ticlopidine) is used for three to six months although the optimal duration is yet to be established.

Other potential adverse effects of drug-eluting stents include late positive remodelling with aneurysm or pseudoaneurysm formation, perforation, accelerated atherosclerosis, fibrosis, and systemic disorders, although we have no evidence of these so far. This is a serious issue to consider; even a late complication rate of 0.5% could affect >10,000 lives each year, assuming that about two million coronary angioplasties are performed each year worldwide<sup>(30)</sup>. The other concern is whether the eluted drug merely delays, rather than prevent, the proliferative response. In trials of brachytherapy, small trends toward late “catch-up” were observed only after at least three years of follow-up. The five-year SCRIPP trial results demonstrated that while brachytherapy continued to result in significantly lower rates of target lesion revascularisation TLR, the benefit is lessening over the years with gradually increasing TLR rates<sup>(5)</sup>. The recent two-year RAVEL results reassuringly demonstrated sustained benefits so far but longer-term results are required before we can answer the question as to whether DES actually prevent, or just simply delay, restenosis<sup>(15)</sup>. With regard to in-stent restenosis, there is still a continuing need for brachytherapy at present, as it is still the only proven effective treatment for this particular problem, and there is still limited data about the efficacy of DES in this lesion subset.

Despite these reservations, the euphoria about DES remains, and the next few years will see studies published on the use of DES in increasingly challenging PCI cases, such as multivessel disease, diabetic patients, small vessels, long lesions, left main stenosis, bifurcations and saphenous vein grafts lesions. One of the most important areas under investigation will be to assess the safety and efficacy of using DES in multivessel disease, especially diabetic patients. Current data show that, in non-diabetic patients, multivessel stenting with conventional bare stents is comparable to CABG, with similar rates of death, stroke or myocardial infarction after one year, although patients who underwent stenting had a significantly higher rate of repeat revascularisation<sup>(31)</sup>. Diabetic patients with

multivessel disease who underwent PCI are also known to have poorer long-term outcome, compared with those who had CABG<sup>(32)</sup>. However, the treatment strategy for these patients may well change with the availability of DES.

Drug-coated stents are expensive; at a cost of about S\$3,500 to S\$4,500 per stent, they cost two to three times more than a bare metal stent. Initial analyses of the use of sirolimus-eluting stents in simple lesions have suggested a favourable cost-effectiveness profile in reducing repeat revascularisations and major cardiac events. However, further studies in more “real world” PCI cases are required before we can have a better idea of how cost-effective DES really are<sup>(33)</sup>.

## CONCLUSIONS

The use of DES is likely to reduce restenosis rate to less than 10%. However, it remains to be seen whether the early promise shown can be maintained without any significant deleterious longer-term side effects. Many questions, such as the optimal drug and local drug delivery system, the optimal dose of the drug to be used, and the rate and duration of drug-release over time, remain unanswered. The long-term efficacy of DES in traditionally challenging lesion subsets such as left main stem stenosis, long lesions, ostial or bifurcation lesions are as yet unclear. The results of trials released over the next few years will show us whether DES is just another false dawn or the most exciting development so far in the brief history of PCI.

## REFERENCES

1. Gruntzig A. Transluminal dilatation of coronary-artery stenosis. *Lancet* 1978; 1:263.
2. Sigwart U, Puel J, Mirkovitch V, Joffre F, Kappenberg L. Intravascular stents to prevent reocclusion and restenosis after transluminal angioplasty. *N Engl J Med* 1987; 316:701-6.
3. Fischman DL, Leon MB, Baim DS, Schatz RA, Savage MP, Penn I, et al. A randomized comparison of coronary stent placement and balloon angioplasty in the treatment of coronary artery disease. *N Engl J Med* 1994; 331:496-501.
4. Serruys PW, de Jaegere P, Kiemeneij F, Macaya C, Rutsch W, Heyndrickx G, et al, for the Benestent Study Group. A comparison of balloon-expandable stent implantation with balloon angioplasty in patients with coronary artery disease. *N Engl J Med* 1994; 331:489-95.
5. Grise MA, Massullo V, Jani S, Popma JJ, Russo RJ, Schatz RA, et al. Five-year clinical follow-up after intracoronary radiation: results of a randomized clinical trial. *Circulation* 2002; 105:2737-40.
6. Serruys PW, van Hout B, Bonnier H, Legrand V, Garcia E, Macaya C, et al, for the Benestent Study Group. Randomized comparison of implantation of heparin-coated stents with balloon angioplasty in selected patients with coronary artery disease (Benestent II). *Lancet* 1998; 352:673-81.
7. Galli M, Bartorelli A, Bedogni F, DeCesare N, Klugmann S, Maiello L, et al. Italian BiodivYsio open registry (BiodivYsio PC-coated stent): study of clinical outcomes of the implant of a PC-coated coronary stent. *J Invasive Cardiol* 2000; 12:452-8.
8. Marx SO, Marks AR. Bench to bedside: the development of Rapamycin and its application to stent restenosis (Editorial). *Circulation* 2001; 104:852-5.

9. Sousa JE, Costa MA, Abizaid A, Abizaid AS, Feres F, Pinto IMF, et al. Lack of neointimal proliferation after implantation of sirolimus-coated stents in human coronary arteries: a quantitative coronary angiography and three-dimensional intravascular ultrasound study. *Circulation* 2001; 103:192-5.
10. Sousa JE, Costa MA, Abizaid AC, Rensing BJ, Abizaid AS, Tanajura LF, et al. Sustained suppression of neointimal proliferation by sirolimus-eluting stents: one-year angiographic and intravascular ultrasound follow-up. *Circulation* 2001; 104:2007-11.
11. Sousa JE, Abizaid A, Abizaid AS, Feres F, Maldonado G, et al. Late (three-year) follow-up from the First-in-Man (FIM) experience after implantation of sirolimus-eluting stents. Presented at the American Heart Association 75th Annual Scientific Session, September 17-20, 2002, Chicago.
12. Degertekin M, Serruys PW, Foley DP, Tanabe K, Regar E, Vos J, et al. Persistent inhibition of neointimal hyperplasia after sirolimus-eluting stent implantation. Long-term (up to two years) clinical, angiographic, and intravascular ultrasound follow-up. *Circulation* 2002; 106:1610-3.
13. Sousa JE, Costa MA, Sousa AGMR, Abizaid AC, Seixas AC, Abizaid AS, et al. Two-year angiographic and intravascular ultrasound follow-up after implantation of sirolimus-eluting stents in human coronary arteries. *Circulation* 2003; 107:381-3.
14. Morice M-C, Serruys PW, Sousa JE, Fajadet J, Hayashi EB, Perin M, Colombo A, et al. A randomized comparison of a sirolimus-eluting stent with a standard stent for coronary revascularization. *N Engl J Med* 2002; 346:1773-80.
15. Morice M-C, Serruys PW, Constantini C, Wuelfert E, Wijns W, Fajadet J, et al. Two-year follow-up of the RAVEL study: A randomized study with the sirolimus-eluting Bx Velocity(tm) stent in the treatment of patients with de-novo native coronary artery lesions. Presented at the American College of Cardiology 52nd Annual Scientific Session, March 30 - April 2, 2003, Chicago.
16. Moses JW, Leon MB, Popma JJ, Kuntz RE, Fitzgerald P for the SIRIUS Investigators. SIRIUS: A US multicenter, randomized, double-blind study of the sirolimus-eluting stent in de novo native coronary lesions. Presented at the Transcatheter Cardiovascular Therapeutics Scientific Session, September 24-28, 2002, Washington, DC.
17. Holmes D, Leon MB, Moses JW, Midwall J, Clark M, Palacios IF, et al. One-year follow-up of the SIRIUS study: A randomized study with the sirolimus eluting Bx Velocity(tm) stent in the treatment of patients with de novo native coronary artery lesions. Presented at the American College of Cardiology 52nd Annual Scientific Session, March 30 - April 2, 2003, Chicago.
18. Sousa JE, Costa MA, Abizaid A, Sousa AGMR, Feres F, Mattos LA, et al. Sirolimus-eluting stent for the treatment of in-stent restenosis. A quantitative coronary angiography and three-dimensional intravascular ultrasound study. *Circulation* 2003; 107:24-7.
19. Axel DJ, Kunert W, Ggelmann C, Oberhof f M, Herdeg C, K ttner A, et al. Paclitaxel inhibits arterial smooth muscle cell proliferation and migration in vitro and in vitro using local delivery drug. *Circulation* 1997; 96:636-45.
20. Park S-J, Shim WH, Ho DS, Raizner AE, Park S-W, Hong M-K, et al. A paclitaxel-eluting stent for the prevention of coronary restenosis. *N Engl J Med* 2003; 348:1537-45.
21. Gershlick AH, Descheerder I, Chevalier B, Camenzind E, Gommeaux A, Vrints C, et al. Local drug delivery to inhibit coronary artery restenosis. Data from the ELUTES (Evaluation of paclitaxel eluting stent) clinical trial. Presented at the American Heart Association 74th Annual Scientific Session, November 8-11, 2001, Anaheim, California.
22. Gershlick AH. 12 months results from the ELUTES (Evaluation of paclitaxel eluting stent) Trial. Presented at the Paris Course of Revascularization, May 21-24, 2002, Paris, France.
23. Grube E, Silber S, Hauptmann KE, Mueller R, Buellesfeld L, Gerckens U, et al. TAXUS I. Six- and twelve-month results from a randomized, double-blind trial on a slow-release paclitaxel-eluting stent for de novo coronary lesions. *Circulation* 2003; 107:38-42.
24. Tanabe K, Serruys PW, Grube E, Smits PC, Selbach G, van der Giessen WJ, et al. TAXUS III Trial. In-stent restenosis treated with stent-based delivery of paclitaxel incorporated in a slow-release polymer formulation. *Circulation* 2003; 107:559-64.
25. Colombo A. TAXUS II Trial. Presented at the Transcatheter Cardiovascular Therapeutics Scientific Session, September 24-28, 2002, Washington, DC.
26. Liistro F, Stankovic G, Di Mario C, Takagi T, Chieffo A, Moshiri S, et al. First clinical experience with a paclitaxel derivative-eluting polymer stent system implantation for in-stent restenosis: Immediate and long-term clinical and angiographic outcome. *Circulation* 2002; 105:1883-6.
27. Liu X, Huang Y, DeScheerder I, on behalf of the STRIDE investigators. Study of Antirestenosis with the BiodivYsio dexamethasone eluting stent (STRIDE): a multicenter trial. Presented at the American College of Cardiology 51st Annual Scientific Session, March 17-20, 2002, Atlanta, Georgia.
28. Grube E, Buellesfeld L, Mueller R, Staberock M, Selbach G, Schmidt T, et al. First human experience using a new everolimus stent coating: procedural and six-month follow-up results of the FUTURE Trial. Presented at the American College of Cardiology 52nd Annual Scientific Session, March 30 - April 2, 2003, Chicago.
29. Liistro F, Colombo A. Late acute thrombosis after paclitaxel eluting stent implantation. *Heart* 2001; 86:262-4.
30. Teirstein PS. Living the dream of no restenosis (Editorial). *Circulation* 2001; 104:1996-8.
31. Serruys PW, Unger F, Sousa JE, Jatene A, Bonnier HJRM, Sch nber ger JPAM, et al. Comparison of coronary-artery bypass surgery and stenting for the treatment of multivessel disease. *N Engl J Med* 2001; 344:1117-24.
32. The Bypass Angioplasty Revascularization Investigation (BARI) Investigators. Comparison of coronary bypass surgery with angioplasty in patients with multivessel disease. *N Engl J Med* 1996; 335:217-25.
33. Lemos PA, Serruys PW, Sousa JE. Drug-eluting stents. Cost versus clinical benefit. *Circulation* 2003; 107:3003-7.