

# Foreign body aspiration in adults

Zubairi A B, Haque A S, Husain S J, Khan J A

## ABSTRACT

**Foreign body aspiration is not an uncommon problem, particularly in children, the elderly, and those with predisposing factors like neurological impairment. In adults, regional differences exist in the type of foreign body aspirated. We report four cases of foreign body aspiration in South Asian adults, three of which were related to the widespread habit of chewing stimulant seeds such as betel nuts (two) and tamarind seed (one). It is important for clinicians to maintain a high index of suspicion for the diagnosis of foreign body inhalation in the appropriate clinical setting. Bronchoscopy is necessary not only for the diagnosis but also for the removal of foreign body from the bronchial tree. Once the foreign body is removed, the improvement in symptoms is usually dramatic, making it rewarding for any physician to manage.**

**Keywords: betel nut, bronchoscopy, foreign body aspiration, stimulant seeds, tamarind seed**

*Singapore Med J 2006; 47(5):415-418*

## INTRODUCTION

Foreign body aspiration is a condition seen all over the world. It can present in a variety of ways, ranging from no or trivial symptoms to irreversible damage to the lung which may be life-threatening<sup>(1)</sup>. Foreign body aspiration in adults is more common in the setting of advanced age, underlying neurological disorder, poor dentition, alcohol consumption and sedative use<sup>(2,3)</sup>. In the absence of predisposing factors, children are reported to be at a higher risk than adults. In children the aspirated material is usually an object like toys, screws and other household items. Aspiration of organic material such as nuts, seeds, vegetables and bones have been described in adults<sup>(4)</sup>. We report four adult cases of foreign body aspiration where there were no underlying risk factors.

## CASE REPORTS

### Case One

A 46-year-old woman presented with an eight-day history of distressing dry cough along with a three-day history of fever. On physical examination, she was febrile and appeared toxic. Chest examination revealed right basal dullness to percussion and reduced breath sounds. A chest radiograph showed a right lower lobe collapse. On further inquiry, it was revealed that eight days ago, she had experienced severe acute cough and choking while chewing betel quid. A fiberoptic bronchoscopic examination showed a foreign body in the bronchus intermedius with surrounding oedema. An ensuing rigid bronchoscopy allowed the successful removal of a large betel nut. The patient recovered with no residual symptoms and re-expansion of the right lower lobe.

### Case Two

A 62-year-old woman was admitted with a two-month history of cough, intermittent fever and dyspnoea. She had received multiple courses of different antibiotics during this period. On physical examination, wheezes and crackles were present on the right side of the chest. A chest radiograph revealed right mid-zone infiltrates with no significant collapse. A flexible fiberoptic bronchoscopy was done to evaluate the aetiology of her symptoms. This showed a foreign body impacted in the bronchus intermedius. A subsequent rigid bronchoscopy, allowed the successful removal of the foreign body, which was later identified as a betel nut. She recovered with no lasting consequences.

### Case Three

A 55-year-old woman with asthma presented with a six-month history of chronic cough and intermittent fever. She had received multiple courses of antibiotics, with partial improvement of her symptoms. On examination, she was febrile and had unilateral wheeze along with basal crackles on right side. Her chest radiograph was suggestive of right lower lobe bronchiectasis and partial collapse (Fig.1). On fiberoptic bronchoscopy, a brownish black

Department of  
Pulmonary and  
Critical Care Medicine  
The Aga Khan  
University Hospital  
PO Box 3500  
Stadium Road  
Karachi 74800  
Pakistan

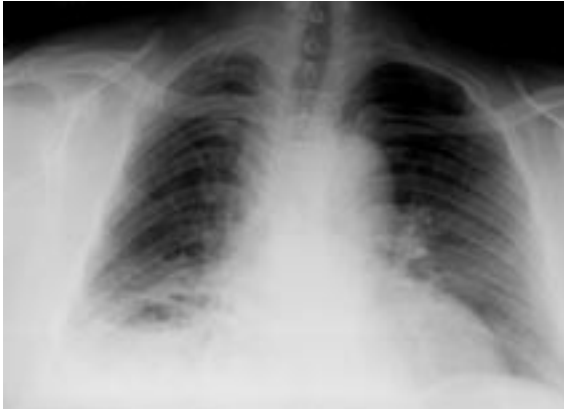Zubairi A B, MD, FCCP  
Assistant Professor

Haque A S, MBBS,  
MRCP  
Assistant Professor

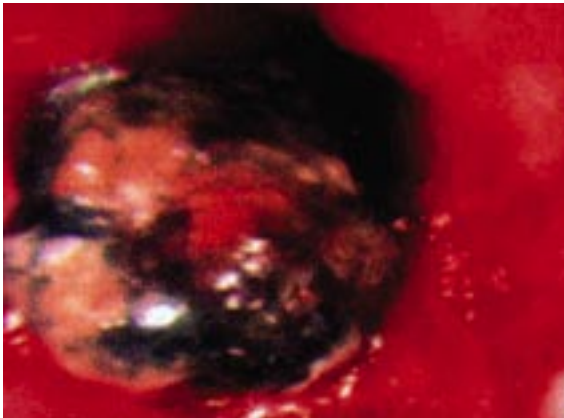
Husain S J, MD, FCCP  
Assistant Professor

Khan J A, MBBS, FRCPE  
Professor

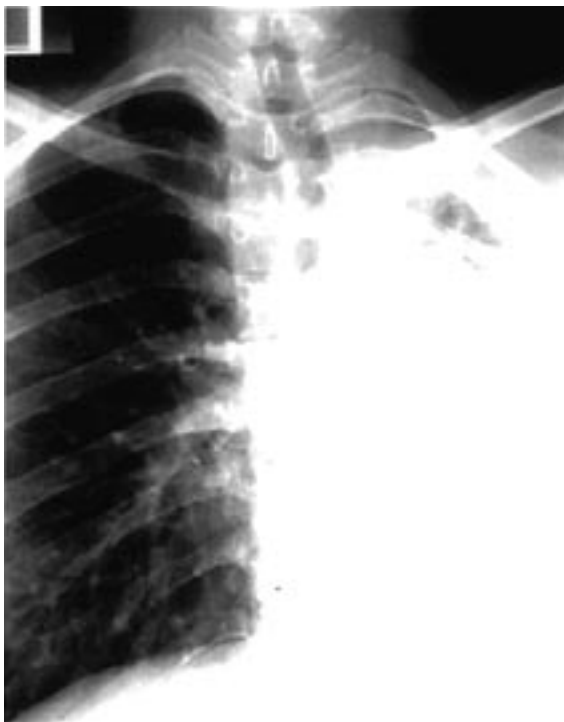**Correspondence to:**  
Dr Ali Bin Sarwar Zubairi  
Tel: (92) 21 4859 4682/5  
Fax: (92) 21 493 4294  
Email: ali.zubairi@  
aku.edu



**Fig. 1** Chest radiograph shows right lower lobe bronchiectasis and partial collapse.



**Fig. 2** Brochoscopic photograph shows a black endobronchial mass-like lesion (vegetable material) impacted in right lower lobe bronchus.



**Fig. 3** Chest radiograph shows extensive left-sided fibrosis.

endobronchial mass was seen in right lower lobe bronchus (Fig. 2). An endobronchial biopsy was done which revealed vegetable matter. She subsequently underwent a rigid bronchoscopy and removal of the foreign body from the right lower lobe bronchus. The foreign body was confirmed to be a tamarind seed. She recovered from her pneumonia. However, she had significant residual bronchiectasis.

#### Case Four

A 19-year-old man from northern Pakistan was referred with a two-year history of productive cough and intermittent fever. During this period, he had received multiple antibiotics and two courses of anti-tuberculous therapy without any benefit. His chest radiograph showed extensive left-sided fibrosis along with cavitations (Fig. 3). Sputum smears were negative for acid-fast bacilli (AFB). On flexible bronchoscopy, the plastic feed of a fountain pen lodged in left lower lobe bronchus was identified (Fig. 4). On close questioning, the patient recalled an event three years ago, where he had intractable cough that lasted two weeks after inhaling “part of a fountain pen”. A surgical consult was sought and the patient underwent a partial lingular and a complete left lower lobe resection due to extensive bronchiectasis. He recovered completely without any significant residual complaints.

#### DISCUSSION

Our four cases of foreign body aspiration, two with betel nuts, one with tamarind seed and one with plastic feed of a fountain pen, demonstrate the potential considerable morbidity associated with this condition. Three of our patients presented many months after the inhalation episode, and one did not even remember the initial episode. The diagnosis was missed previously in all cases, and in one case, two courses of anti-tuberculous therapy were given



**Fig. 4** Photograph shows the plastic feed of a fountain pen.

based on clinical and radiological suspicion. The high rate of initial alternate diagnosis and the empirical treatment of common conditions is not infrequently seen in cases of foreign body aspiration. Our cases highlight the potential diagnostic challenge posed by this condition, and illustrate the importance of obtaining a good history and maintaining a high index of clinical suspicion to arrive at the correct diagnosis.

Tracheobronchial obstruction by a foreign body was first described as a cause of wheezing by Struthers in 1852<sup>(5)</sup>. In adults, the most commonly aspirated material are food particles. Significant neurological impairment, alcohol and drug intoxication and poor dentition are identified risk factors for such events in adults. However, as seen in our series, foreign body aspiration can occur, even in the absence of identifiable risk factors. Foreign bodies that are able to pass through the vocal cords often lodge at the carina and right main stem bronchus<sup>(5)</sup>.

In many Asian countries, including Taiwan, India and Pakistan, betel nut (Areca nut) is chewed by itself and in various scented preparations<sup>(6,7)</sup>. It is also consumed in the form of betel quid, which consists of betel leaf, areca nut, sweetener, slaked lime, condiments, and sometimes, tobacco. Betel nut inhalation is common in South East Asia. In a series of 52 Pakistani children with foreign body aspiration, 29 cases were due to betel nuts<sup>(8)</sup>. The manner in which nuts are introduced into the mouth places the user at high risk of aspiration. The nut mixture, which usually consist of many small particles, is first spread onto the palm, following which a sharp flicking movement of the arm and wrist, with the neck partially extended and an accompanying inspiratory effort, causes the nuts to be tossed into the oral cavity at a high velocity. The net effect of these actions is that particles of varying sizes are predisposed to enter the airways.

Nut aspiration is recognised as a public health issue in some parts of the world. A study on Pakistani school-aged children found that 74% of the children were using areca nut. The reasons for this widespread use were aggressive marketing, easy availability, and a lack of school education among parents<sup>(8)</sup>. In another study from Turkey, hazelnut aspiration was responsible for 26% of all foreign bodies aspirations, and the peak correlated with hazelnut harvest season<sup>(9)</sup>. To our knowledge, there has been no case report of tamarind seed aspiration. Tamarind seed is part of the tamarind fruit, which is a paste-like fruit and is usually chewed. The seed itself is extremely smooth and slippery and thereby increases the likelihood of aspiration.

Regional differences exist in the kind of foreign bodies aspirated worldwide. In a study from China,

bony fragments were the most common foreign body aspirated in adults<sup>(10)</sup>. A possible explanation may be that Chinese eat viand (meat and bone) with rice using chopsticks, which requires a suction, usually generated by an inspiratory effort, as a consequence of which risk of aspiration is increased. Limper and Prakash reported that food particles were the most common foreign body aspirated in their series of North American cohorts<sup>(11)</sup>. Consistent with previous series, our patients also presented late, with the presence of symptoms for many months in three of our patients. Lan found that only six out of 46 patients had presentation within one week of aspiration<sup>(12)</sup>. This delay not uncommonly occurs because the episode of aspiration is either asymptomatic or causes minimal symptoms. In adults, a probable reason for lack of acute symptoms may be the larger calibre of airways resulting in most foreign bodies lodging and obstructing more distal airways<sup>(13)</sup>. Because of the delayed presentation, all of our patients had an abnormal chest radiograph and associated complications such as localised bronchiectasis, lung fibrosis and recurrent pneumonia. The initial diagnosis and localisation of the foreign bodies in all our cases was confirmed by flexible bronchoscopy. Studies have reported high success rates with flexible bronchoscopy for the removal of foreign objects<sup>(14,15)</sup>. However, in our series, three patients required rigid bronchoscopy to remove the foreign body and in one patient, thoracotomy and lobar resection were done. This was due to the consistency and the size of the aspirated material. The betel nuts and tamarind seeds are of a large size and are slippery, thus preventing the forceps or the basket from capture and removal of the object.

In conclusion, foreign body aspiration can occur in adults in certain ethnic/ subgroups of South Asian population, in the absence of any predisposing factors. A delay in presentation or recognition may lead to serious complications, emphasising the importance of early diagnosis in this potentially dangerous but completely reversible condition. Foreign body aspiration should always be considered in the aetiology of recurrent pulmonary infections, haemoptysis, lung abscess, middle lobe syndrome, and bronchiectasis, all of which may necessitate a surgical resection.

#### ACKNOWLEDGEMENT

We are thankful to Saulat Fatimi, MD, Assistant Professor of Cardiothoracic Surgery at the Aga Khan University, for providing assistance in the management of our cases

## REFERENCES

1. al Majed SA, Ashour M, al-Moberireek AF, et al. Overlooked inhaled foreign bodies: late sequelae and the likelihood of recovery. *Resp Med* 1997; 91:293-6.
2. Irwin RS, Ashba JK, Braman SS, Lee HY, Corrao WM. Food asphyxiation in hospitalized patients. *JAMA* 1997; 277:2744-5.
3. Rahulan V, Patel M, Sy E, Menon L. Foreign body aspiration in elderly: an occult cause of chronic pulmonary symptoms and persistent infiltrates. *Clin Geriatr* 2003; 11:41-3.
4. Baharloo F, Veyckemans F, Francis C, Biettlot MP, Rodenstein DO. Tracheobronchial foreign bodies: presentation and management in children and adults. *Chest* 1999; 115:1357-62.
5. Lin YS, Chu NF, Wu DM, Shen MH. Prevalence and factors associated with the consumption of betel-nut among military conscripts in Taiwan. *Eur J Epidemiol* 2004; 19:343-51.
6. Wang SC, Tsai CC, Huang ST, Hong YJ. Betel nut chewing: the prevalence and the intergenerational effect of parental behavior on adolescent students. *J Adolesc Health* 2004; 34:244-9.
7. Samad L, Ali M, Ramzi H. Tracheobronchial foreign bodies in children: reaching a diagnosis. *J Pak Med Assoc* 1998; 48:332-4.
8. Shah SM, Merchant AT, Luby SP, Chotani RA. Addicted school children: prevalence and characteristics of areca nut chewers among primary school children in Karachi, Pakistan. *J Paediatr Child Health* 2002; 38:507-10.
9. Tander B, Kirdar B, Ariturk E, Rizalar R, Bernay F. Why nut? The aspiration of hazelnuts has become a public health problem among small children in the central and eastern Black Sea regions of Turkey. *Pediatr Surg Int* 2004; 20:502-4.
10. Chen CH, Lai CL, Tsai TT, Lee YC, Perng RP. Foreign body aspiration into the lower airway in Chinese adults. *Chest* 1997; 112:129-33.
11. Limper AH, Prakash UBS. Tracheobronchial foreign bodies in adults. *Ann Intern Med* 1990; 112:604-9.
12. Lan RS. Non-asphyxiating tracheobronchial foreign bodies in adults. *Eur Resp J* 1994; 7:510-4.
13. Mu L, He P, Sun D. Inhalation of foreign bodies in Chinese children: a review of 400 children. *Laryngoscope* 1991; 101:657-60.
14. Karen LS, Prakash UBS, Midthun DE, et al. Flexible bronchoscopic management of airway foreign bodies in children. *Chest* 2002; 121:1695-700.
15. Rafanan AL, Mehta AC. Adult airway foreign body removal. What's new? *Clin Chest Med* 2001; 22:319-30.