

Posterior fracture-dislocation of the humeral head treated without the use of metallic implants

Tey I K, Tan A H C

ABSTRACT

Posterior fracture-dislocation of the humeral head is an uncommon injury, usually associated with seizures, electrocution injury and high-impact trauma. Prompt diagnosis and treatment are important to prevent avascular necrosis of the humeral head. Various methods to treat such injury have been described. We report a 34-year-old man who had a four-part humeral head fracture with concomitant posterior dislocation that was treated with open reduction and internal fixation with non-absorbable polyester sutures. The diagnosis and operative techniques are described and factors influencing our choice of management are discussed. A review of the literature is also included.

Keywords: avascular necrosis, fracture treatment, humeral head fracture, non-absorbable polyester sutures, posterior dislocation

Singapore Med J 2007;48(3):e114–e118

INTRODUCTION

Posterior fracture-dislocation of the humeral head is an uncommon injury, usually associated with seizures, electrocution injury and high-impact trauma. Prompt diagnosis and treatment are important to prevent avascular necrosis of the humeral head. Various methods to treat such injury have been described. We report a case of a four-part humeral head fracture with concomitant posterior dislocation treated with open reduction and internal fixation with non-absorbable polyester sutures.

CASE REPORT

A 34-year-old, left-hand dominant man was seen in the emergency department (ED) after sustaining a high-impact fall while jogging. He had used both upper limbs to break his fall, and subsequently reported severe pain in his right shoulder and left forearm. Apart from this, he sustained no other injuries. On examination, his left forearm and right shoulder were exquisitely tender, and

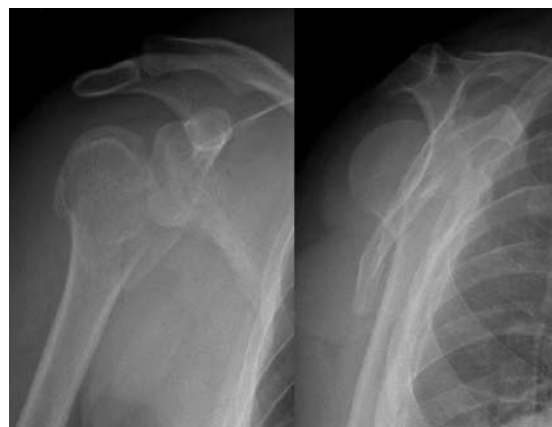

Fig. 1 (a) Anteroposterior and (b) Y-scapular view radiographs of the right shoulder show a comminuted fracture of the humeral head and a concomitant posterior dislocation.

no range of motion was possible. There were no associated neurovascular injuries. Radiographs done in ED showed a closed comminuted right humeral head fracture with concomitant posterior dislocation of the humeral head, and closed displaced fractures of the left distal radius and ulna (Fig. 1).

The distal left radius and ulna fractures were promptly treated with open reduction and internal fixation. Meanwhile, his right upper limb was immobilised with an arm sling. Computed tomography (CT) of the right shoulder showed a four-part humeral head fracture-dislocation (Fig. 2). He subsequently underwent open reduction and internal fixation of his right humeral head fracture-dislocation. Intraoperatively, the fractured humeral head was noted to be devoid of any soft tissue attachment. There was also internal rotation contracture on examination under anaesthesia.

The approach used was the deltopectoral approach with the strap muscles retracted medially and the fracture site adequately exposed. Biceps tenotomy was done, and the greater and lesser tuberosity fragments were secured with non-absorbable polyester sutures and retracted to expose a posteriorly-dislocated humeral head. This was delivered into the joint using bone lever and anteriorly-directed pressure from the back of the shoulder. The humeral head was then reduced, and secured to the greater tuberosity and the surgical neck

Sports Medicine Service,
Department of Orthopaedic Surgery,
Singapore General Hospital,
Outram Road,
Singapore 169608

Tey IK, MBBS
Medical Officer

Tan Andrew, MBBS,
FRCSG, FRCSE
Consultant

Correspondence to:
Dr Tey Inn Kuang
Tel: (65) 9178 2341
Fax: (65) 6226 2684
Email: innkuang@hotmail.com

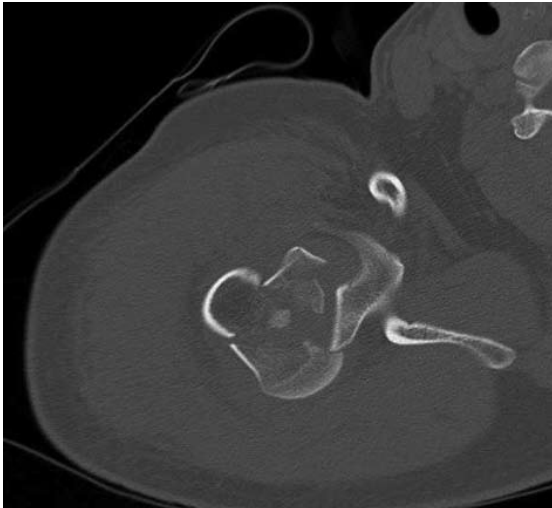

Fig. 2 CT image shows a four-part humeral head fracture-dislocation.

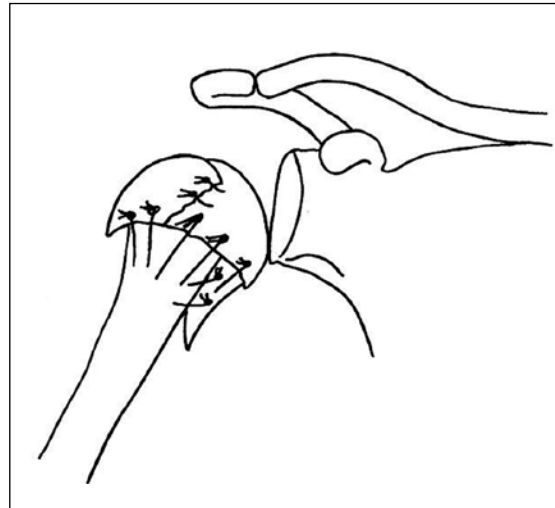


Fig. 3 Schematic diagram shows the placement of the sutures in the various fracture fragments.

with non-absorbable polyester sutures (Figs. 3 & 4). This was done with the medial surgical neck seated into the medial portion of the humeral head for stability. The lesser tuberosity fragment was then reduced and secured with similar polyester sutures. Finally, biceps tenodesis was done to the bicipital groove. When examined again at the end of operation, there was no internal rotation contraction and the range of motion was full and stable.

Postoperatively, the patient was commenced on a shoulder rehabilitation programme, starting with muscle strengthening and pendular motion exercises for one month. He was subsequently allowed to abduct his shoulder from 0° to 90° from one-month post-surgery onwards, and finally progressed to full range of motion at three months post-surgery. The patient achieved good range of motion at 15 months post-surgery (Fig. 5). Forward flexion was 170°, external rotation 80° and internal rotation was up to the level of the tenth thoracic vertebra. He had no complaint of right shoulder pain and had since returned to his job as an engineer.

DISCUSSION

Fracture-dislocation of the humeral head is a rare but severely-disabling injury.⁽¹⁻⁴⁾ The diagnosis is frequently delayed or missed, in view of its rarity and paucity of tell-tale physical signs and failure to make adequate radiographs.^(1,3,5,6) One should raise the suspicion of a fracture-dislocation when a patient reports shoulder pain and inability to move his shoulder following either an epileptic seizure⁽⁷⁾ or an electrocution injury to the arm,⁽⁸⁾ or following axial loading on an adducted, internally rotated arm. Physical signs may be subtle and easily missed, if not actively sought. They include internal rotation contracture with the

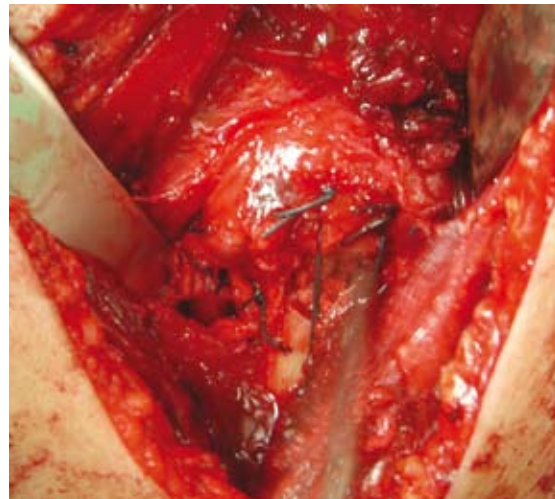


Fig. 4 Operative photograph shows the fracture fragments of the humeral head reduced and sutured together using non-absorbable polyester sutures.

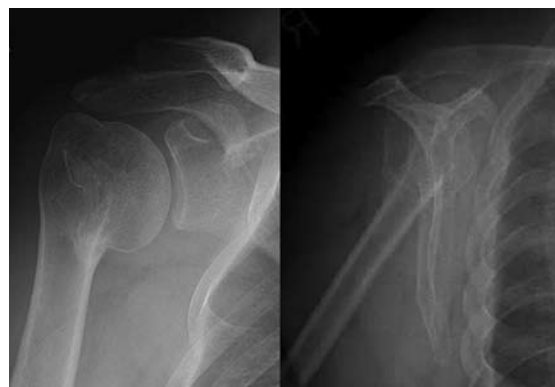

Fig. 5 Repeat (a) anteroposterior and (b) Y-scapular view radiographs taken 15 months postoperation show union of the humeral head fracture. Range of motion was good with forward flexion 170°, external rotation 80° and internal rotation up to the tenth thoracic vertebra level.

shoulder having zero degree of external rotation. This occurs because the posteriorly-dislocated humeral head gets locked behind the glenoid. Other signs which may be present include a prominent coracoid process, flattening of the anterior aspect of the shoulder, and prominence over the back of the shoulder. In patients suspected of having fracture-dislocation of the shoulder, it is mandatory to perform adequate radiographs, namely anteroposterior, Y-scapular and axillary views. In our patient, the anteroposterior radiographs clearly showed a four-part humeral head fracture. CT may be performed to better delineate the anatomy of the fracture dislocation and enable the planning of surgery.

Prompt diagnosis and treatment of the fracture is of paramount importance in preventing avascular necrosis and subsequent collapse of the humeral head. The evaluation of the risk of post-traumatic avascular necrosis of the humeral head requires knowledge of its blood supply. Cadaveric studies on the vascularity of the humeral head^(9,10) have shown that the main arterial supply to the humeral head was via the ascending branch of the anterior circumflex humeral artery and its intraosseous continuation, the arcuate artery (Fig. 6). There are significant intraosseous anastomoses between the arcuate artery and the posterior circumflex humeral artery through vessels entering the posteromedial aspect of the proximal humerus, the metaphyseal vessels and the vessels of the greater and lesser tuberosities. Simulated four-part fractures prevented the perfusion of the humeral head in most cases. If, however, the head fragment extends distally below the articular surface medially, some perfusion of the head by the posteromedial vessels may persist. These vessels are important in the management of comminuted fractures of the humeral head.

Due to the rarity of posterior fracture-dislocation of the humeral head, comparative studies on the efficacy of different treatment methods are lacking. Most publications consist of level IV (case series) and level V (expert opinion) studies, compiled retrospectively over many years.⁽¹¹⁾ A wide variety of methods have been described to treat humeral head fracture-dislocation. They range from non-operative treatment⁽¹²⁾ to operative methods which include open reduction and internal fixation and hemiarthroplasty.⁽¹³⁾ Different types of implant such as screws,⁽¹⁴⁾ locking plates,⁽¹⁵⁾ intramedullary interlocking nails,⁽¹⁶⁾ external fixators,⁽¹⁷⁾ tension band wires,⁽¹⁸⁾ Kirschner wires⁽¹⁹⁾ and non-absorbable sutures⁽²⁰⁾ have been reported to be used for the purpose of fixation, each with varying degrees of successful outcome. Selection of the most appropriate treatment option is complex and multifactorial. Due to the rarity of the injury, evidence-

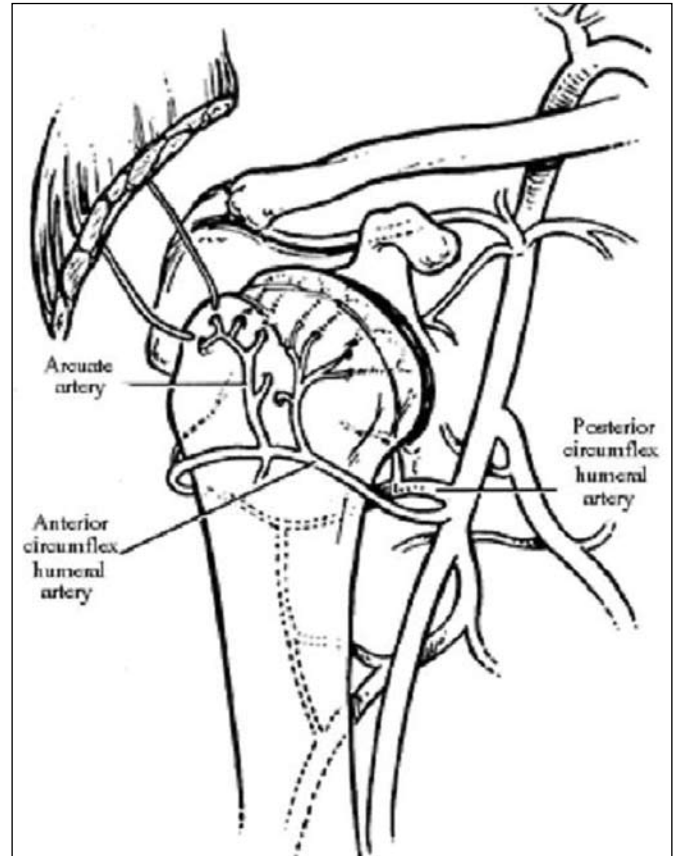


Fig. 6 Diagram shows the blood supply of the humeral head.

based treatment protocols are difficult to devise. Hence, treatment needs to be individualised according to the demographics of the patient.

Deciding on the optimal choice of management requires taking various factors into consideration, i.e. age, occupation, medical status and lifestyle of the patient, degree of devascularisation, and fragmentation of the humeral head and bone quality. In our patient, non-operative management is unacceptable, given the patient's relatively young age, occupation and active lifestyle, as the unreduced fracture of the humeral head predisposes him to the certainty of post-traumatic osteoarthritis. On the other hand, shoulder hemiarthroplasty deserves consideration, given the comminution of the four-part fracture, which translates to a high risk of avascular necrosis. Pavelka stated that early intervention definitely improved the outcome, but still nearly 50% of cases of femoral head avascular necrosis necessitate arthroplasty.⁽²¹⁾ However, the patient's age is once again a relative contraindication to this choice of management, because he is most likely to outlive and outlast the longevity of his prosthesis, requiring further revision surgery later in his lifetime.

Our last option is open reduction and internal fixation. According to Naranja and Iannotti, patients with

four-part fractures and valgus impaction of the head fragment should be treated with limited open reduction and minimal internal fixation, as the blood supply to the humeral head is better preserved than with other fracture patterns and the potential for avascular necrosis is less.⁽²²⁾ In the case of displaced three- and four-part fractures, the physiological age and bone quality also help guide treatment selection. In young patients with good bone quality, attempts to preserve the humeral head by meticulous handling of soft tissues and the use of low-profile implants to secure fracture fragments is recommended.^(23,24) Elderly patients and those with poor bone quality have a greater risk of loss of reduction after open reduction and internal fixation, and the current consensus is that early hemiarthroplasty is the appropriate treatment.

In our patient, given his young age, lifestyle, good bone quality and pattern of fracture, open reduction and internal fixation became our treatment of choice. We opted for fixation using sutures, because we believe that obviating the placement of hardware into the glenohumeral joint would give a better outcome in terms of its post-surgery range of motion.⁽²⁵⁾ Suture fixation also avoids the need for a second operation to remove the hardware after fracture healing has occurred. Fixation using non-absorbable sutures have been described in two- and three-part but not in a four-part humeral head fracture.⁽²⁰⁾ By impacting the surgical neck of the humerus to the medial portion of the humeral head, added stability was achieved, which was further enhanced by suture fixation. This suture fixation technique was sufficient to provide stability, allow healing and good range of motion postoperatively.

During surgery, we thought that it was critical to achieve anatomical reduction of the fracture fragments to achieve a stable construct. However, accurate assessment of the vascular supply of the fragments was not part of our consideration, because it was difficult to ascertain precisely the vascularity of each fragment, and this was especially so when they were devoid of any soft tissue attachment. Hence, fixability of the fragments was not influenced by the vascular supply of the individual fragments. We believe that although the fracture fragments may have been devascularised, revascularisation subsequently occurred by creeping substitution. Published case reports^(26,27) of posterior fracture-dislocation of the humeral head after open reduction and internal fixation with long-term follow-up of more than ten years generally showed good outcome.

At one year post-surgery, our patient did not report any pain or showed any radiographical signs of avascular necrosis. He also had fairly satisfactory range of motion that allowed him to return to work.

Kofoed reported two cases of fracture-dislocation of the shoulder that were followed up radiologically and by technetium-99m scintigraphy for at least two years.⁽²⁸⁾ Lee and Hansen also reported 19 patients with displaced four-part fracture or fracture-dislocation of the proximal humerus during a retrospective study to investigate the incidence of avascular necrosis.⁽²⁹⁾ Both authors recommended early open reduction and internal fixation, rather than conservative treatment or hemiarthroplasty as the treatment of choice for humeral head fracture-dislocation. Both also concluded that the majority of the humeral heads in this injury develop avascular necrosis, but most underwent revascularisation by creeping substitution.

It remains to be seen if our patient will further develop avascular necrosis of the humeral head as it could still set in years later. Further follow-up of the patient is necessary to monitor the possible development of such complication. Suture fixation without the use of metallic implants has, however, successfully stabilised the fracture, allowing it to heal uneventfully with good postoperative range of motion and function achieved in our patient.

REFERENCES

- McLaughlin HL. Posterior dislocation of the shoulder. *J Bone Joint Surg Am* 1952; 24A:584-90.
- Mestdagh H, Maynou C, Delobelle JM, Urvoy P, Butin E. [Traumatic posterior dislocation of the shoulder in adults. Apropos of 25 cases] *Ann Chir* 1994; 48:355-63. French.
- Rowe CR, Zarins B. Chronic unreduced dislocations of the shoulder. *J Bone Joint Surg Am* 1982; 64:494-505.
- Schulz TJ, Jacobs B, Patterson RL Jr. Unrecognized dislocations of the shoulder. *J Trauma* 1969; 9:1009-23.
- Dorgan JA. Posterior dislocation of the shoulder. *Am J Surg* 1955; 89:890-900.
- Matsen FA III, Thomas SC, Rockwood CA Jr, Wirth MA. Glenohumeral instability. In: Rockwood CA Jr, Matsen FA III, eds. *The Shoulder*. 2nd ed. Philadelphia: Saunders, 1998: 611-754.
- Ahlgren O, Lorentzon R, Larsson SE. Posterior dislocation of the shoulder associated with general seizures. *Acta Orthop Scand* 1981; 52:694-5.
- Carew-McColl M. Bilateral shoulder dislocations caused by electrical shock. *Br J Clin Prac* 1980; 34:251-4.
- Gerber C, Schneeberger AG, Vinh TS. The arterial vascularization of the humeral head. An anatomical study. *J Bone Joint Surg Am* 1990; 72:1486-94.
- Brooks CH, Revell WJ, Heatley FW. Vascularity of the humeral head after proximal humeral fractures. An anatomical cadaver study. *J Bone Joint Surg Br* 1993; 75:132-6.
- Robinson CM, Aderinto J. Posterior shoulder dislocations and fracture-dislocations. *J Bone Joint Surg Am* 2005; 87:639-50.
- Leyshon RL. Closed treatment of fractures of the proximal humerus. *Acta Orthop Scand* 1984; 55:48-51.
- Qian QR, Wu HS, Zhou WJ, Li XH, Wu YL. Proximal humeral fractures treated with arthroplasty. *Chin J Traumatol* 2005; 8:283-8.
- Schweighofer F, Schippinger G, Peicha G. [Posterior dislocation fracture of the shoulder] *Chirurg* 1996; 67:1251-4. German.
- Plecko M, Kraus A. Internal fixation of proximal humerus fractures using the locking proximal humerus plate. *Oper Orthop Traumatol* 2005; 17:25-50.
- Adedapo AO, Ikpeme JO. The results of internal fixation of three- and four-part proximal humeral fractures with the Polarus nail. *Injury* 2001; 32:115-21.

17. Altay T, Karapinar L, Kaya A, Ozturk H. [Treatment of two-part proximal humeral fractures with external fixators] *Ulus Travma Acil Cerrahi Derg* 2005; 11:153-6. Turkish.
18. Banco SP, Andrisani D, Ramsey M, Frieman B, Fenlin JM Jr. The parachute technique: valgus impaction osteotomy for two-part fractures of the surgical neck of the humerus. *J Bone Joint Surg Am* 2001; 83A suppl 2:38-42.
19. Sharma L, Pankaj A, Kumar V, Malhotra R, Bhan S. Bilateral anterior dislocation of the shoulders with proximal humeral fractures: a case report. *J Orthop Surg (Hong Kong)* 2005; 13:303-6.
20. Park MC, Murthi AM, Roth NS, et al. Two-part and three-part fractures of the proximal humerus treated with suture fixation. *J Orthop Trauma* 2003; 17:319-25.
21. Pavelka K. Osteonecrosis. *Baillieres Best Pract Res Clin Rheumatol* 2000; 14:399-414.
22. Naranja RJ Jr, Iannotti JP. Displaced three- and four-part proximal humerus fractures: evaluation and management. *J Am Acad Orthop Surg* 2000; 8:373-82.
23. DeFranco MJ, Brems JJ, Williams GR Jr, Iannotti JP. Evaluation and management of valgus impacted four-part proximal humerus fractures. *Clin Orthop Relat Res* 2006; 442:109-14.
24. Wiggman AJ, Roolker W, Patt TW, Raaymakers EL, Marti RK. Open reduction and internal fixation of three and four-part fractures of the proximal part of the humerus. *J Bone Joint Surg Am* 2002; 84A:1919-25.
25. Zyto K, Kronberg M, Brostrom LA. Shoulder function after displaced fractures of the proximal humerus. *J Shoulder Elbow Surg* 1995; 4:331-6.
26. Kaar TK, Wirth MA, Rockwood CA Jr. Missed posterior fracture-dislocation of the humeral head. A case report with a fifteen-year follow-up after delayed open reduction and internal fixation. *J Bone Joint Surg Am* 1999; 81:708-10. Comment in: *J Bone Joint Surg Am* 2000; 82:1364-5.
27. Ide J, Honda K, Takagi K. Posterior dislocation of the shoulder associated with fracture of the humeral anatomical neck with 11-year follow-up after early open reduction and internal fixation. *Arch Orthop Trauma Surg* 2003; 123:118-20.
28. Kofoed H. Revascularization of the humeral head. A report of two cases of fracture-dislocation of the shoulder. *Clin Orthop Relat Res* 1983; 179:175-8.
29. Lee CK, Hansen HR. Post-traumatic avascular necrosis of the humeral head in displaced proximal humeral fractures. *J Trauma* 1981; 21:788-91.