

# Uncommon locations of hydatid cysts

Kouskos E, Chatziantoniou J, Chrissafis I, Anitsakis C, Zamtrakis S

## ABSTRACT

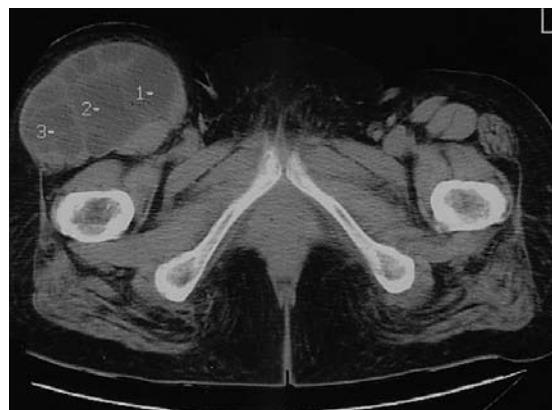Human echinococcosis remains a complex problem that may affect several organs, and requires mostly surgical management. We present two cases with uncommon locations of hydatid cysts that were successfully managed in our hospital during the last two years. The first case was a 62-year-old woman with a multicystic lesion in her right thigh that was radically excised, and histology confirmed the diagnosis of echinococcosis. The second case was a 78-year-old man with multiple large intraabdominal hydatid cysts that required a complex operation, including splenectomy, partial removal of the liver cyst wall and evacuation of the content, and excision of pelvic, mesenteric cysts, and suprahepatic cysts. Both cases have not shown any sign of recurrence to date. Since the disease is still endemic in certain parts of the world and pharmaceutical agents are not radical, specific surgical procedures remain the treatment of choice with good results and acceptable morbidity, mortality and recurrence rates.

**Keywords:** abdominal echinococcosis, echinococcus, hydatid cysts, immunoelectrophoresis, thigh echinococcosis

Singapore Med J 2007;48(4):e119–e121

## INTRODUCTION

Human echinococcosis is a parasitic disease known since the ancient times; Hippocrates first described it as being located in the liver, and introduced methods of treatment. The disease is still endemic in many countries, such as Greece, other parts of Eastern Europe, South America, Australia and South Africa. It is caused by the tapeworm *Echinococcus* with *E. granulosus* being the most common form and the most frequent aetiological agent, although occasionally *E. multilocularis* is the infective agent.<sup>(1-4)</sup> In this report, we present two cases with uncommon location of hydatid disease that were successfully managed in our hospital during the last two years.



**Fig. 1** Case 1. Axial CT image shows a large multicystic hydatid lesion in the anterior right thigh.

## CASE REPORTS

### Case 1

A 62-year-old Caucasian woman, a permanent resident of our city without any history of travelling abroad and occupied with housekeeping, presented with a mass in her right thigh since 1995. There was a progressive increase in the size of the mass during the last years, and it had been painful for the last three months. Serological test (counter immunoelectrophoresis test [CIE]) was diagnostic for echinococcosis, while computed tomography (CT) revealed multiple cysts in the anterior part of her thigh between the muscle and subcutaneous fat (Fig. 1). The patient underwent a radical excision of that multicystic mass, and histology confirmed the diagnosis of echinococcosis. The patient had an uncomplicated postoperative period; she received three monthly cycles of albendazole (Zentel, SmithKline Beecham, Athens, Greece) 400 mg twice a day. To date, she has not presented any sign, neither clinical or imaging, of recurrence.

### Case 2

A 78-year-old Caucasian man, who is a resident in a village of our island, has no history of travelling abroad and works as a animal herder, presented with dysuria for a period of three weeks. He had abdominal ultrasonography (US) that revealed multiple intra-abdominal cysts. CIE was abnormal, indicative of hydatid disease. CT showed multiple large hydatid

Second Surgical Department,  
Vostanio General Hospital,  
48 E Vostanis Street,  
Mytilene 81100,  
Lesvos Island,  
Greece

Kouskos E, MD  
Consultant

Zamtrakis S, MD  
Consultant and Head

Department of  
Orthopaedics

Chatziantoniou J  
Consultant

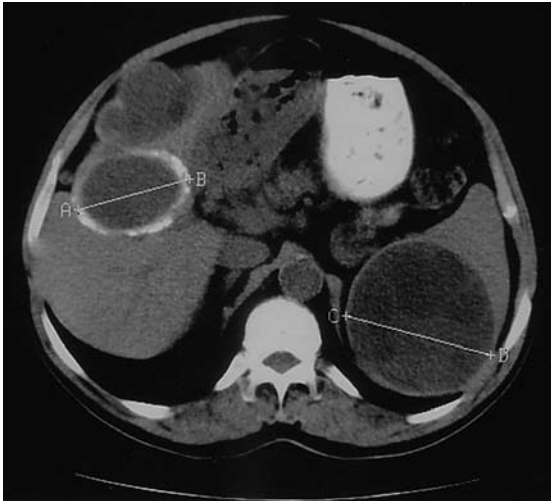
Radiology  
Department

Chrissafis I  
Consultant

Second Department  
of Internal Medicine

Anitsakis C  
Consultant

**Correspondence to:**  
Dr Efstratios P  
Kouskos  
Tel: (3) 22510 37585  
Fax: (3) 22510 28829  
Email: skouskos@  
hotmail.com;  
ekouskos@tpp24.gr



**Fig. 2** Case 2. Axial CT image shows a large splenic hydatid cyst, a calcified liver cyst and a third cyst between the diaphragm and the liver.

cysts, most of them with daughter cysts and hydatid sand. The cysts were located between the diaphragm and liver (two cysts, with sizes of 5 cm and 7 cm), within the liver (two cysts: the first in the right lobe, 7 cm in size, with focal wall calcifications; and the second, close to the liver hilum, 6 cm in size), spleen (one measuring 11 cm), pelvis, and fixed to the small bowel mesentery (Fig. 2). The patient had a preoperative treatment with three monthly cycles of albendazole (Zentel, SmithKline Beecham, Athens, Greece) 400 mg twice a day, in order to improve the surgical results, and to reduce the risk of disease recurrence.

The patient then underwent a complex operation. Splenectomy and excision of the pelvic cysts were performed. The sigmoid colon was firmly attached to one of the pelvic cysts. The excision of the cyst was very laborious, and the blood supply of the sigmoid colon was damaged, requiring a prophylactic left-sided loop colostomy. Excision of the cysts fixed to small bowel mesentery, and partial removal of the wall of both liver cysts, evacuation of their contents, and excision of the inner cyst layer were performed. Drain tubes were placed inside the cysts. The bigger one had developed bile leakage after the excision of the inner layer. In order to have the biliary tree decompressed, a no. 18 size Foley catheter was placed in the gallbladder. The suprahepatic cysts with a part of the transverse colon, which was invaded by the cyst wall inflammation, was removed. The transverse colon continuity was achieved by a one-layer anastomosis with 3-0 Vicryl suture. Excision of the omentum, due to its fixation on the multiple cysts, was also performed.

The patient developed cholangitis on the sixth postoperative day. Endoscopic retrograde

cholangiopancreatography (ERCP) revealed a daughter cyst in the common bile duct, and it was successfully removed by sphincterotomy. The patient had the Foley catheter removed from the gallbladder two weeks later, following a normal cholangiography. He again received three monthly cycles of albendazole 400 mg twice a day. He had his loop colostomy closed four months later, and on follow-up, his clinical examination, laboratory tests and CT do not show any echinococcosis recurrence to date.

## DISCUSSION

Even though simple liver cysts are the most common cystic lesions of the liver worldwide, echinococcosis remains a frequent cause of liver cysts in endemic areas. More than 90% of hydatid cysts occur in the liver, lungs, or both. Symptomatic cysts have been reported occasionally in the spleen, kidney, peritoneal cavity, skin and muscles (incidence of 2% each), and rarely in the heart, brain, vertebral column, ovaries, pancreas, gallbladder, thyroid gland, breast, and bones (incidence of 1% or less each).<sup>(3)</sup> The diagnosis of uncomplicated hydatid cyst of the liver depends on clinical suspicion. Symptomatic cysts are usually larger than 5 cm; mild abdominal pain in the epigastrium or right upper quadrant, hepatomegaly or a palpable abdominal mass are quite common symptoms.<sup>(1,2)</sup> Rupture of the cyst into the biliary tree will cause biliary colic and jaundice,<sup>(5)</sup> while rupture into the peritoneal cavity may cause urticaria, anaphylactic shock or implantation of the cysts into other viscera.<sup>(6)</sup> Hydatid cysts of the spleen present with pain or even a palpable mass in the upper left abdomen, while those of other organs could demonstrate various organ-specific and systematic manifestations.<sup>(3,7)</sup> Our first patient presented with a painful mass in her right thigh, while the second one was asymptomatic.

Diagnosis is established by imaging and specific serological tests, such as the indirect haemagglutination test, the enzyme-linked immunosorbent assay that yields a positive result in more than 90% of the patients, the radioallergosorbent test, the complement fixation test, and the CIE, with the latter being used for both our cases with excellent results.<sup>(1,3)</sup> US, CT, and magnetic resonance imaging have an almost 100% specificity and sensitivity, and could reveal the morphological characteristics of the cyst, its exact position in relationship with the surrounding tissues, the number of concomitant cysts, and also help to differentiate hydatid cysts from other lesions such as abscesses or tumours, especially when daughter cyst(s) or hydatid sand are found.<sup>(8)</sup> CT was used in both our cases with excellent diagnostic results. ERCP may demonstrate possible communications of the cyst with

the biliary tree, either preoperatively or intraoperatively. Moreover, ERCP provides therapeutic manoeuvres, such as stent placement, balloon dilatation and sphincterotomy.<sup>(9)</sup> In our second patient who presented with postoperative cholangitis, ERCP proved to be very helpful in the patient's diagnosis and treatment.

Medical treatment with antihelminthic drugs, such as mebendazole and albendazole, has been introduced since 1977 as preoperative or postoperative chemotherapy. Many authors have reported that these agents can achieve clinical improvement of the patients, increased life expectancy, shrinkage of the cysts, sterilisation of the cyst fluid and changes in serological reactions. On the other hand, besides the low concentration of these drugs in the hydatid fluid and the persistence of living parasites within the cysts in almost half of the patients, there are significant side effects, such as haematological abnormalities, hepatotoxicity, nephrotoxicity and teratogenicity, that should not be ignored.<sup>(10,11)</sup> Both our patients received albendazole (the first postoperatively and the second pre- and postoperatively), without any serious side effects.

Surgery still remains the mainstay in the management of hydatid disease. The general principle for surgical treatment is the removal of cyst contents without contaminating the patient, followed by appropriate management of any remaining cavity.<sup>(1)</sup> Packs immersed in hypertonic saline solution, placed in the operative field, are widely used, without serious complications, in order to prevent spillage of scoleces or daughter cysts into the peritoneal cavity during evacuation. The same solution should be irrigated in the empty cyst cavity.<sup>(4)</sup> These principles were applied to both patients.

Concerning the remaining cavity, a few surgical techniques have been used with good results, namely: (a) external drainage of the cyst cavity, used for the liver cysts of the second patient; and (b) evacuation and partial cystectomy followed by omentoplasty.<sup>(1,2,5)</sup> The latter is the most effective method for a conservative approach for liver hydatidosis. In our second patient, omentoplasty could not be performed, because the omentum was fixed on the cysts and was resected. Percutaneous and laparoscopic techniques for the management of hepatic hydatid cysts are not used widely, due to the risk of anaphylaxis and/or dissemination.<sup>(12)</sup>

Intrabiliary rupture with resultant cholangitis is the commonest complication of liver hydatid disease and requires common bile duct exploration with extraction of the hydatid cysts, followed by primary closure and T-tube drainage.<sup>(1,2)</sup> Our second patient presented intraoperatively with bile leaking into one of the liver cysts, and Foley catheter drainage of the gallbladder

was performed in order to have the biliary tree decompressed. We drained the gallbladder instead of the bile duct, because the procedure was much simpler, faster and easier. Unfortunately, the patient later required a common bile exploration by ERCP, because he presented with postoperative cholangitis.

Large splenic hydatid cysts are treated by splenectomy. Small superficial cysts located in one pole of the spleen can be treated by conservative techniques, such as partial splenectomy and unroofing of the cyst with omentoplasty.<sup>(7)</sup> Uncommon locations of hydatid cysts are treated by excision of the cyst alone or en-bloc with a part or the whole organ that is involved, e.g. cholecystectomy in the case of cysts within the gallbladder, and cyst excision for cysts located in the soft tissues, as in our first case.<sup>(13-15)</sup> In conclusion, when surgeons face uncommon locations of hydatid cysts, after the appropriate preoperative evaluation and surgical management, they could achieve a satisfactory clinical outcome with a low morbidity rate and an acceptable recurrence rate.

## REFERENCES

1. Silva MA, Mirza DF, Bramhall SR, et al. Treatment of hydatid disease of the liver. Evaluation of a UK experience. *Dig Surg* 2004; 21:227-34. Comment in: *Dig Surg* 2005; 22:380; author reply 380.
2. Safioleas M, Misiakos E, Kakisis J, et al. Surgical management of human echinococcosis. *Int Surg* 2000; 85:358-65.
3. McManus DP, Zhang W, Li J, Bartley PB. Echinococcosis. *Lancet* 2003; 362:1295-304.
4. Hamamci EO, Besim H, Korkmaz A. Unusual locations of hydatid disease and surgical approach. *ANZ J Surg* 2004; 74:356-60.
5. Yildirman MI, Basoglu M, Atamanalp SS, et al. Intrabiliary rupture in liver hydatid cysts: results of 20 years' experience. *Acta Chir Belg* 2003; 103:621-5.
6. Saenz de San Pedro B, Cazana JL, Cobo J, et al. Anaphylactic shock by rupture of hydatid hepatic cyst. Follow-up by specific IgE serum antibodies. *Allergy* 1992; 47:568-70.
7. Safioleas M, Misiakos E, Manti C. Surgical treatment for splenic hydatidosis. *World J Surg* 1997; 21:374-8. Comment in: *World J Surg* 1998; 22:423.
8. Valle-Sanz Yd Y, Lorente-Ramos RM. Sonographic and computed tomographic demonstration of hydatid cysts communicating with the biliary tree. *J Clin Ultrasound* 2004; 32:144-8.
9. Simsek H, Ozaslan E, Sayek I, et al. Diagnostic and therapeutic ERCP in hepatic hydatid disease. *Gastrointest Endosc* 2003; 58:384-9. Comment in: *Curr Gastroenterol Rep* 2004; 6:272.
10. Chai J, Menghebat, Wei J, et al. Observations on clinical efficacy of albendazole emulsion in 264 cases of hepatic cystic echinococcosis. *Parasitol Int* 2004; 53:3-10.
11. Senyuz OF, Yesildag E, Celayir S. Albendazole therapy in the treatment of hydatid liver disease. *Surg Today* 2001; 31:487-91.
12. Yaghan R, Heis H, Bni-Hani K, et al. Is fear of anaphylactic shock discouraging surgeons from more widely adopting percutaneous and laparoscopic techniques in the treatment of liver hydatid cyst? *Am J Surg* 2004; 187:533-7.
13. Bhattacharya S, Roy CK, Das S, et al. A case of disseminated hydatidosis. *J Indian Med Assoc* 2003; 101:672-4.
14. Kiresi DA, Karabacakoglu A, Odev K, Karakose S. Uncommon locations of hydatid cysts. *Acta Radiol* 2003; 44:622-36.
15. Orhan Z, Kara H, Tuzuner T, Sencan I, Alper M. Primary subcutaneous cyst hydatid disease in proximal thigh: an unusual localisation: a case report. *BMC Musculoskelet Disord* 2003; 4:25.