

Diabetic fibrous mastopathy

Lakshmanan R, Clarke M J, Putti T C

ABSTRACT

Diabetic fibrous mastopathy is reported in a 37-year-old premenopausal woman. A known case of insulin-dependent diabetes mellitus, she presented with bilateral hard breast lumps, which were suggestive of malignancy on both ultrasonography and mammography. Fine-needle aspiration cytology and core biopsy showed fibrosis. An incisional biopsy further excluded malignancy and was conclusive for diabetic fibrous mastopathy.

Keywords: diabetes mellitus, diabetic fibrous mastopathy, fibrous mastopathy, mammography, mastopathy

Singapore Med J 2007;48(6):579-581

INTRODUCTION

Diabetic fibrous mastopathy (DFM) is an uncommon pathology of the breast that presents classically in premenopausal women with insulin-dependent diabetes mellitus (IDDM). The clinical presentation and radiological features closely mimic that of carcinoma of the breast. Awareness of this entity is important in the multidisciplinary team of surgeons, radiologists and pathologists managing the patient with breast disease. Proper diagnosis also helps to alleviate anxiety and unnecessary invasive procedures to exclude malignancy.

CASE REPORT

A 37-year-old woman presented with bilateral breast lumps of three years' duration. She had IDDM for a period of 26 years, complicated by bilateral focal maculopathy. She was referred to us after ultrasonography of the breasts revealed bilateral hypoechoic masses with ill-defined margins in the subareolar region. The masses demonstrated posterior acoustic shadowing (Fig. 1). Measurement of the lesions was 45 mm × 40 mm, and 27 mm × 42 mm, in the right and left breasts, respectively. Mammography showed bilateral dense glandular tissue with no significant features of malignancy (Fig. 2). Clinical examination revealed bilateral hard subareolar masses measuring 4 cm in diameter. An initial fine-needle aspiration cytology (FNAC) performed showed that there was difficulty withdrawing and advancing the needle from the "rock hard" breast mass. The resultant cytology was insufficient to make a diagnosis. Core biopsy of

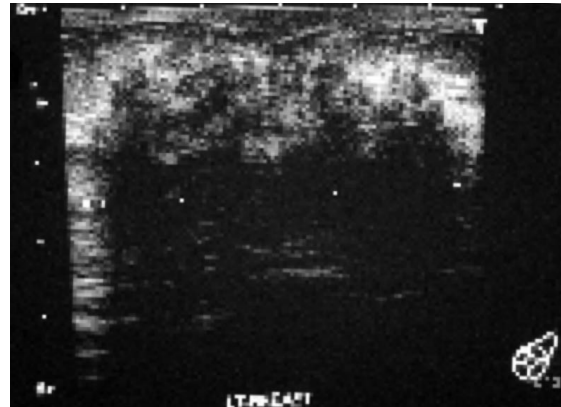


Fig. 1 Ultrasonographical image of the left breast shows posterior acoustic shadowing.

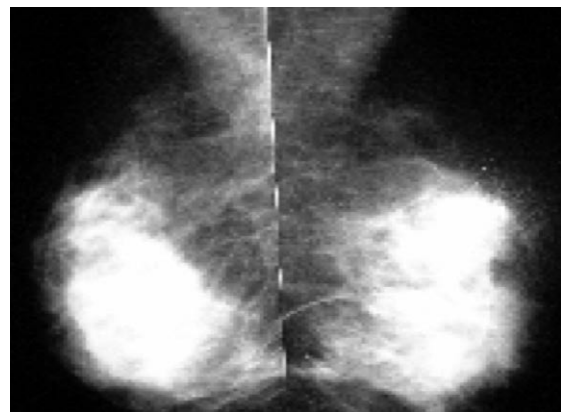

Fig. 2 Bilateral mammograms show dense breast tissue with no evidence of malignancy.

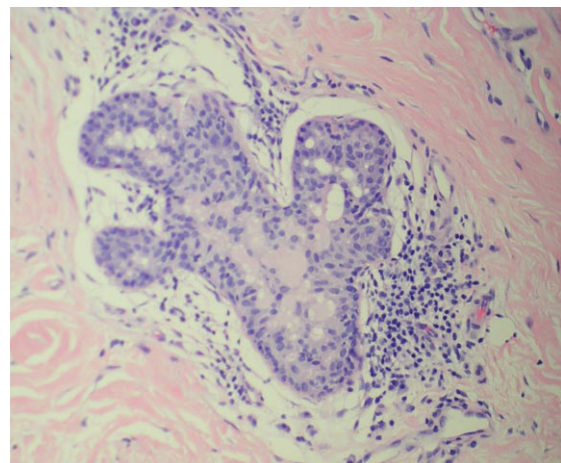


Fig. 3 Photomicrograph shows perilymphocytic infiltration (Haematoxylin & eosin, x 200).

Department of
General Surgery,
Alexandra Hospital,
378 Alexandra Road,
Singapore 159964

Lakshmanan R,
MBBS, MMed,
MRCS
Registrar

Department of
Radiology

Clarke MJ, MBBS,
FRANZCR
Consultant

Department of
Pathology,
National University
Hospital,
5 Lower Kent
Ridge Road,
Singapore 119074

Putti TC, MD
Consultant

Correspondence to:
Dr Radhika
Lakshmanan
Tel: (65) 6379 3481
Fax: (65) 6379 3880
Email: radhika_@
lakshmanan@
alexhosp.com.sg

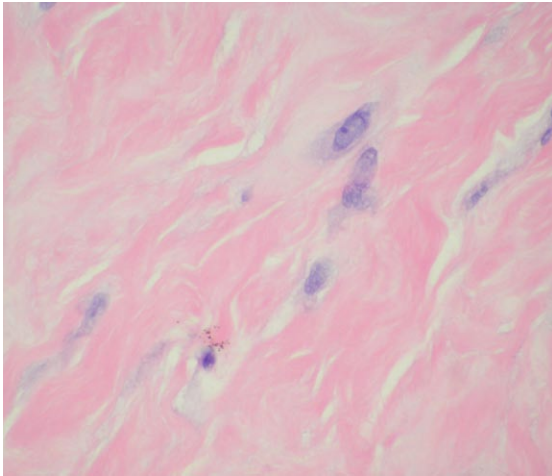


Fig. 4 Photomicrograph shows epithelioid myofibroblasts (Haematoxylin & eosin, x 400).

both lesions showed fibrosis in the right breast and only adipose tissue in the left. In view of the clinical predicament of the inability to exclude malignancy, a decision was made for open biopsy of the bilateral breast lumps. Incisional biopsy of both lesions showed lymphocytic lobulitis/ductulitis, perivascular lymphocytic infiltrate (Fig. 3) and stromal myofibroblasts (Fig. 4) consistent with DFM.

DISCUSSION

DFM represents an entity that is seen predominantly in premenopausal women with long standing IDDM. They are rarely seen in postmenopausal or NIDDM patients, as evidenced by the scarce case reports available. The incidence of DFM in women with longstanding IDDM is about 13%.⁽¹⁾ About 60% of DFM tend to be bilateral, have a predilection for the subareolar region,⁽²⁾ and recur after surgical excision.⁽³⁾ Mammographical features are usually unremarkable in DFM due to the presence of dense breast tissue. Ultrasonography shows an irregular hypoechoic mass with posterior acoustic shadowing,⁽⁴⁾ consistent with our case report. Attenuation increases in proportion to the percentage of fibrous tissue⁽⁵⁾ and the finding of strong acoustic shadowing is in keeping with the diagnosis of DFM. It needs to be highlighted that these ultrasonographical features are also characteristically seen in malignant breast disease. Recent literature propose that magnetic resonance (MR) imaging features of DFM show absence of enhancing mass with non-specific stromal enhancement as opposed to carcinoma where there is a presence of an avidly-enhancing focal mass with irregular margins.⁽⁶⁾ However, MR imaging features are not specific to DFM and may be difficult to differentiate

from malignancy without biopsy.⁽⁷⁾ The surgeon would require a histological diagnosis to exclude malignancy. On FNAC, the needle characteristically encounters an unusually firm, hard resistance.^(2,4) Cytology usually yields benign ductal epithelium with a moderate amount of peculiar-appearing, dense, hyalinised fibrous tissue.⁽²⁾ We often receive a report of “insufficient cellular material” for evaluation, another characteristic of DFM having a paucity of cellular material.⁽⁴⁾ The awareness of the clinical presentation, the imaging features and the cytological features are sufficient to diagnose DFM without the need for an excision biopsy.⁽⁸⁾ The pathological features of DFM showed lymphocytic lobulitis and ductulitis, lymphocytic vasculitis (predominantly B cell), and dense keloid-like fibrosis. The patient, demonstrating a complete constellation of pathological findings including: (1) dense fibrosis with lymphocytic ductulitis and lobulitis, (2) lymphocytic vasculitis, and (3) epithelioid fibroblasts, was found to be uniformly suffering from long-standing IDDM.⁽⁸⁾ This correlates with our patient. This paper also found that the immunophenotype of the chronic inflammatory cell infiltrate in DFM was composed primarily of B-cells which differs from the primarily T-cell infiltrate found in patients with other types of mastitis. An association between autoimmune diseases, such as IDDM, thyroid disease, and connective tissue abnormalities, have been noted.^(9,10) It is also interesting to note that while normal non-lactating breast epithelium lacks major histocompatibility complex class II products, they are seen in the epithelium of inflamed lobules.⁽⁴⁾ These inflamed lobules resemble lympho-epithelial lesions seen in other autoimmune diseases.

The publications on DFM have been few and there has been no standard protocol for the long-term management of these patients. One of the articles suggested yearly ultrasonography and FNAC if a patient is between 25 and 30 years of age. If she is older than 30 years and DFM is confirmed on histology, then yearly physical examination, mammographic and ultrasonographic examinations are recommended. However, as it has been noted that the number and size of DFM usually increases as the patient grows older, it is recommended that serial FNACs or core biopsies are performed on these new lesions to ensure that they are not malignant lesions.⁽¹¹⁾ It is not recommended to perform open excisional biopsy if clinical and radiological features are suggestive of DFM.⁽¹²⁾

In conclusion, the multidisciplinary units of breast physicians need to be aware of this entity. Correlation needs to be made with respect to the patient’s significant long-term history of IDDM

and confirmation with core biopsy. DFM is not a pre-malignant disease. Therefore, open surgical procedures to exclude malignancy should be avoided.

REFERENCES

1. Gump FE, McDermott J. Fibrous disease of the breast in juvenile diabetes. N Y State J Med 1990; 90:356-7. Comment in: N Y State J Med 1990; 90:618.
2. Rollins SD. Fine-needle aspiration cytology of diabetic fibrous mastopathy. Diagn Cytopathol 1993; 9:687-90. Comment in: Diagn Cytopathol 1994; 11:207-9.
3. Camuto PM, Zetrenne E, Ponn T. Diabetic mastopathy: a report of 5 cases and a review of literature. Arch Surg 2000; 135:1190-3.
4. Logan WW, Hoffman NY. Diabetic fibrous breast disease. Radiology 1989; 172:667-70.
5. Cole-Beuglet C, Soriano RZ, Kurtz AB, Goldberg BB. Ultrasound analysis of 104 primary breast carcinomas classified according to histopathologic type. Radiology 1983; 147:191-6.
6. Wong KT, Tse GMK, Yang WT. Ultrasound and MR imaging of diabetic mastopathy. Clin Radiol 2002; 57:730-5.
7. Sakuwara Y, Shinozaki T, Hozumi Y, et al. MR imaging of diabetic mastopathy. AJR Am J Roentgenol 2002; 179:1201-3.
8. Ely KA, Tse G, Simpson JF, Clarfeld R, Page DL. Diabetic mastopathy. A clinicopathologic review. Am J Clin Pathol 2000; 113:541-5.
9. Soler NG, Khardori R. Fibrous disease of the breast, thyroiditis, and cheiroarthropathy in type I diabetes mellitus. Lancet 1984; 1:193-5.
10. Lammie GA, Bobrow LG, Staunton MD, et al. Sclerosing lymphocytic lobulitis of the breast – evidence for an autoimmune pathogenesis. Histopathology 1991; 19:13-20.
11. Tomaszewski JE, Brooks JS, Hicks D, Livolsi VA. Diabetic mastopathy: a distinct clinicopathologic entity. Hum Pathol 1992; 23:780-6.
12. Harvey SC, Denison CM, Lester SC, et al. Fibrous nodules found at large-core needle biopsy of the breast: imaging features. Radiology 1999; 211:535-40.

So many choices, too little time.
Tired of channel surfing?



Singapore Medical Journal. The perfect channel for your publication.
Singapore Medical Journal – The voice of academic medicine in Singapore and Southeast Asia since 1960.

Enquiries
Tel: 65 6223 1264 Fax: 65 6224 7827
Email: smj@sma.org.sg Website: www.sma.org.sg