

Postpartum pneumomediastinum

Norzilawati M N, Shuhaila A, Zainul Rashid M R

ABSTRACT

A 21-year-old primigravida with previous history of pulmonary tuberculosis had a normal but assisted vaginal delivery after a prolonged second stage. Within 12 hours, she complained of dyspnoea and was found to have abnormal neck and anterior chest wall swelling. A diagnosis of subcutaneous emphysema was made and this was confirmed with the chest radiograph, which also revealed pneumomediastinum. She recovered well within four days with conservative treatment.

Keywords: postpartum complication, postpartum pneumomediastinum, subcutaneous emphysema,

Singapore Med J 2007;48(6):e174–e176

INTRODUCTION

Subcutaneous emphysema is a rare but potentially lethal complication of labour and delivery. There have been about 200 cases reported worldwide since it was mentioned over 400 years ago. This report describes a primigravida, who developed dyspnoea 12 hours following vaginal delivery.

CASE REPORT

A 21-year-old woman, a primigravida, had an uneventful antenatal care at a public hospital. She was diagnosed to have pulmonary tuberculosis in the previous year and completed medical therapy one month prior to conception. Following that, she was well with no residual complications. There was no history of smoking. She presented in established labour at 40 weeks. The first stage was short, lasting four hours only and she was given epidural analgesia. The second stage was prolonged (100 minutes) and ended with a vacuum-assisted delivery for poor maternal effort. She delivered a healthy, live male infant weighing 3.1 kg with good Apgar scores.

The immediate postpartum period was unremarkable. Twelve hours later, the patient complained of shortness of breath and pain over the neck region. There was no associated chest pain. On examination, the patient was comfortable and was in minimal distress. She was neither pale nor cyanosed

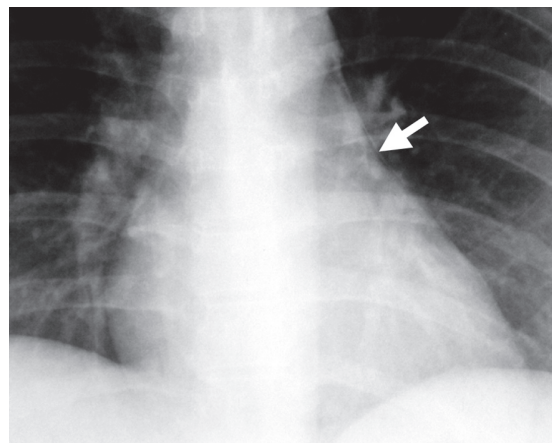


Fig. 1 Frontal chest radiograph (coned view) shows the pneumomediastinum (arrow).

but there was mild tachypnoea of 22 breaths per minute. The oxygen saturation was 98% on room air and the blood pressure and pulse were all within normal limits. The examination of the neck revealed the characteristic crepitus of subcutaneous emphysema which was palpable over the anterior neck region, both supraclavicular regions and the anterior chest wall. There was no tracheal deviation and the air entry was equal bilaterally. Electrocardiography revealed normal rhythm and the arterial blood gases was also normal. Clinical and investigative results did not reveal any evidence of pulmonary embolism or pneumothorax. The chest radiograph confirmed the absence of pneumothorax but pneumomediastinum was seen. (Fig. 1)

The patient was closely observed following the clinical diagnosis and remained well. Her dyspnoea improved and the subcutaneous emphysema did not appear to be extending. The cardiothoracic team was consulted and agreed with the conservative approach. All her symptoms and signs gradually resolved and she was discharged well on the fourth postpartum day. She was reviewed in the clinic one week later and she remained asymptomatic (Fig. 2).

DISCUSSION

Hamman's syndrome was first described in 1945,⁽¹⁾ but the first case ever reported was in 1793 by Simmons.⁽²⁾ The earliest documented account was in 1618 by the midwife of the Queen of France.⁽³⁾ This

Department of
Obstetrics and
Gynaecology,
Faculty of Medicine,
Hospital University
Kebangsaan
Malaysia,
Jalan Yaacob Latif,
Cheras 56000,
Malaysia

Norzilawati MN,
MD, MOG
Consultant and
Senior Lecturer

Shuhaila A, MD, MOG
Consultant and
Senior Lecturer

Zainul Rashid MR,
MD, PhD, FRCOG
Senior Consultant
and Professor

Correspondence to:
Dr Norzilawati
Mohd Naim
Tel: (60) 3 9170 2294
Fax: (60) 3 91738946
Email: norzila@
mail.hukm.ukm.my

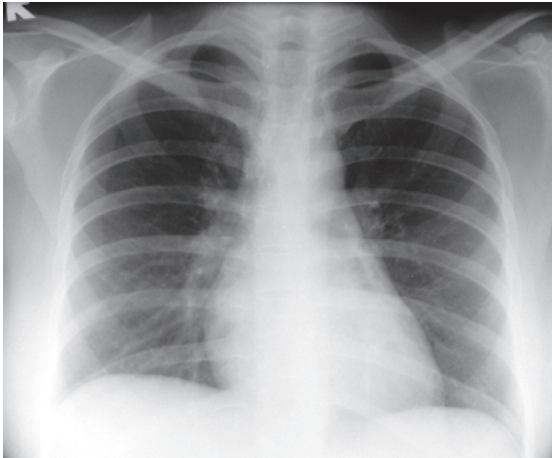


Fig. 2 Repeat frontal chest radiograph shows resolution of the pneumomediastinum two weeks later.

problem has been around for almost 400 years but it is rare with reports of approximately 200 cases worldwide so far.⁽⁴⁾ Subcutaneous emphysema and pneumomediastinum are said to occur mainly in the second stage of labour in healthy primiparous women with prolonged labour and big babies.⁽⁵⁾ Analysis of 187 cases however revealed that although 95% of women were primiparous, the length of labour was normal and the babies were of average size.⁽⁵⁾ This patient was primiparous but she did have a prolonged second stage. The baby was an average size for this population, weighing 3.01 kg.

Considerable forces and repeated Valsalva manoeuvres generated during parturition cause a wide range of complications which include detached retina, subconjunctival haemorrhage,⁽⁶⁾ possible intracranial bleeding⁽⁷⁾ and rupture of small intrapulmonary spaces or bullae.⁽⁸⁾ These intrapulmonary ruptures may lead to subcutaneous emphysema, pneumomediastinum and pneumothorax. Most of the patients present during labour and delivery^(5,9) but in this patient, the signs and symptoms developed well after the delivery. The clinical symptoms were rather worrying as respiratory symptoms in the puerperium may indicate the presence of an embolism and thus constitute an obstetrical emergency. Immediate evaluation and investigations were instituted to rule out this possible catastrophic event and surprisingly they were negative and the patient remained relatively well. Due to the rarity of this diagnosis, the clinicians have missed the “Hamman’s sign”, which is the crackling sound synchronous with the heartbeat, which suggests the presence of air in the mediastinum.

The pathophysiology is said to involve rupture of marginally-situated alveoli into perivascular tissue planes, with tracking of air into the mediastinum.

Usually, air subsequently dissects through facial planes in the neck to prevent the build up of pressure within the mediastinum, which may ultimately impede venous return to the intrathoracic veins.⁽¹⁰⁾ When this happens, the patient will end up with subcutaneous emphysema that will commonly run a more benign course, as compared to the consequences of the impediment of venous return to the intrathoracic veins. The history of pulmonary tuberculosis deserves some consideration in this particular patient as it may have made her more susceptible to this problem. The other consideration is whether she had existing pulmonary blebs due to the tuberculosis, which had ruptured into the perivascular tissue planes during the second stage of labour. In this case, conservative management was advocated, as there was no associated pneumothorax seen on the chest radiograph. Pneumothorax has been reported in about one third of cases but it has also developed independently.⁽¹¹⁾ Surprisingly, this patient did not have concomitant pneumothorax, as pneumothorax alone can occur in patients with predisposing lung disease. Pneumothorax is a complication that must be ruled out as a developing tension pneumothorax may ultimately lead to cardiorespiratory collapse.

In the absence of a pneumothorax, the pneumomediastinum and subcutaneous emphysema usually run a benign course and respond well to conservative management, as was also seen in this case. If detected during labour, it has been suggested that, apart from administration of oxygen and providing adequate analgesia, the use of nitrous oxide and repeated expulsive efforts should be avoided to prevent aggravating the problem. There may be a clear role to assist the second stage by using a pair of forceps to reduce the maternal expulsive process. In the event that delivery is done by caesarean section, then regional anaesthesia is definitely preferred as it will avoid positive pressure ventilation.⁽⁹⁾

Fortunately, apart from the rarity of the disease, pneumomediastinum is also self-limiting and usually resolves within two weeks. In this patient, the condition had resolved spontaneously within four days. Occasionally, a more severe form will occur and this has been reported as “malignant mediastinum”.⁽¹²⁾ In this disease, acute impairment of cardiorespiratory function occurs, which usually requires surgical intervention and splitting of the sternum. On other occasions, instead of following a benign course, the pneumomediastinum and subcutaneous emphysema can actually be quite extensive, persistent and symptomatic. Good outcome has been reported with infraclavicular blowholes, which involves making multiple incisions on the chest wall to allow the escape of trapped air.⁽¹³⁾

There is no consensus on the management of subsequent deliveries. Some authors have recommended assisted vaginal delivery in the hopes of reducing the intensity of the expulsive efforts during the second stage. However, as there have been no reported cases of recurrence since 1900,⁽¹⁴⁾ this practice has not been widely accepted. The fact that 95% of all cases reported were primigravidas, and only 5%⁽⁵⁾ were multiparous women, indicates that recurrence of the disease is unlikely. In fact, in one of the recent cases, even with the patient's history of chronic smoking and illicit drug abuse, she did not experience a recurrence in her next pregnancy and delivery.⁽⁸⁾ In summary, this report describes a spontaneous delivery in a primigravida, with prolonged second stage, who developed dyspnoea with clinical evidence of subcutaneous emphysema, and the chest radiograph confirmed the presence of pneumomediastinum. She recovered within four days of conservative management.

REFERENCES

1. Hamman L. Mediastinal emphysema. *JAMA* 1945; 128:1-6.
2. Simmons ST. A case of emphysema brought on by severe labor pains. *Lond Med Commun* 1783; 1:176.
3. Gordon CA. Respiratory emphysema in labour. *Am J Obstet Gynecol* 1927; 14:633-46.
4. Karson EM, Saltzman D, Davis MR. Pneumomediastinum in pregnancy: two case reports and a review of the literature, pathophysiology and management. *Obstet Gynecol* 1984; 64 (3 suppl):39S-43S.
5. Arroyo M. Subcutaneous emphysema during labour. *Int J Obstet Anesth* 2001; 10:307-8.
6. Mogil LG, Friedman AH. Ocular complications. In: Cohen WR, ed. *Cherry and Merkatz's Complications of Pregnancy*. 5th ed. Philadelphia: Lippincott, Williams and Wilkins, 2000: 233-65.
7. Carlidge NEF. Neurologic disorders. In: Barron WM, Lindheimer MD eds. *Medical Disorders during Pregnancy*. 2nd ed. St Louis: Mosby, 1995: 430-50.
8. Duffy BL. Post partum pneumomediastinum. *Anaesth Intensive Care* 2004; 32:117-9.
9. Jayran-Nejad Y. Subcutaneous emphysema in labour. *Anaesthesia* 1993; 48:139-40.
10. Weinberger SE, Weiss ST. Pulmonary diseases. In: Burrow GN, Duffy TP, eds. *Medical Complications During Pregnancy*, 5th ed. Philadelphia: WB Saunders, 1999: 363-400.
11. De Swiet M. Diseases of the respiratory system. In: De Swiet M, ed. *Medical Disorders in Obstetric Practice*. 3rd ed. Oxford: Blackwell Science, 1995: 1-32.
12. Gray JM, Hanson GC. Mediastinal emphysema: aetiology, diagnosis, and treatment. *Thorax* 1966; 21:325-32.
13. Herlan DB, Landreneau RJ, Ferson PF. Massive spontaneous subcutaneous emphysema. Acute management with infraclavicular "blow-holes". *Chest* 1992; 102:503-5. Comment in: *Chest* 1993; 104:655-6. *Chest* 1994; 105:321.
14. Reeder SR. Subcutaneous emphysema, pneumomediastinum, and pneumothorax in labor and delivery. *Am J Obstet Gynecol* 1986; 154: 487-9.