

# Technical challenges of advanced hip osteonecrosis managed using a vascularised fibular graft

Tan C H J, Sathappan S S, Chew Y C W, Ong H S

## ABSTRACT

**Management of hip osteonecrosis in the young is challenging, and femoral head preservation surgery is often preferred. We report the first local case of treating advanced hip osteonecrosis with a vascularised fibular graft in a 26-year-old man who presented with left hip pain after a fall. He was diagnosed with left hip osteonecrosis and underwent core decompression and insertion of a vascularised fibular graft. Postoperative radiographs and computed tomography of the hip were performed to assess viability of the graft. In this report, we discuss the technical considerations when operating on Asian patients and how technical difficulties are circumvented. We also report the postoperative outcome and discuss the various methods for monitoring viability of the graft.**

**Keywords: fibular graft, hip osteonecrosis, vascularised fibular graft**

*Singapore Med J 2007;48(11):e299–e303*

## INTRODUCTION

Avascular necrosis (AVN) or osteonecrosis of the hip commonly affects patients in the third to sixth decades of life, and is often associated with significant morbidity. Its natural history is one of progressive necrosis, collapse and subsequent arthrosis of the hip. Various hip-sparing options have been reported in the literature in an attempt to delay arthroplasty in these patients. Possible treatment options described in the literature include core decompression, core decompression with strut allograft, and core decompression with vascularised fibular graft, resurfacing arthroplasty and total hip arthroplasty.<sup>(1)</sup> The outcomes of these procedures are based on the disease severity of the osteonecrosis.

Femoral head preservation would be the most ideal treatment and preferred option, especially in the young patient. In this regard, vascularised bone grafts

provide a biologically active structural scaffold, which have been reported to have good outcomes in patients with osteonecrosis.<sup>(2)</sup> Various vascularised bone graft options have been described including: iliac crest,<sup>(3)</sup> greater trochanter<sup>(4)</sup> and fibular autograft.<sup>(2)</sup> In general, the use of vascularised bone grafts are reserved for the early precollapse stage of osteonecrosis. The use of vascularised fibular graft in the hip with advanced osteonecrosis with femoral head collapse (Ficat stage III)<sup>(5)</sup> has been reported by few authors,<sup>(6)</sup> and to our knowledge, the local experience in Singapore is even more limited.

We report our first experience of using vascularised fibular graft for a patient with osteonecrosis of the hip associated with femoral head collapse (Ficat stage III). Often descriptions of surgical technique in the literature originate from specialised centres performing a high volume of these procedures.<sup>(7)</sup> Thus, the instrumentation options are often extensive and would not be entirely applicable or available to institutions in Singapore. Modifications in surgical technique that are more widely applicable to non-specialised centres and postoperative management of such patients are discussed in detail.

## CASE REPORT

A 26-year-old Chinese man presented with a three-month history of progressive left groin pain and related the onset of symptoms to a prior fall. He complained of aggravation of symptoms following physical activity and his ambulation potential was significantly affected. There were no constitutional symptoms and all other joints were normal. There was no previous history of paediatric hip disorders, alcohol abuse or intake of oral steroids.

Clinical examination revealed an antalgic gait with 5 mm shortening of the left leg. Examination of the right hip was unremarkable. The left hip, however, had an externally rotated attitude with tenderness on palpation of the hip joint. The range of motion was almost full with pain at extremes of flexion, internal rotation and external rotation. Laboratory data showed a normal full blood count, erythrocyte sedimentation rate and C-reactive protein level. An

Department of  
Orthopaedic  
Surgery,  
Tan Tock Seng  
Hospital,  
11 Jalan Tan  
Tock Seng,  
Singapore 308433

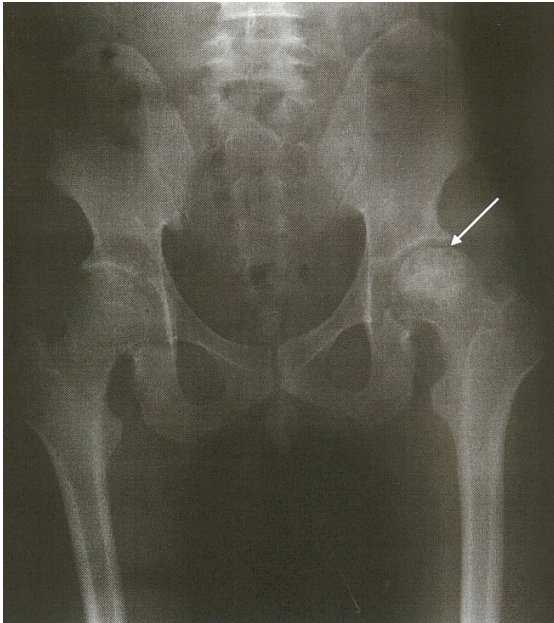
Tan CHJ, MBBS,  
MRCSE  
Medical Officer

Sathappan SS,  
MBChB, MMed,  
FRCS  
Consultant and  
Clinician Scientist

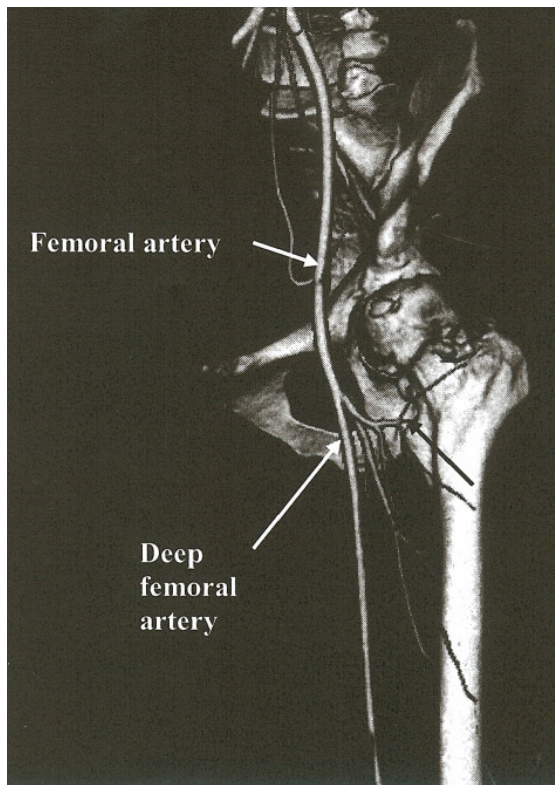
Chew YCW, MBBS,  
FRCSE, FAMS  
Senior Consultant  
and Head

Ong HS, MBBS,  
MMed, MRCSE  
Registrar

**Correspondence to:**  
Dr SS Sathappan  
Tel: (65) 6357 7713  
Fax: (65) 6357 7715  
Email: sathappan@  
ttsh.com.sg



**Fig. 1** Antero-posterior radiograph of the patient's pelvis shows a subchondral collapse of the left femoral head (arrow).

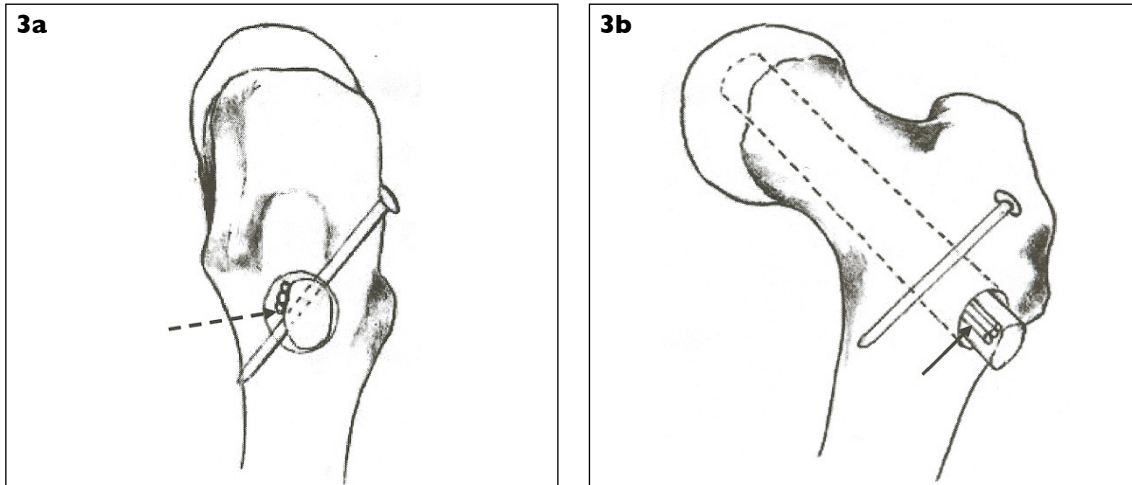


**Fig. 2** CT angiogram, with three-dimensional reconstruction of the patient's left hip, shows the transverse branch of the lateral femoral circumflex artery (black arrow).

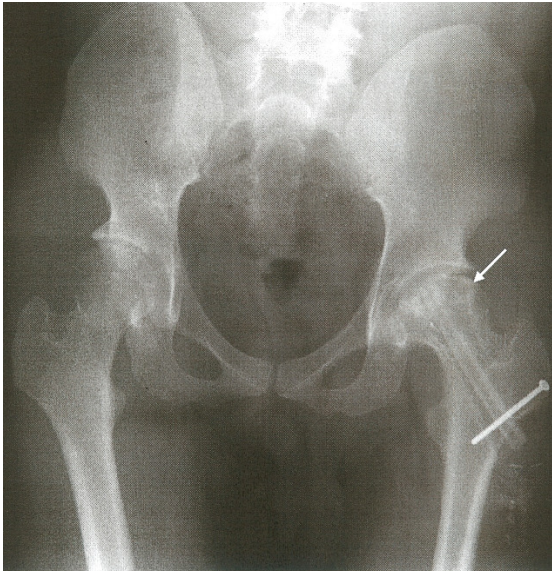
anterio-posterior and lateral radiograph of the left hip revealed Ficat III AVN and was characterised with femoral head collapse (Fig. 1). Magnetic resonance (MR) imaging was done primarily to

screen the contralateral hip and was confirmed to be normal. There was no acetabular involvement in the left hip. Various treatment options were discussed with the patient and he opted for vascularised fibular graft. Computed tomography (CT) angiogram of the left hip was performed to evaluate the arterial mapping to facilitate surgical planning (Fig. 2). The lateral circumflex artery and its related branches were confirmed to be patent.

The patient was positioned on a traction table and a curvilinear longitudinal incision was made on the left thigh. Following division of the tensor fascia lata and the vastus lateralis, the lateral femoral circumflex artery and its related branches were identified. There are three main branches that were both seen in the CT angiogram and in the operative field, and consist of: ascending branch, transverse branch and descending branch. The use of the ascending branch has been previously described but we opted to trace and preserve the transverse branch due to the appreciable calibre of the vessel.<sup>(7)</sup> With the aid of an image intensifier, a guidewire was inserted into the femoral neck and triple reaming was performed using a dynamic hip screw reamer (Synthes, Solothurn, Switzerland). This was sequentially widened using flexible reamers to create a 13-mm channel. This osseous channel was essential since the fibular diameter of the patient was 10 mm, based on digital radiographic measurements. The clearance of the sclerotic subchondral bone was rather difficult as we did not have the special custom-made reamers that have been described by Aldridge et al.<sup>(7)</sup> A Midax bulb reamer (Stryker, Mahwah, New Jersey, USA) was used instead, to enable complete clearance of the sclerotic bone. Using bone tamps, the collapsed articular segments were gently tapped upwards. Water-soluble contrast was injected into the osseous femoral channel and the image intensifier revealed a light-bulb shaped femoral head image confirming adequate femoral head preparation. The hip wound was provisionally closed. The patient was placed in a lateral decubitus position and the entire left lower limb was prepared. A lateral longitudinal incision was made. The fibular was accessed by dividing the anterior and posterior intermuscular septa, as well as the interosseous membrane. Fibular osteotomy was performed 10 cm distal to the fibular head and 10 cm proximal to the lateral malleolus. Peroneal vascular pedicle was isolated and was divided in near proximity to the popliteal arterial trifurcation so as to maximise the length of the harvested vascular pedicle. The fibular graft measured 13.5 cm and had a vascular pedicle of 5 cm.



**Fig. 3** Diagrammatic representation shows the (a) lateral and (b) antero-lateral views of the fibular graft secured in the femoral osseous canal by a cortical screw. A 3-mm clear space (broken arrow) between the anterior wall of the canal and vascular pedicle (full arrow) was ensured.



**Fig. 4** Anterior-posterior radiograph of the patient's pelvis, taken three months after surgery, shows osteointegration of the graft (arrow).

The hip wound was reaccessed and remainings from the earlier procedure (bone "slurry") was gently compacted into the bulbous end of the femur with the use of a bone tamp. The fibular graft was then inserted into the osseous channel (Fig 3). There was approximately 3 mm clear space permitted for the vascular pedicle to avoid compression within the osseous channel. The appropriate cephalad sitting of the graft was confirmed with the image intensifier; secure fixation was attained using a 3.5 mm cortical screw. The transverse branch of the lateral femoral circumflex artery and the accompanying venae comitantes were microsurgically anastomosed to

the fibular peroneal vessels. The tensor fascia lata overlying the vascular anastomosis site was not plicated to avoid compromising graft vascularity. Postoperative recovery was uneventful and the patient was kept on non-weight bearing ambulation for six weeks and was commenced on progressive weight-bearing ambulation thereafter. Flexor hallucis longus contracture was a potential complication as its nerve branches run along peroneal vessels.<sup>(7)</sup> This was avoided by fitting the patient's left leg with an ankle foot orthosis at the postoperative period for six weeks.

Radiographs at two, four and eight weeks revealed satisfactory graft positions with no features of femoral head collapse. During his six, nine and 12 months postoperative follow-ups, radiographs revealed progressive osteointegration of the fibular autograft (Fig. 4). We repeated the CT angiogram of the left hip three months following the index procedure and it confirmed a patent vascular anastomosis with sustained vascularity to the femoral head. He is currently in the 12-month postoperative period, and clinical examination at the last review revealed pain-free full weight-bearing with hip range of motion as follows: flexion 120°, abduction 60°, adduction 15°, internal rotation 40° and external rotation 40°. He had neither ankle pain nor any features of flexor hallucis longus contracture. He has already returned to work as a car washer.

## DISCUSSION

Osteonecrosis is a significant problem in our local population; approximately a quarter of the patients undergoing total hip arthroplasty in our institution have a primary diagnosis of osteonecrosis.<sup>(8)</sup> The disease stage is an important determinant of the possible

**Table I. Radiological features and treatment of various stages of hip AVN.**

	Symptoms	Radiographs	Bone scan	MR imaging	Management
Stage I	Pain	Normal	Decreased uptake	Bone oedema	Core decompression
Stage II	Pain	Cysts with or without sclerosis	Increased uptake	Hypervascular necrotic region surrounded by zone of fibrosis <sup>(13)</sup> (Double line sign)	Core decompression with allograft or vascularised fibular autograft
Stage III	Pain	Subchondral collapse (Crescent sign)	Increased uptake	Subchondral collapse, marrow oedema, joint effusion <sup>(13)</sup>	Resurfacing arthroplasty
Stage IV	Pain	Osteoarthritis	Increased uptake	Acetabular and femoral head arthrosis	Total hip replacement

management options that can be considered. Disease staging is typically done with the use of radiographic modalities; the Ficat and Arlet classification<sup>(5)</sup> is one of the more commonly-used methods (Table I). The mainstay for treatment of AVN of the hip is surgery. Core decompression of the femoral head is indicated for stage I AVN, core decompression with strut allograft or vascularised fibular graft for stage II AVN, resurfacing arthroplasty for stage III AVN and total hip arthroplasty for stage IV AVN. Although radiographic parameters, particularly collapse of the femoral head and acetabular dysplasia, influence the choice of surgical treatment, age should also be considered. Patients in their teens would be appropriate candidates for femoral head-sparing procedures, whereas older patients (aged 60 years and older) may be suitable for hip arthroplasty procedures when bone-sparing or cartilage-sparing procedures would be expected to be less efficacious. Vascularised fibular graft was offered to our patient despite stage III AVN because of his young age. Scully et al had treated symptomatic patients younger than 50 years of age with stage III AVN successfully. 700 hips studied by Scully et al showed survival rates (at 50 months) of vascularised fibular graft exceeding 80% for Ficat I–III AVN of the hip.<sup>(2)</sup> Donor-site morbidity was studied in 247 cases of vascularised fibular graft by Vail and Urbaniak.<sup>(9)</sup> Results at the end of five years showed 2.7% objective motor weakness, 11.8% sensory deficits, 11.5% ankle pain and 8.9% pain at sites other than the ankle. The benefits of vascularised fibular graft clearly outweigh its morbidity.

The surgical technique popularised by Aldridge et al often describes the use of custom-made instrumentation,<sup>(7)</sup> which may not be applicable to many centres, including our institution, due to the limitation of available resources. The alternative options in instrumentation have already been described earlier. Furthermore, certain specific surgical technique modifications were also done. Bone graft supplementation for the prepared femoral head was

not harvested from the greater trochanter. We used the filtered bone “slurry” obtained from femoral neck triple reamings; the necrotic bone from the femoral head was discarded. It is our opinion that the proximal femoral anatomy is smaller in Asians,<sup>(10)</sup> and bone harvest from the subtrochanteric region can increase the risk of fracture. Aldridge et al secured the graft with a 0.062-mm Kirschner wire that crossed both fibular cortices and femoral cortex at the lesser trochanter. In this patient, a 3.5 mm/50 mm screw was preferred for greater stability and to facilitate an optimal osseous integration. Anastomosis of the veins with 9/0 ethilon sutures under the microscope was performed, while Aldridge et al had the benefit of the microvascular anastomotic coupler system.<sup>(7)</sup>

Conventionally, postoperative monitoring of graft survivorship is conducted with the use of radiographs.<sup>(2,7)</sup> We supplemented radiographs with the use of CT angiogram at the two-month postoperative period. It showed the patency of the anastomosis. Other alternative methods of postoperative monitoring of vascularity of fibular graft include dynamic MR imaging,<sup>(11)</sup> bone scans<sup>(12)</sup> and digital angiograms.<sup>(12)</sup> CT angiogram was chosen for its noninvasiveness and its ability to allow three-dimensional reconstruction of vessels, which was also extremely useful in preoperative planning. Bone scan involves the injection of contrast material, and interpretation in the early postoperative period can be difficult. Dynamic MR imaging was not suitable, as it measures the degree of bone marrow perfusion (visualised as a perfusion curve) and does not allow visualisation of the anastomosis. Moreover, in the presence of orthopaedic hardware, MR imaging is associated with magnetic scatter. We acknowledge that these investigative tools are primarily used as research and investigative adjuncts. Therefore, serial radiographs are still the preferred follow-up imaging modality of choice because of its low cost and availability.

The pathophysiology in osteonecrosis is still obscure, and this often makes definitive management

challenging, especially when this condition also affects young patients. The ideal treatment option is one which spares the femoral head with minimal surgical morbidity. Vascularised fibular graft can be used with good results in young patients with hip AVN. Adjustments in surgical techniques and alternative choices in instrumentation can be easily made to accommodate the capabilities of different institutions. With increasing surgical experience in this technique, this treatment can be more extensively applied to more patients with hip osteonecrosis.

#### ACKNOWLEDGEMENT

The authors thank Dr Liang Weihao for the sketches in Figs. 3a and b.

#### REFERENCES

- Lieberman JR, Berry DJ, Mont MA, et al. Osteonecrosis of the hip: management in the 21st century. *Instr Course Lect* 2003; 52:337-55.
- Scully SP, Aaron RK, Urbaniak JR. Survival analysis of hips treated with core decompression or vascularised fibular grafting because of avascular necrosis. *J Bone Joint Surg Am* 1998; 80:1270-5.
- Eisenschenk A, Lautenbach M, Schwetlick G, Weber U. Treatment of femoral head necrosis with vascularized iliac crest transplants. *Clin Orthop Relat Res* 2001; 386:100-5.
- Pucher A, Ruszkowski K, Bernardczyk K, Nowicki J. The value of distal greater trochanteric transfer in the treatment of deformity of the proximal femur owing to avascular necrosis. *J Pediatr Orthop* 2000 20:311-6.
- Ficat RP. Idiopathic bone necrosis of the femoral head. Early diagnosis and treatment. *J Bone Joint Surg Br* 1985; 67:3-9.
- Berend KR, Gunneson EE, Urbaniak JR. Free vascularized fibular grafting for the treatment of postcollapse osteonecrosis of the femoral head. *J Bone Joint Surg Am* 2003; 85:987-93.
- Aldridge JM 3rd, Berend KR, Gunneson EE, Urbaniak JR. Free vascularised fibular grafting for the treatment of postcollapse osteonecrosis of the femoral head. Surgical technique. *J Bone Joint Surg Am* 2004; 86(Suppl 1):87-101.
- Liu YEB, Hu S, Chan SP, Sathappan SS. The epidemiology and surgical outcomes of patients undergoing primary total hip replacement: An Asian Perspective. Singapore: 29th Annual Scientific Meeting of Singapore Orthopaedic Association, 2006.
- Vail TP, Urbaniak JR. Donor-site morbidity with use of vascularized autogenous fibular grafts. *J Bone Joint Surg Am* 1996; 78:204-11.
- Hoaglund FT, Low WD. Anatomy of the femoral neck and head, with comparative data from Caucasians and Hong Kong Chinese. *Clin Orthop Relat Res* 1980; 152:10-6.
- Bey E, Paraque A, Pharaboz C, Cariou JL. [Postoperative monitoring of free fibular grafts by dynamic magnetic resonance imaging. Preliminary results in three cases of mandibular reconstruction]. *Ann Chir Plast Esthet* 2001; 46:10-7. French.
- Malizos KN, Soucacos PN, Vragalas V, et al. Three phase bone scanning and digital arteriograms for monitoring vascularized fibular grafts in femoral head necrosis. *Int Angiol* 1995; 14:319-26.
- Saini A, Saifuddin A. MRI of osteonecrosis. *Clin Radiol* 2004; 59:1079-93.