

Patients' perception of transnasal gastroscopy

Luman W

ABSTRACT

Introduction: Gastroscopy is an excellent technique for investigation of upper gastrointestinal pathology. However, patients frequently request for conscious sedation as the procedure causes pain, pharyngeal reflex and nausea. Administration of conscious sedation incurs additional medical expenditure and risks. Transnasal gastroscopy, which became commercially available in 2005, does not induce pharyngeal reflex. The aim of this study was to examine patients' perception and satisfaction with transnasal gastroscopy performed in an office setting.

Methods: Questionnaires were administered to consecutive patients after the performance of transnasal gastroscopy. Patients received topical ten percent xylocaine spray to the nasal and pharyngeal cavities 1-2 minutes before the procedure. The transnasal endoscope used was a narrow upper gastrointestinal endoscope (EG270N5 [Fujinon, Saitama City, Japan]).

Results: Transnasal gastroscopy was attempted in 96 patients. The procedure failed in one patient due to a narrow nasal passage and had to be converted to oral route of intubation. Questionnaires were completed by 96 patients. There were 52 males (54 percent) with the median age of 43 (range 11-85) years. None of them received conscious sedation. 53 patients (56 percent) reported that there was no pain/discomfort during the procedure. On the Lickert visual analogue scale for pain from 0 to 10 points, 91 patients (96 percent) reported severity of pain of below 5 points. 85 patients (89 percent) reported they were satisfied or more than satisfied with the procedure. 84 patients (88 percent) were happy to undergo similar repeat procedure without sedation. 25 patients (26 percent) had undergone previous oral gastroscopy; 22 of these patients reported that transnasal route was definitely more comfortable than the oral route. There were two incidents of nosebleed which were self-limiting.

Conclusion: Transnasal gastroscopy with a thin

endoscope was found to be safe. The procedure is well-tolerated by patients without conscious sedation. Patients reported better preference for transnasal endoscopes in comparison to conventional transoral gastroscopy.

Keywords: dyspepsia, endoscopy, gastroscopy, patients' perception, transnasal gastroscopy

Singapore Med J 2008;49(4):339-341

INTRODUCTION

Gastroscopy is a widely-used method for detecting upper gastrointestinal diseases. However, hypoxia, elevations of blood pressure and heart rate have repeatedly been demonstrated during gastroscopy.^(1,2) These potentially harmful side-effects are sometimes life-threatening, particularly for patients with underlying cardiopulmonary disease. Patients often find the procedure to be unpleasant and often ask for sedatives to be administered during the procedure. Although it has been shown that sedation during gastroscopy helps to prevent the increase in blood pressure and heart rate, hypoxia still remains a potential risk following administration of sedation.⁽³⁾ Recently, small-calibre upper gastrointestinal endoscopes have been developed and marketed. These endoscopes can be inserted transnasally. They have been reported to cause less choking sensations and gagging episodes in comparison with transoral gastroscopes. They have also been reported to have good tolerability for patients.^(4,5) The aim of this prospective study was to document patients' perception and tolerability of transnasal gastroscopy.

METHODS

This prospective study was performed in an office-based setting in a private medical centre. The procedures were performed by a single endoscopist (WL). The study was carried out between August 2006 and November 2007. Consecutive patients undergoing gastroscopy for dyspepsia were recruited for the study. None of the patients received conscious sedation. Patients received topical 10% xylocaine spray to the nasal and pharyngeal cavities 1-2 minutes before the procedure. On average, they received six puffs corresponding to 60 mg of xylocaine. Patients were also instructed to inhale 2% lignocaine jelly into both nostrils just before insertion of the gastroscope.

W Luman Digestive and Liver Clinic Pte Ltd, Mt Elizabeth Medical Centre, #09-01, 3 Mount Elizabeth, Singapore 228510

Luman W, MBChB, FRCP, FAMS Consultant Gastroenterologist and General Physician

Correspondence to: Dr Widjaja Luman
Tel: (65) 6732 7710
Fax: (65) 6734 5256
Email: wijluman@singnet.com.sg

The transnasal gastroscope used was a narrow upper gastrointestinal endoscope (EG270N5 [Fujinon, Saitama City, Japan]) with a Fujinon system processor 2200. It had an outer diameter 5.9 mm, forceps channel 2.0 mm, length 110 cm and an air/water channel. Examinations were carried out with the patients in the left lateral recumbent position and the endoscope was introduced by the endoscopist under direct vision. The examination was performed in a standardised way, reaching the second part of the duodenum and carrying out gastric retroversion to explore the cardia and fundus. Endoscopic biopsies were taken when considered necessary.

Questionnaires were administered to these patients after the transnasal gastroscopic procedure. This questionnaire asked for their total impression of the transnasal gastroscopy, rating the levels of discomfort, tolerance and satisfaction. Their level of pain/discomfort was assessed using a 100-mm visual analogue scale. Patients also stated whether or not they would wish to be sedated for a possible further examination of the same type. Patients, who had previously undergone conventional gastroscopy through the oral route, were asked the additional question of whether their experience in the current examination was similar to, better or worse than the conventional transoral examination. They were also asked for their preference for their next upper gastrointestinal endoscopy: transnasal or conventional transoral gastroscopy.

RESULTS

Transnasal gastroscopy was attempted in 96 patients. The procedure failed in one patient due to a narrow nasal passage and had to be converted to the oral route of intubation. None of the remaining 95 patients received conscious sedation for the procedure. Questionnaires were completed by 95 patients. There were 52 males (54%) with a median age of 43 (range 11–85) years. 53 patients (56%) reported that there was no pain/discomfort during the procedure. On the Lickert visual analogue scale for pain from 0 to 10 points, 91 patients (95%) reported a severity of pain of below 5 points (Fig. 1). 85 patients (89%) reported they were satisfied or more than satisfied with the procedure (Fig. 2). 84 patients (88%) were happy to undergo a similar repeat procedure without sedation. 25 patients (26%) had undergone previous conventional transoral gastroscopy; 22 of these patients reported that the transnasal route was definitely more comfortable than the oral route. There were two incidents of nosebleed and both cases of complication were self-limiting.

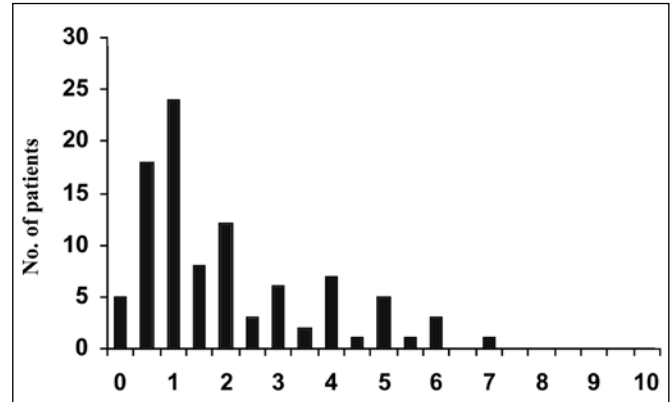


Fig. 1 Bar chart shows the number of patients against the level of discomfort/pain on the Lickert scale.

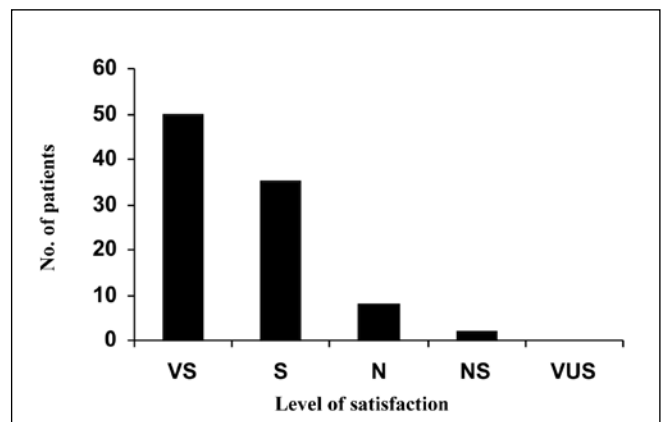


Fig. 2 Bar chart shows the number of patients against their satisfaction level.

VS: very satisfied; S: satisfied; N: neutral; NS: not satisfied; VUS: very unsatisfied.

DISCUSSION

The results of the present study show that transnasal gastroscopy is an easy and safe procedure. Patients tolerated the procedure well, even without conscious sedation. There was no cardiopulmonary complication noted during the procedure. The only complication noted was two cases of nosebleeds, which were both self-limiting. These findings are in agreement with earlier ones, in that transnasal gastroscopy induced less frequent gagging episodes, nausea, choking sensation and pharyngeal discomfort.^(6,7) This is not related to the diameter of the endoscopes. Per oral introduction of similarly thin endoscopes causes a similar degree of retching as conventional gastroscopes.⁽⁷⁾ Nasal introduction offers a direct pathway to the oesophagus, avoiding exacerbation of the gag reflex caused by contact of per oral endoscopes with the base of the tongue, soft palate, and posterior pharyngeal wall. Thus, the risk of vomiting and aspiration

is lower with the transnasal route.

The transnasal route of insertion has been shown to not induce a drop in oxygen saturation. Increase in blood pressure and heart rate was also found to be less pronounced with the transnasal route.^(6,8) Fewer adverse effects on the cardiopulmonary system means increased safety of the procedure. Conscious sedation is often required for conventional transoral gastroscopy as it is associated with unpleasant experiences of choking sensations and gagging episodes. Although sedation provides anterograde amnesia, which in turn improves tolerance, and also helps to prevent the increase in blood pressure and heart rate,⁽³⁾ there is the risk of hypoxia and drug reaction during the procedure.^(3,6) It also drives up the cost of the procedure, as patients require more nursing care and a longer period of hospitalisation during recovery. There is also an increase in indirect costs, as patients must be accompanied to the hospital for the procedure, and are advised not to drive or work on the day of the procedure.

In the current study, most patients were willing to undergo the transnasal route again, even without the administration of conscious sedation. The present study included 25 patients (26%) who had prior conventional gastroscopy. This allowed comparison of prior and current endoscopic tolerance in the same patients. However, this comparison is controversial as most of these patients had undergone prior conventional gastroscopy under conscious sedation. Nevertheless, majority of the patients reported a preference for transnasal gastroscopy. The evidence from a formal comparative study with per oral gastroscopies would certainly be stronger, provided such a study is performed with the patients undergoing the endoscopic procedures twice, i.e. transnasal and per oral gastroscopies. Furthermore, per oral gastroscopies should not be performed under conscious sedation.

In the current model, no difficulty was experienced

in the passage of the endoscopes through the pylorus or second part of the duodenum. The only difficulty the author experienced was the longer time required to aspirate gastric secretion and mucus with these thin endoscopes. One possible application with these thin endoscopes is passage across tight oesophageal strictures⁽⁹⁾ or placement of feeding tubes.⁽¹⁰⁾ Transnasal gastroscopy with thin endoscopes was found to be safe, well-tolerated and accepted by patients even without conscious sedation. It also has the potential of being more cost effective than conventional per oral gastroscopy.

REFERENCES

1. Azuma M. Electrographic changes during gastroendoscopy. *Gastroenterol Endosc* 1981; 189:201.
2. Kinoshita Y, Ishido S, Nishiyama K, et al. Arterial oxygen saturation, blood pressure, and pulse rate during upper gastrointestinal endoscopy-influence of sedation and age. *J Clin Gastroenterol* 1991; 13:656-60.
3. Bell GD. Review article: premedication and intravenous sedation for upper gastrointestinal endoscopy. *Aliment Pharmacol Ther* 1990; 4:103-22.
4. Zaman A, Hahn M, Hapke R, et al. A randomized trial of peroral versus transnasal unsedated endoscopy using an ultrathin videoendoscope. *Gastrointest Endosc* 1999; 49:279-84.
5. Craig A, Hanlon J, Dent J, Schoeman M. A comparison of transnasal and transoral endoscopy with small-diameter endoscopes in unsedated patients. *Gastrointest Endosc* 1999; 49:292-6.
6. Yagi J, Adachi K, Arima N, et al. A prospective randomized comparative study on the safety and tolerability of transnasal esophagogastroduodenoscopy. *Endoscopy* 2005; 37:1226-31.
7. Campo R, Montserrat A, Brullet E. Transnasal gastroscopy compared to conventional gastroscopy: a randomized study of feasibility, safety, and tolerance. *Endoscopy* 1998; 30:448-52.
8. Dean R, Dua K, Massey B, et al. A comparative study of unsedated transnasal esophagogastroduodenoscopy and conventional EGD. *Gastrointest Endosc* 1996; 44:422-4.
9. De Gregorio BT, Poorman JC, Katon RM. Peroral ultrathin endoscopy in adult patients. *Gastrointest Endosc* 1997; 45:303-6.
10. Bordas JM, Llach J, Mondelo F, et al. Nasogastric tube insertion over a guidewire placed with a thin transnasal gastroscope. *Gastrointest Endosc* 1996; 43:83.