

CME Article

Clinics in diagnostic imaging (I22)

Rasheed S, Peh W C G, Chin T W

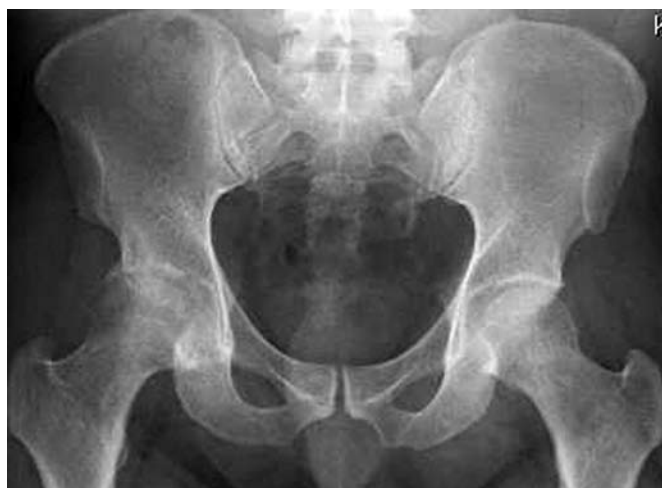

Fig. 1 Anteroposterior radiograph of the pelvis.

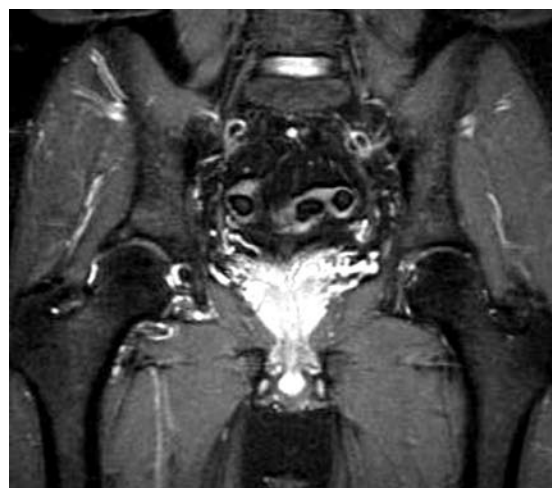

Fig. 2a Coronal fat saturated T2-W MR image of the pelvis.

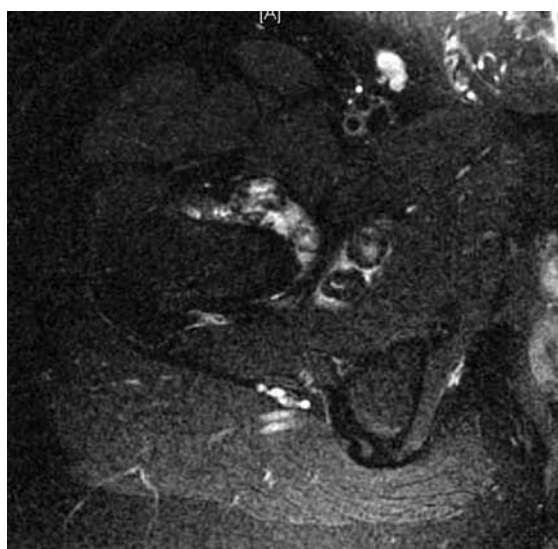

Fig. 2b Axial fat saturated T2-W MR image of the right hip.

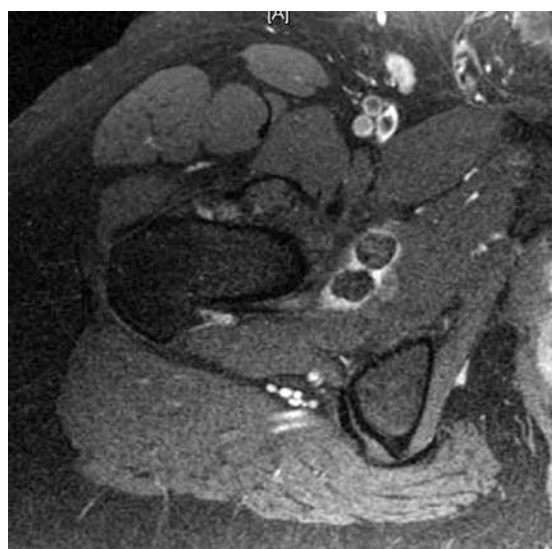

Fig. 2c Axial contrast-enhanced fat saturated T1-W MR image of the right hip.

CASE PRESENTATION

A 37-year-old Indian man presented with right hip pain for the past two years. The pain was gradual in onset, mechanical in nature, worse on walking, and relieved by rest. There was no previous history of trauma and he was able to walk without assistance. He was

also able to squat. He had no past medical history. On examination, the patient had pain on internal and external rotation, but full flexion of the hip joint was possible. What do radiographs (Fig. 1) and magnetic resonance (MR) imaging (Figs. 2a-c) of the right hip show? What is the diagnosis?

Department of Diagnostic Radiology, Alexandra Hospital, 378 Alexandra Road, Singapore 159964

Rasheed S, BSc, MBBCh, LRCPSI
Medical Officer

Peh WCG, MD, FRCP, FRCR
Clinical Professor and Senior Consultant

Department of Orthopaedic Surgery

Chin TW, MBBS, FRCSE, FRCR
Senior Consultant and Head

Correspondence to: Prof Wilfred CG Peh
Tel: (65) 6379 3283
Fax: (65) 6476 4571
Email: wilfred.peh@gmail.com

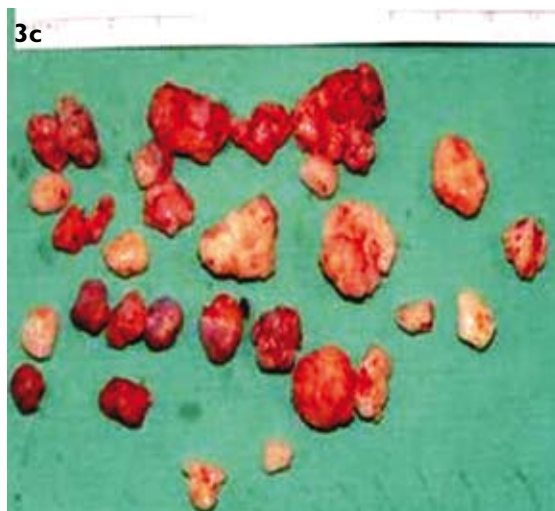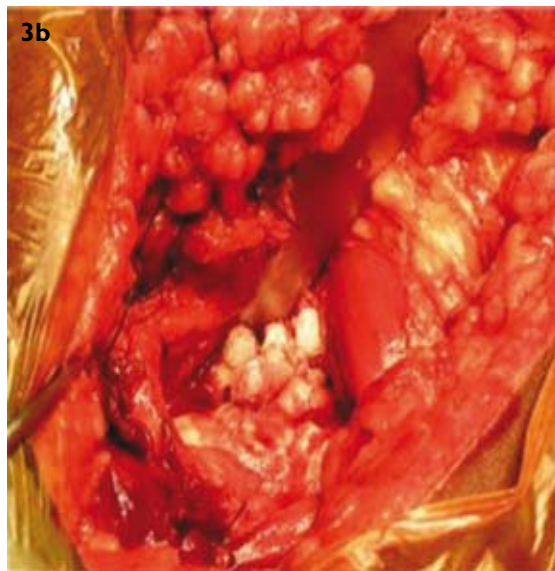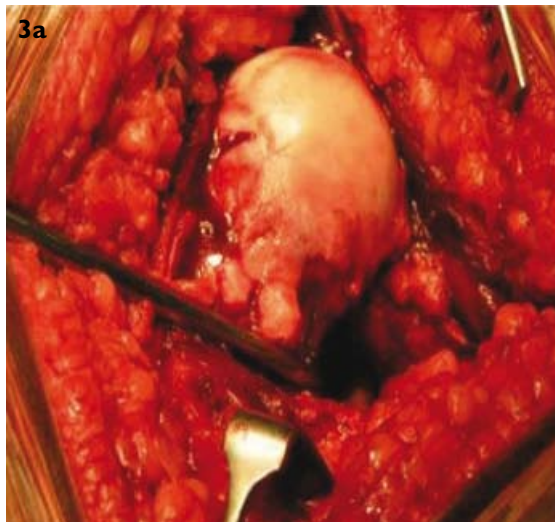


Fig. 3 Intraoperative photographs show (a) the exposed femoral head together with hypertrophied synovium; and (b) multiple loose bodies within the hip joint. (c) Specimen photograph shows some of the loose bodies.

IMAGE INTERPRETATION

The radiograph of the right hip (Fig. 1) showed mild degenerative changes with marginal osteophytes.

Small faint dense nodules were seen at the infero-medial aspect of the right hip. The left hip joint is normal. MR imaging (Fig. 2) showed a small effusion in the right hip joint. Multiple rounded lesions that were T2-hypointense and T1-hypointense were present. They were surrounded by joint fluid and located mainly at the inferior and medial parts of the right hip joint. Mild synovial enhancement was present. These appearances were consistent with mild hip joint synovitis with multiple intra-articular ossified loose bodies. An incidental finding of a small right lateral supra-acetabular subchondral cyst was also seen. No bone or joint erosion was otherwise detected.

DIAGNOSIS

Synovial osteochondromatosis of the hip joint.

CLINICAL COURSE

The patient was admitted electively for a right hip arthrotomy and synovectomy. At surgery, a total of 31 loose bodies were removed. The synovium of the hip joint was hypertrophied (Figs. 3a-c). The diagnosis of synovial osteochondromatosis (SOC) was confirmed histologically. Postoperative recovery was uneventful and the patient was discharged two days after surgery. At the follow-up appointment two weeks later, the wound was healthy, well-healed and non-tender. The patient was able to walk short distances and underwent a course of physiotherapy.

DISCUSSION

SOC is a benign condition where there is development of numerous intra-articular nodules that undergo cartilaginous changes in the synovial membranes of joints, bursa and tendon sheaths.⁽¹⁾ The synovial lining of a joint, tendon sheath or bursa are thought to undergo proliferation and metaplasia to form these nodules. The nodules can detach and lie free in the joint as loose bodies, where they get nourishment from the synovial fluid, and typically ossify.^(1,2) The disease is gradually progressive, and can exist in the primary form or secondary form in association with osteoarthritis⁽²⁾ (Fig. 4). It has a higher incidence in males compared to females, and is most frequent in the 20–50 year age group.⁽¹⁾

The knee (Fig. 5) is the most common site involved, followed by the elbow (Fig. 6), hip, shoulder, ankle and wrists.⁽²⁾ Patients often present with chronic and progressive pain with limitation of movement. Swelling and joint effusion may also be present. In some cases, the effusion may be haemorrhagic. The disease can exist in three phases.⁽³⁾ In phase one, there is active intrasynovial disease without loose bodies. In phase two, osteochondral nodules are present in the synovial membrane, with osteochondral bodies lying free in the

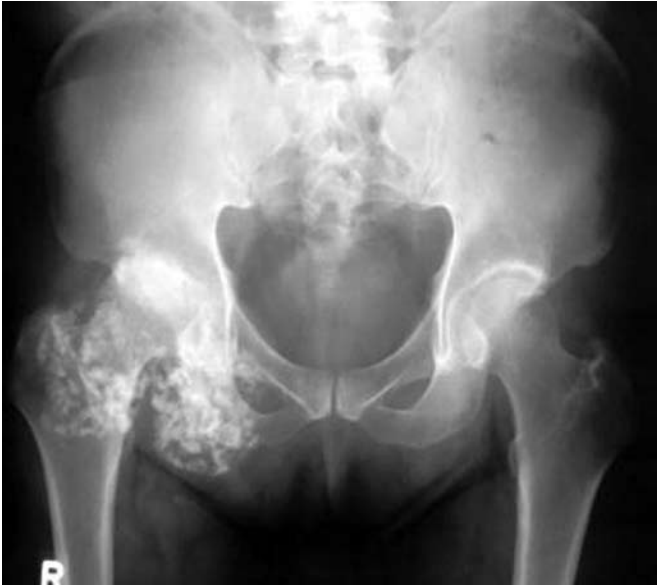

Fig. 4 Anteroposterior pelvic radiograph of a 55-year-old man with synovial osteochondromatosis shows numerous densely-ossified loose bodies confined within and distending the capsular margins of the right hip joint. There are associated degenerative changes and marked joint space narrowing. The left hip is normal.

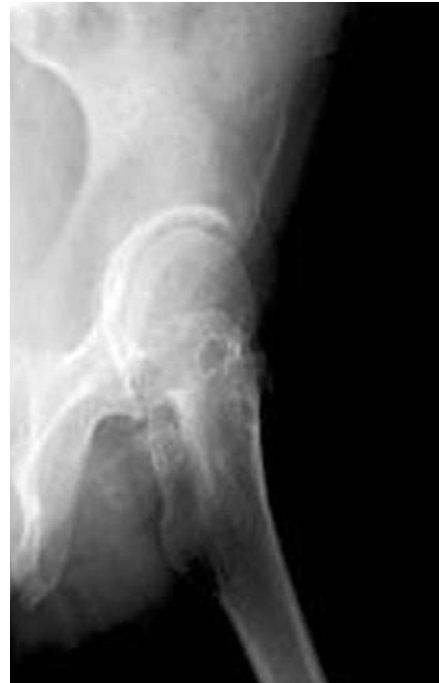

Fig. 7 Lateral hip radiograph of a 57-year-old woman with synovial osteochondromatosis shows small faint dense loose bodies and prominent pressure erosions of the left femoral neck.

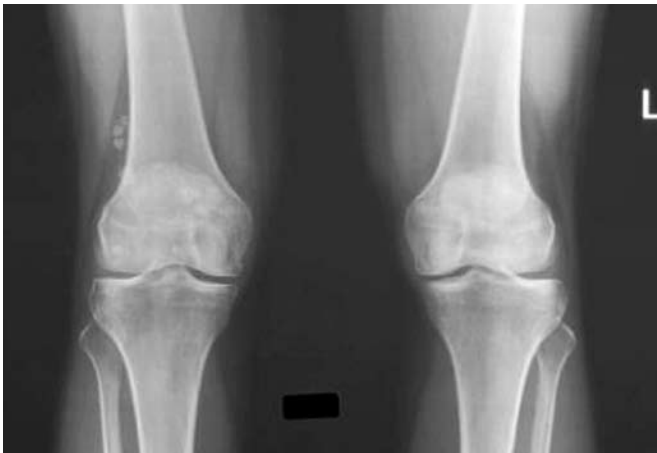


Fig. 5 Anteroposterior knee radiograph of a 43-year-old woman with synovial osteochondromatosis shows multiple dense rounded loose bodies in and around the right knee, conforming to the capsular margins of the knee joint.

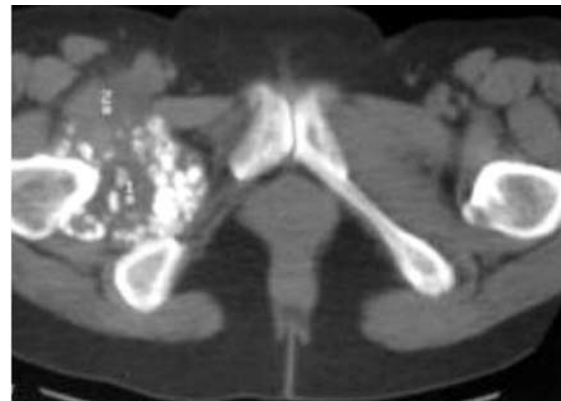

Fig. 8 Axial CT image of the hips in a 54-year-old man with synovial osteochondromatosis shows multiple ossified loose bodies confined within the capsular margins of the effusion-distended right hip joint.

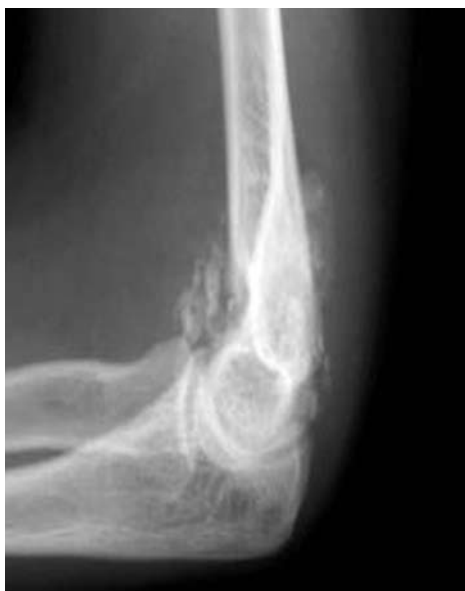

Fig. 6 Lateral elbow radiograph of a 26-year-old woman with synovial osteochondromatosis shows many ossified rounded and stippled loose bodies around the elbow joint.

joint cavity. In phase three, the intrasynovial disease is inactive, and there are multiple free osteochondral bodies.⁽³⁾

Features usually seen on radiographs include a soft tissue mass related to a joint, which is caused by a mixture of non-mineralised cartilaginous nodules, hyperplastic synovium, and an associated joint effusion.⁽²⁾ In addition, in 70%–95% of cases, multiple ossified nodules are seen within the joint space.⁽²⁾ These usually appear smooth and oval-shaped, with the finding of juxta-articular ossified nodules being a typical radiographical feature.⁽⁴⁾ Osteophytes, bone erosions (Fig. 7), juxta-articular osteopenia and joint space narrowing may also be seen.⁽⁴⁾ Computed tomography (CT) is useful for detection of the ossified and non-ossified masses seen in SOC, particularly if

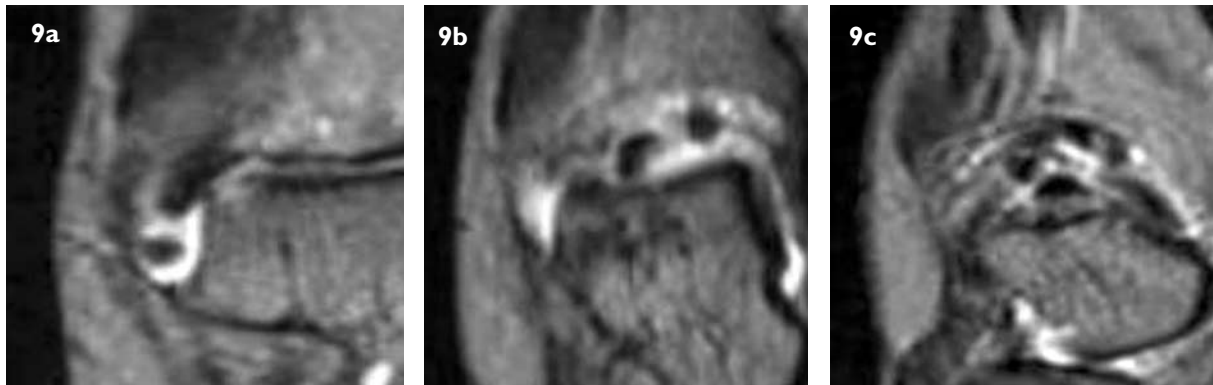


Fig. 9 (a-c) Coronal T2-W MR images of the right ankle of a 49-year-old woman, taken from mid-joint to posterior, show a joint effusion as well as multiple hypointense round lesions at the posterior and lateral aspects of the ankle joint, consistent with synovial osteochondromatosis.

the radiographs are equivocal. CT is able to show the typical intra-articular location of multiple rounded loose bodies (Fig. 8). CT can also demonstrate periarticular erosions which may indicate a chronic course of the disease.⁽²⁾

The MR imaging appearances of SOC depend on the composition of the cartilaginous loose bodies and degree of synovitis. Purely cartilaginous loose bodies are T1-hypointense and T2-hyperintense. The intra-articular bodies that are ossified typically show predominantly low signal intensity on all pulse sequences.⁽²⁾ In mature ossified loose bodies, fatty marrow may be seen in the centre of the loose bodies. The presence of joint effusion helps outline the loose bodies (Fig. 9). Intravenous contrast injection helps show any synovitis, the degree of synovial hyperplasia, and also helps differentiate joint effusion from the inflamed synovium. MR imaging is particularly useful in cases where the unossified bodies are not seen on radiographs. MR imaging depicts any also show bone erosions and delineate the intra-articular location of the loose bodies.⁽⁵⁾ MR imaging may also show synovial masses, with or without the associated intra-articular loose bodies.⁽⁶⁾ Synovial masses have a high signal intensity on T2-weighted images, while mineralisation within these synovial masses may appear as areas of signal void.

Patients with SOC that are asymptomatic do not require treatment. Symptomatic patients may undergo arthroscopic or surgical removal of the intra-articular loose bodies, and excision of the proliferating or metaplastic synovium. Because post-surgical recurrence of disease occurs frequently, total synovectomy is the preferred treatment for this condition.⁽⁴⁾

ACKNOWLEDGEMENT

We thank Ms Elizabeth Goh for taking the operative photographs (Figs 3a-c).

ABSTRACT

A 37-year-old Indian man presented with a two-year history of right hip pain. Radiographs showed small faint dense nodules at the inferomedial aspect of the right hip joint. Diagnosis of synovial osteochondromatosis was made on MR imaging, where multiple ossified loose bodies surrounded by a joint effusion, as well as enhancing synovium, were seen. Synovectomy and removal of 31 loose bodies were performed, and the diagnosis was confirmed histologically. The clinical manifestations and imaging features of synovial osteochondromatosis are discussed.

Keywords: intra-articular loose bodies, synovial metaplasia, synovial osteochondromatosis, synovitis

Singapore Med J 2008;49(5):430-434

REFERENCES

1. Monu J U V, Oka M. Synovial osteochondromatosis. EMedicine. Available at: www.emedicine.com/radio/topic667.htm. Last updated June 21, 2007. Accessed September 4, 2007.
2. Ryan RS, Harris AC, O'Connell JX, Munk PL. Synovial osteochondromatosis: the spectrum of imaging findings. *Australas Radiol* 2005; 49:95-100.
3. Milgram JW. Synovial osteochondromatosis: a histopathological study of thirty cases. *J Bone Joint Surg AM* 1977; 59:792-801.
4. Annunziata C, Christoforetti II JJ. Synovial osteochondromatosis. EMedicine. Available at: www.emedicine.com/orthoped/topic447.htm. Last updated December 1, 2006. Accessed September 4, 2007.
5. Kim SH, Hong SJ, Park JS, et al. Idiopathic synovial osteochondromatosis of the hip: radiographic and MR appearances in 15 patients. *Korean J Radiol* 2002; 3:254-9.
6. Narvaez JA, Narvaez J, Ortega R, et al. Hypointense synovial lesions on T2-weighted images: differential diagnosis with pathologic correlation. *Am J Roentgenol* 2003; 181:761-9.

SINGAPORE MEDICAL COUNCIL CATEGORY 3B CME PROGRAMME
Multiple Choice Questions (Code SMJ 200805B)

- | | True | False |
|---|--------------------------|--------------------------|
| Question 1. The following statements regarding synovial osteochondromatosis are true: | | |
| (a) It is a highly malignant lesion. | <input type="checkbox"/> | <input type="checkbox"/> |
| (b) Numerous cartilaginous nodules form in the synovium. | <input type="checkbox"/> | <input type="checkbox"/> |
| (c) The disease presents at birth and regresses by puberty. | <input type="checkbox"/> | <input type="checkbox"/> |
| (d) The secondary form may be associated with osteoarthritis. | <input type="checkbox"/> | <input type="checkbox"/> |
|
Question 2. Patients with synovial osteochondromatosis may present with: | | |
| (a) Joint pain. | <input type="checkbox"/> | <input type="checkbox"/> |
| (b) Limitation of joint movement. | <input type="checkbox"/> | <input type="checkbox"/> |
| (c) Haemorrhagic joint effusion. | <input type="checkbox"/> | <input type="checkbox"/> |
| (d) Cranial nerve palsy. | <input type="checkbox"/> | <input type="checkbox"/> |
|
Question 3. Regarding the imaging features of synovial osteochondromatosis: | | |
| (a) Multiple ossified nodules are typically seen. | <input type="checkbox"/> | <input type="checkbox"/> |
| (b) Presence of a large intramuscular mass at the mid-shaft of a long bone is a characteristic finding. | <input type="checkbox"/> | <input type="checkbox"/> |
| (c) Periarticular erosions are never seen. | <input type="checkbox"/> | <input type="checkbox"/> |
| (d) Joint effusion may be present. | <input type="checkbox"/> | <input type="checkbox"/> |
|
Question 4. Regarding magnetic resonance imaging of synovial osteochondromatosis: | | |
| (a) Appearances of the loose bodies depend on whether they are ossified. | <input type="checkbox"/> | <input type="checkbox"/> |
| (b) Ossified loose bodies have low signal intensity on both T1- and T2-weighted sequences. | <input type="checkbox"/> | <input type="checkbox"/> |
| (c) Synovitis is difficult to diagnose. | <input type="checkbox"/> | <input type="checkbox"/> |
| (d) Synovial masses may sometimes be seen. | <input type="checkbox"/> | <input type="checkbox"/> |
|
Question 5. In the management of patients with synovial osteochondromatosis: | | |
| (a) All patients, whether symptomatic or not, require urgent surgery. | <input type="checkbox"/> | <input type="checkbox"/> |
| (b) The intra-articular loose bodies may be removed arthroscopically. | <input type="checkbox"/> | <input type="checkbox"/> |
| (c) There is no role for total synovectomy. | <input type="checkbox"/> | <input type="checkbox"/> |
| (d) Post-surgical recurrence may occur. | <input type="checkbox"/> | <input type="checkbox"/> |

Doctor's particulars:

Name in full: _____

MCR number: _____ Specialty: _____

Email address: _____

SUBMISSION INSTRUCTIONS:

(1) Log on at the SMJ website: <http://www.sma.org.sg/cme/smj> and select the appropriate set of questions. (2) Select your answers and provide your name, email address and MCR number. Click on "Submit answers" to submit.

RESULTS:

(1) Answers will be published in the SMJ July 2008 issue. (2) The MCR numbers of successful candidates will be posted online at www.sma.org.sg/cme/smj by 15 July 2008. (3) All online submissions will receive an automatic email acknowledgment. (4) Passing mark is 60%. No mark will be deducted for incorrect answers. (5) The SMJ editorial office will submit the list of successful candidates to the Singapore Medical Council.

Deadline for submission: (May 2008 SMJ 3B CME programme): 12 noon, 25 June 2008.