

# Diagnostic laparoscopy in the evaluation of right lower abdominal pain: a one-year audit

Lim G H, Shabbir A, So J B Y

## ABSTRACT

**Introduction:** Acute appendicitis is the commonest cause for right lower abdominal pain. Clinical features, laboratory and imaging investigations are either not very sensitive or specific, and neither is therapeutic. We aimed to define the role of diagnostic laparoscopy in patients with right lower abdominal pain.

**Methods:** Data was collected retrospectively from January 1, 2005 to December 31, 2005. Patients admitted to the Emergency Department and subsequently transferred to the Department of Surgery, National University Hospital, Singapore, with right lower abdominal pain and who eventually underwent diagnostic laparoscopy were evaluated.

**Results:** 691 patients with right lower abdominal pain were admitted with suspected diagnosis of appendicitis. Diagnostic laparoscopy was undertaken in 103 patients aged 17–71 years old. Of the 83 females, 78 (94 percent) were premenopausal. Histology-proven acute appendicitis was diagnosed in 78 (75.7 percent) patients. Interestingly, within this group, 25.6 percent had other concomitant pathologies found on laparoscopy. 25 patients had a normal appendix; gynaecological causes accounted for pain in 15 of these 25 (60 percent) cases. In four (3.9 percent) patients, no pathology was found. Complication rate was 1.9 percent, which included ileus in two patients. In 32 (31.1 percent) patients, diagnostic laparoscopy altered the management plan, requiring either intervention or care by a subspecialty.

**Conclusion:** Diagnostic laparoscopy is useful in evaluating patients with right lower abdominal pain, especially in those with equivocal signs of acute appendicitis. It also has the additional benefit of being therapeutic. Premenopausal women benefit the most from this procedure.

**Keywords:** acute appendicitis, diagnostic laparoscopy, laparoscopic surgery, right lower abdominal pain

*Singapore Med J 2008;49(6):451-453*

## INTRODUCTION

Right lower abdominal pain often presents as a diagnostic problem to the clinician. Causes most commonly include appendicitis, gynaecological causes in females, and colonic pathology such as diverticulitis. Though radiological investigations could diagnose the cause of right lower abdominal pain in some cases, they are not therapeutic. Diagnostic laparoscopy, though invasive, can be both diagnostic and therapeutic. We conducted a retrospective study to define the role of diagnostic laparoscopy in evaluating right lower abdominal pain especially in patients with suspected appendicitis.

## METHODS

Data was collected retrospectively from January 1, 2005 to December 31, 2005. Patients admitted to the Emergency Department and subsequently transferred to the Department of Surgery, National University Hospital, Singapore, with right lower abdominal pain and who eventually underwent diagnostic laparoscopy, were evaluated. Exclusion criteria included patients with right lower abdominal pain admitted to the gynaecological or urology department, paediatric patients and patients with a previously-known cause of right lower abdominal pain such as adhesion colic. Patients with previous appendectomy, planned laparoscopic appendectomy and abdominal pain secondary to trauma were also excluded.

Diagnostic laparoscopy was undertaken by surgical registrars and consultants using the open Hasson technique with a 10-mm trocar being placed at the periumbilical area. A 0° or 30° telescope, depending on the surgeon's preference, was then inserted. Based on the laparoscopic findings, other ports may be inserted to facilitate further examination and for therapeutic purposes. For laparoscopic appendectomy, for example, two other 5-mm ports were usually inserted in the suprapubic and left iliac fossa region. Outcomes studied included demographics

Department of  
Surgery,  
National University  
Hospital,  
5 Lower Kent Ridge  
Road,  
Singapore 119074

Lim GH, MMed,  
MRCSE  
Registrar

Shabbir A, MMed,  
FRCS, FAMS  
Associate Consultant

So JBY, MBChB,  
FRCSE, FAMS  
Senior Consultant  
and Associate  
Professor

Correspondence to:  
Dr Lim Geok Hoon  
Tel: (65) 9639 2353  
Fax: (65) 6777 8427  
Email: ghlimsg@  
yahoo.com.sg

**Table I. Patients' demographics.**

Age (years)	No. of patients	
	Male	Female
17–20	2	9
21–30	5	29
31–40	8	28
41–50	3	12
51–60	1	4
61–70	1	0
> 70	0	1
Total	20	83

**Table II. Laparoscopic findings.**

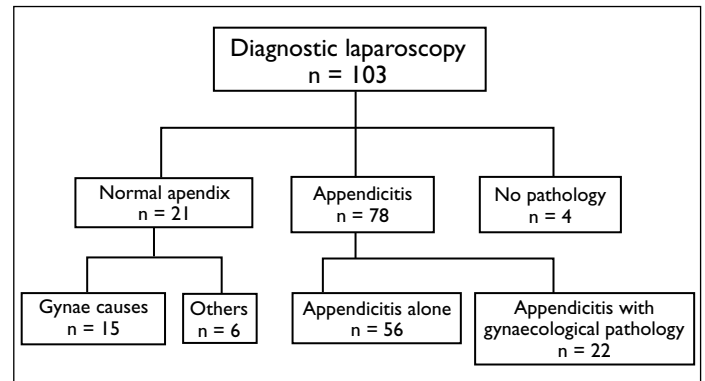
Concomitant pathologies	No. patients with normal appendix	No. patients with abnormal appendix
Fibroid	1	3
Retrograde menses	2	2
Ovarian cyst	4	12
Endometriosis	6	0
Pelvic inflammatory disease	2	3
Diverticulitis	4	0
Adhesions	2	0
Total	21	20

of patients undergoing diagnostic laparoscopy, including the sex and age of these patients. The operative findings of these patients were then compared with the clinical diagnosis and any discrepancies noted, including the resultant change in management secondary to diagnostic laparoscopy. The complication rates and conversion rates of diagnostic laparoscopies were recorded.

## RESULTS

During the study period, 691 patients with right lower abdominal pain, all with a possible diagnosis of appendicitis, were included. Of these patients, three and two patients underwent a laparotomy for colonic and complicated appendiceal pathology, respectively. 335 patients received conservative management with resolution of abdominal pain. 239 patients underwent open appendectomy and nine patients underwent planned laparoscopic appendectomy after computed tomography (CT) findings of acute appendicitis. 103 patients underwent diagnostic laparoscopy for evaluation of right lower abdominal pain. Diagnostic laparoscopy was undertaken in patients aged 17–71 years, with a median age of 33 years. Of the 83 females, 78 (94%) were premenopausal (Table I).

Clinical diagnosis of suspected appendicitis correlated with operative findings in 78 (75.7%) patients, (Fig. 1). Of these 78 patients, 56 and 22 patients had inflamed and complicated suppurative appendicitis, respectively. Two patients with complicated suppurative appendicitis also developed postoperative ileus which made the complication rate of diagnostic laparoscopy 1.9%. Interestingly, among patients with appendicitis, 25.6%

**Fig. 1** Algorithm shows the distribution of patients.

had other concomitant pathologies found on laparoscopy, which included mainly gynaecological causes such as fibroids, ovarian cysts, inflamed fallopian tubes and retrograde menses.

25 patients had a normal appendix, including four patients with no pathology found; gynaecological causes accounted for pain in 15 of these 25 patients (60%) and of these, 6 (40%) were from endometriosis alone. Other causes included pelvic inflammatory disease (13.3%), ovarian cysts (26.7%), retrograde menses (13.3%) and fibroid (6.7%) (Table II). Nongynaecological causes included diverticulitis and adhesions in four and two patients, respectively. In four patients (3.9%), diagnostic laparoscopy found no pathology but the appendix was removed nonetheless. The normal-looking appendix was left intact in eight out of 25 patients; these cases all had another cause accounting for their right lower abdominal pain.

Eight (7.8%) patients required conversion to open surgery. The reasons included an appendiceal mass, a stuck-down and friable appendix with a large amount of frank pus, or a perforation at the appendix base. In 32 (31.1%) patients, diagnostic laparoscopy altered the management plan, requiring either intervention or care by a subspecialty which could be intraoperative or at an outpatient setting.

## DISCUSSION

Diagnostic laparoscopy is an effective way of evaluating right lower abdominal pain, most commonly secondary to appendicitis in an acute setting.<sup>(1)</sup> Though imaging modalities, such as CT and ultrasonography, exist to aid in the detection of acute appendicitis, with reported CT sensitivity,<sup>(2)</sup> specificity, and accuracy to be up to 91%, 92%, and 91%, respectively, none of the investigations were therapeutic.

Diagnostic laparoscopy, though invasive, may be superior to transabdominal or transvaginal ultrasonography in the assessment of female adnexal organs when the

diagnosis is in doubt. In our study, eight out of 35 patients with gynaecological pathology underwent transvaginal ultrasonography of the pelvis, performed by ultrasonographers supervised by gynaecologists, prior to laparoscopy. In five of these eight patients, laparoscopy was more informative and could pick up small ovarian cysts, fibroids and hydrosalpinges which were missed on ultrasonography. The clinical management was altered due to the laparoscopic findings in two out of five patients.

Diagnostic laparoscopy allows direct visualisation of the intra-abdominal organs with low morbidity and may find unexpected concomitant pathologies, especially in premenopausal women, which may alter subsequent management (up to 31%) in our study. Laparoscopy, in particular, has been shown to be useful in childbearing women presenting with right lower abdominal pain. Larsson et al prospectively randomised 110 women of childbearing age with right lower abdominal pain and suspected appendicitis into open or laparoscopic appendectomy. They found that among the women with a normal appendix, a gynaecological diagnosis was found in 73% after laparoscopy, as compared with 17% after open surgery.<sup>(3)</sup>

Is it possible then, that diagnostic laparoscopy may lead to misdiagnosis and overtreatment of possibly clinically-asymptomatic gynaecological pathology? In our study, 20 patients had a concomitant histologically-proven inflamed appendix and a gynaecological pathology which included ovarian cysts in 12 patients, pelvic inflammatory diseases in three patients, fibroids in three patients, and retrograde menses in two patients. Of these patients, 13 patients were referred to the gynaecologist for further management and all of them received conservative treatment. The significance of certain conditions, such as ovarian cyst and fibroid, also contributing to right lower abdominal pain in this subgroup of patients with concomitant pathology is debatable.

On the contrary, the role of diagnostic laparoscopy in males with right lower abdominal pain and suspected appendicitis is controversial. A comparative randomised study in 100 males with suspected appendicitis showed no significant advantages of laparoscopic appendectomy over open appendectomy. Both groups had comparable postoperative recovery of bowel function and length of hospital stay.<sup>(4)</sup> This was supported by another prospective randomised study by Mutter et al, and they recommended that the use of laparoscopy be limited to men with atypical

pain of uncertain diagnosis and in obese patients.<sup>(5)</sup> However, Cox et al argued that laparoscopic compared to open appendectomy could allow a more rapid recovery to normal activities in men.<sup>(6)</sup>

Based on previous studies<sup>(1,3)</sup> which showed that women of childbearing age, with right lower abdominal pain, had most to gain from diagnostic laparoscopy, coupled with the intention to treat, there was selection bias in our study, where we tended to include women of childbearing age into the laparoscopic group, while men usually underwent open appendectomy. Women with equivocal signs were also more likely to undergo laparoscopic than open appendectomy. In addition, though our institution has the laparoscopic facilities available 24 hours a day, the laparoscopic experience of some of our junior surgeons may be limited, hence resulting in an open procedure after office hours. This finding correlated with a study by Horstmann et al which showed that the laparoscopic experience of the surgeons is one of the factors which influences decision-making between a laparoscopic versus open procedure.<sup>(7)</sup> Ideally, the study should have been carried over a longer period of time to increase the number of subjects.

In conclusion, diagnostic laparoscopy is a useful tool in evaluating patients with right lower abdominal pain, especially those with equivocal signs of acute appendicitis. It has the added benefit of being therapeutic. Women of childbearing age gain most from the procedure.

## REFERENCES

1. Golash V, Willson PD. Early laparoscopy as a routine procedure in the management of acute abdominal pain: a review of 1,320 patients. *Surg Endosc* 2005; 19:882-5.
2. Hershko DD, Sroka G, Bahouth H, et al. The role of selective computed tomography in the diagnosis and management of suspected acute appendicitis. *Am Surg* 2002; 68:1003-7.
3. Larsson PG, Henriksson G, Olsson M, et al. Laparoscopy reduces unnecessary appendectomies and improves diagnosis in fertile women. A randomized study. *Surg Endosc* 2001; 15:200-2.
4. Helmy MA. A comparative study between laparoscopic versus open appendectomy in men. *J Egypt Soc Parasitol* 2001; 31:555-62.
5. Mutter D, Vix M, Bui A, et al. Laparoscopy not recommended for routine appendectomy in men: results of a prospective randomized study. *Surgery* 1996; 120:71-4.
6. Cox MR, McCall JL, Toouli J, et al. Prospective randomized comparison of open versus laparoscopic appendectomy in men. *World J Surg* 1996; 20:263-6.
7. Horstmann R, Tiwisina C, Classen C, Palmes D, Gilleszen A. [Laparoscopic versus open appendectomy: which factors influence the decision between the surgical techniques?]. *Zentralbl Chir* 2005; 130:48-54. German.