

# Knee locking secondary to osteochondral fracture of the patella: an unusual presentation

Goh S K, Koh J S B, Tan M H

## ABSTRACT

Acute locking is a sign of internal derangement of the knee and is an orthopaedic surgical emergency. Differential diagnoses of this condition are torn meniscus, intra-articular loose bodies and torn anterior cruciate ligament. We present a 15-year-old schoolboy who developed acute locking of the knee during dancing. Arthroscopy revealed that he had sustained an osteochondral fracture of the patella and the loose fragment from it caused locking of the knee. That this was not pseudo-locking was confirmed by examination of the knee under anaesthesia. Locking of the knee by a loose osteochondral fragment following acute dislocation of the patella, though rare, should be considered as a possible cause of true locking.

**Keywords:** knee injuries, knee locking, osteochondral fracture, patellar dislocation

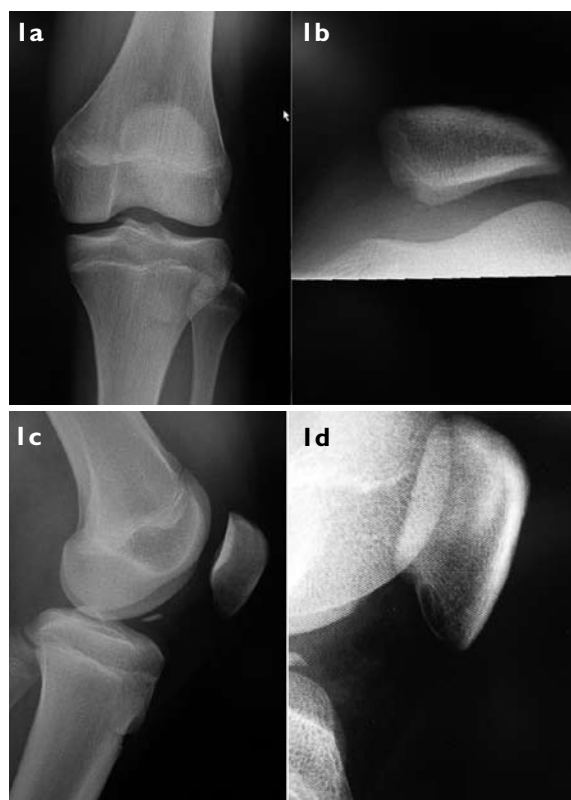*Singapore Med J 2008;49(6):505-506*

## INTRODUCTION

Acute post-traumatic locking of the knee is commonly caused by a torn medial meniscus, and less commonly by osteocartilaginous loose body or osteochondral fragment. An osteochondral fragment from the knee occurs after an osteochondral fracture of intra-articular structures of the knee, e.g. the femoral condyles or the patella. Though osteochondral fractures of patella following acute traumatic dislocations of patella are common, locking of the knee from it has never been reported. We report a true locking of the knee caused by an osteochondral fragment following a probable acute traumatic dislocation of patella.

## CASE REPORT

A 15-year-old schoolboy presented to our clinic with sudden onset of locking of his left knee. One day prior to the presentation, the patient had been practising dancing in school when he thought he had "twisted" his left knee, which promptly gave way and caused him to fall on the stage. Immediately after the fall, he found his left knee to be swollen and locked in extension; this remained so until he was seen in the clinic.



**Fig. 1** (a) Frontal, (b) skyline, (c) lateral and (d) close-up lateral radiographs show an oval loose body located in the anterior intercondylar area. There is also a defect in the medial facet of the patella.

The patient was brought into the consultation room on a wheelchair. On examination, his left knee was swollen, tense and held in full extension. There was diffuse tenderness in the knee joint. The patella was not displaced on palpation. Flexion of his left knee was not possible beyond 20° due to intolerable pain. Clinically, his Q-angles were within normal range bilaterally. On the nine-point Beighton score, he scored seven, which suggested that his ligaments were generally lax.

Radiographs of his knee (Figs. 1a–c) revealed a small bony fragment lodged in the joint just above the medial tibial spine. There was otherwise no other obvious fracture of the tibia or femur. The differential diagnoses at that stage were medial tibial spine avulsion fracture and medial meniscus tear. An urgent arthroscopy of the knee was arranged for the following day.

Under general anaesthesia, clinical examination confirmed that the patient had true locking of the knee.

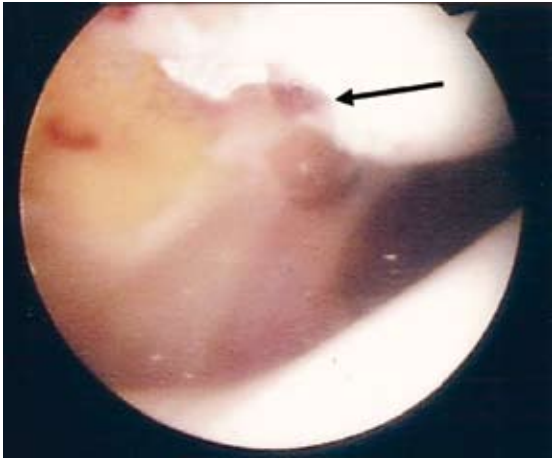
Department of  
Orthopaedic  
Surgery,  
Singapore General  
Hospital,  
Outram Road,  
Singapore 169608

Goh SK, MA,  
MBBCh, MRCS  
Registrar

Koh JSB, MBBS,  
FRCS  
Consultant

Tan MH, MBBS,  
FRCS  
Senior Consultant  
and Director of  
Musculoskeletal  
Tumour Service

Correspondence to:  
Dr Goh Seo Kiat  
Tel: (65) 6321 4040  
Fax: (65) 6224 8100  
Email: seokiat.goh@  
cantab.net



**Fig. 2** Arthroscopic photograph shows a defect in the infero-medial facet of the patella (arrow).

Standard arthroscopy revealed haemarthrosis in the knee joint. The anterior cruciate ligament was intact. There was no observable injury to his menisci and posterior cruciate ligament. His tibial and femoral condylar cartilages were normal. A 2-cm osteochondral fragment was found floating in the knee joint, and this was retrieved. It was also noted that the patient had an osteochondral ulcer in the posterior aspect of the infero-medial pole of the patella (Fig. 2). In retrospect, it could be seen that there was a cortical defect of the patella on the radiograph (Fig. 1d). Postoperatively, the patient made an uneventful recovery. At the last follow-up in the outpatient clinic six months after the accident, the patient remained well and had since gone back to dancing in school.

## DISCUSSION

Our patient had sustained an osteochondral fracture of the patella, which subsequently impinged upon the knee joint, leading to acute locking of the knee. Based on the radiographic (Fig. 1) and arthroscopic (Fig. 2) findings, the origin of the osteochondral fragment was the infero-medial facet of the patella. The observation that patellar osteochondral fracture is associated with patellar dislocation was first made by Kroner<sup>(1)</sup> in 1905. It was subsequently reported that the most common area of patellar osteochondral fracture in these patients was the medial facet of the patella.<sup>(2)</sup> The propensity for this area to be fractured was thought to be related to the high tangential shearing forces between the medial patellar surface and the lateral femoral condyle during the lateral dislocation, and subsequent relocation of the patella.

The lack of evidence from the presenting history and clinical examination notwithstanding, we believe that our patient did sustain an acute lateral dislocation of his patella, which was almost instantaneously reduced during, or soon after, the fall. Many authors have emphasised the importance of the medial patellofemoral ligament in providing the primary restraint to the lateral displacement of the patellar bone.<sup>(3)</sup> Isolated release of this ligament in cadaveric knees had been known to produce 50% increase in lateral displacement of the patella on test loading. The Q-angle, vastus medialis obliquus and the congruency of the patellofemoral joint are the other important factors of patellar stability.<sup>(4)</sup>

When the knee is in full extension, the patella lays superolateral to the femoral sulcus. On flexing the knee, engagement between the patella and the trochlea occurs from about 10° to 30°. In cadaveric studies, it had been shown that lateral displacement of the patella was greater than medial displacement at all angles of knee movement.<sup>(5)</sup> Hence, patellar displacement typically occurs laterally, and at low angles of flexion, when there is little or no engagement between the patella and the trochlea. During sports (and dancing), it is not uncommon to have the knee in a position of internal rotation with the knee in valgus, on a planted foot. This produces a significant lateral force on the patella and is the position of peril with regard to the lateral stability of the patella.

It is known that patellar osteochondral injuries could be found in as many as 95% of patients with acute dislocation of the patella.<sup>(2)</sup> It has, however, never been reported that such osteochondral fracture fragments could result in acute knee locking, as was illustrated in this case. Arthroscopy and retrieval of the offending fragment should result in good functional recovery of the knee.

## REFERENCES

1. Rorabeck CH, Bobechko WP. Acute dislocation of the patella with osteochondral fracture: a review of eighteen cases. *J Bone Joint Surg (Br)*, 1976; 58:237-40.
2. Nomura E, Inoue M, Kurimura M. Chondral and osteochondral injuries associated with acute patellar dislocation. *Arthroscopy* 2003; 19:717-21.
3. Vainionpää S, Laasonen E, Päätiälä H, Rusanen M, Rokkannen P. Acute dislocation of the patella. Clinical, radiographic and operative findings in 64 consecutive cases. *Acta Orthop Scand* 1986; 57:331-3.
4. Arendt EA, Fithian DC, Cohen E. Current concepts of lateral patella dislocation. *Clin Sports Med* 2002; 21:499-519.
5. Stanitski CL. Patellofemoral mechanism. In: DeLee JC, Drez D, Miller M, eds. *DeLee & Drez's Orthopaedic Sports Medicine*. 2nd ed. Philadelphia: WB Saunders, 2003:1815-40.