

Ruptured superficial femoral artery aneurysm treated by simple ligation

Dighe S, Thomas P

ABSTRACT

A 79-year-old man, with a background of peripheral vascular disease, presented to the emergency department with a sudden increase in the size of his swelling in the right thigh, indicating rupture of his right superficial femoral artery aneurysm. His past medical history included having had a left femoropopliteal bypass (1986), abdominal aortic aneurysm repair (1991), repair of false aneurysm on the right (1992) and repair of left common femoral artery aneurysm (1995). On surgical exploration, four contiguous aneurysms in the right superficial femoral artery were identified, which measured around 25 cm in total length. After achieving control of the aneurysm, it was noted that the popliteal artery was unsuitable for anastomosis. However, the leg was still adequately perfused via collaterals in spite of the ligation, so nothing further was done. The patient was put on a heparin infusion postoperation, and had an uneventful recovery with a viable limb on discharge. It is a useful reminder that ligation can still be an option in vascular emergencies in some situations.

Keywords: aneurysm rupture, aneurysm simple ligation, atherosclerosis, superficial femoral artery

Singapore Med J 2008;49(6):e151-e152

INTRODUCTION

A true arterial aneurysm is a result of the degeneration of the arterial wall due to atherosclerosis, leading to its dilatation. With the increase in life expectancy and old age, the incidence of aneurysmal disease due to atherosclerosis is rising. As atherosclerosis is a systemic disease, there is a potential for any artery in the body to develop an aneurysmal dilatation. The most commonly affected artery is the abdominal aorta. Isolated superficial femoral artery (SFA) aneurysm is a rare entity with only about 43 cases reported to date.^(1,2) The reason for this may be the excellent muscular support and minimal bending stress enjoyed by this artery. There is a general tendency for the central artery aneurysm to rupture, while the peripheral artery aneurysms are complicated by thrombosis and embolism. We report a patient with an extensive past history of aneurysmal disease in the peripheral arteries as well as the abdominal

aorta, and who subsequently presented with a rupture of his aneurysm in the right SFA. To date, the extensive array of aneurysmal disease in a single patient has not been previously documented.

CASE REPORT

A 79-year-old man, with a background of peripheral vascular disease, presented to the emergency department with a sudden increase in the size of his swelling in the right thigh. His past medical history included having had a left femoropopliteal bypass (1986), abdominal aortic aneurysm repair (1991), repair of false aneurysm on the right (1992) and repair of left common femoral artery aneurysm (1995). His other medical history included congestive cardiac failure, paroxysmal atrial fibrillation, a ventricular thrombus, iatrogenic hypothyroidism (secondary to amiodarone), hypertension, significant ischaemic cardiomyopathy, angina and chronic renal failure.

He then subsequently developed a right SFA in 1995 and was regularly reviewed at six monthly intervals since 1995. Doppler imaging in 1998 revealed a 6-cm aneurysm of the right SFA with a decreased flow (0.45 m/s) at a site distal to the initial repair. Over two years, the aneurysm expanded longitudinally (7 cm) with four loculated segments. The last scan on the left leg (2001) showed a further increase in aneurysmal dilatations measuring 5 cm, 4.7 cm, 4.7 cm and 3.8 cm in diameter, respectively, with the distal aneurysm occluded with a thrombus. However, his foot was clinically viable with good capillary refill time and ankle-brachial pressure index readings of 0.90 and 0.88. In view of his extensive atherosclerotic disease, absence of good distal vessels to repair and very high-risk comorbid condition, he was treated conservatively. He was then lost to follow-up, until he presented as an emergency.

On this admission, the patient presented with an eight-hour history of an increasingly painful, pulsating swelling over his right anteromedial thigh, over the site of the known aneurysm. On examination, the patient was haemodynamically stable with haemoglobin of 13.6 g/dL. There was a 15 cm × 10 cm pulsating mass over the antero-medial aspect of his right thigh with an audible bruit and bruising over the swelling. His femoral, popliteal pulses and distal pulses were audible on handheld Doppler imaging. He was on long-term anticoagulation medication with an international normalised ratio of 1.6. In spite of the rupture, he had

**Surgical Services,
St Helier University
Hospital,
Wrythe Lane,
Carshalton,
Surrey SM5 1AA,
United Kingdom**

Dighe S, MS, DNB,
MRCS
Registrar

Thomas P, MS, FRCS
Consultant

Correspondence to:
Dr Shwetal Dighe
Tel: (44) 20 8726 7909
Mobile: (44) 079 0644
8674
Fax: (44) 20 8296 4751
Email: shwetal@
doctors.org.uk

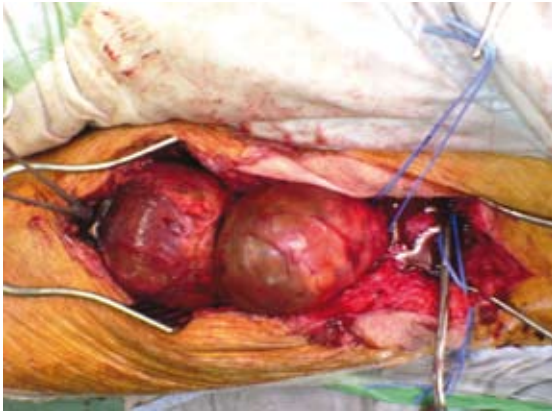

Fig. 1 Clinical photograph shows the superficial femoral artery aneurysm measuring 25 cm in length.

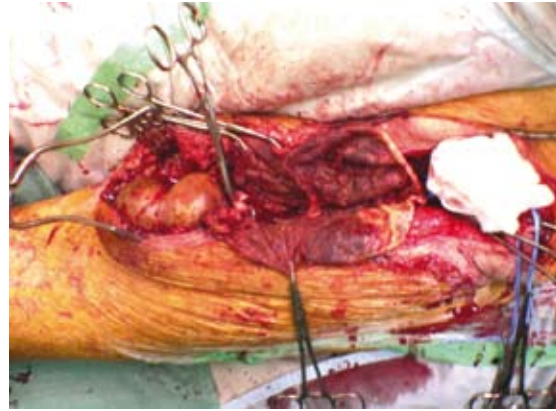


Fig. 2 Clinical photograph shows the aneurysm opened along its length.

a warm perfused limb with good capillary refill. As the risk of exsanguination haemorrhage was high, it was decided that the aneurysm should be explored.

A high inguinal approach was used and four contiguous aneurysms in the SFA were identified; these extended down into the Hunterian canal. The total length of the aneurysmal segment was around 25 cm (Fig. 1), which was the largest recorded so far. The aneurysm was opened all along its length (Fig. 2), the thrombus was evacuated and the ends were ligated. The popliteal artery was exposed at the medial aspect of the thigh but was found too diseased for reconstruction. As the limb was still viable, it was deemed safer to simply ligate the aneurysm and achieve haemostasis, with a plan for angiography if the limb became ischaemic. The patient was put on a heparin infusion postoperation. He had an uneventful recovery and had a viable limb on discharge.

DISCUSSION

Of all peripheral aneurysms, 55% are popliteal and only 3% are located in the thigh. The distribution of the latter is 80% in the common femoral, 15% in the superficial femoral, and 5% in the deep femoral arteries.⁽³⁾ Cutler and Darling first classified them in 1973 as Types 1 and 2, depending on its relationship to the femoral bifurcation. Femoral artery aneurysms are usually associated with abdominal artery aneurysms in 40% of cases and are bilaterally situated in around 18%–72% of cases. They are also associated with other peripheral aneurysms in 27%–50% of cases.⁽⁴⁾ Thus, all patients with these aneurysms should be screened at these other sites.

The natural history of these aneurysms is not very well known due to the rarity of the condition. However, it does affect the elderly age group. In 35% of cases, the initial presentation is with a complication such as rupture, 18% of cases present with thrombosis, and distal emboli are seen in 12%. Surprisingly, however, the limb is salvageable in 94% of cases.^(4,5) This is in contrast to the common femoral aneurysms, which have a 31% incidence of thrombosis, 3% incidence of distal emboli and only an 82% limb salvage rate.⁽⁵⁾

Surgical reconstruction is recommended for patients with aneurysms of the SFA that are 2.5 cm or greater in maximum diameter, and for complicated aneurysms of any size.⁽⁴⁾ Many operative procedures, like excision and vein graft prosthesis, Matas' endoaneurysmorrhaphy, ligation and autogenous bypass graft, and ligation alone, have been suggested. The preferred method appears to be ligation of the aneurysm, and an autologous venous graft or a polytetrafluoroethylene (PTFE) graft. Only three cases so far have documented treatment by ligation alone, without grafting, and all three have been cases reported before 1981. Recently, the trend has been towards reconstruction with a PTFE graft.^(5,6)

This patient was evaluated in the past for his SFA aneurysm and upon investigation, all his distal vessels were diseased with no vessel adequate for reconstruction. Thus, in long-standing aneurysms with no evidence of vascular compromise to the leg, simple ligation of the aneurysm can be an alternative mode of management to avoid complications of bypass surgery. Another interesting finding was that over the years, he suffered from all the three types of aneurysms (abdominal, common femoral and superficial femoral), and was successfully operated on all of them. Such an extensive spectrum of diseases has not been previously documented to date.

REFERENCES

- Honjo O, Yamada Y, Mima T, Kushida Y. Surgical treatment for an atherosclerotic aneurysm of the superficial femoral artery: report of a case. *Surg Today* 2004; 34:188-9.
- Pulcini G, Cimaschi D, Vinco A, et al. [Rupture of voluminous atherosclerotic superficial femoral artery aneurysm]. *Chir Ital* 2005; 57:661-7. Italian.
- Ormstad K, Solheim K. Ruptured aneurysm of the superficial femoral artery. *Scand J Thorac Cardiovasc Surg* 1975; 9:181-2.
- Dimakakos PB, Tsiligiris V, Kotsis T, Papadimitriou JD. Atherosclerotic aneurysms of the superficial femoral artery: report of two ruptured cases and review of the literature. *Vasc Med* 1998; 3:275-9.
- Rigdon EE, Monajjem N. Aneurysms of the superficial femoral artery: a report of two cases and review of the literature. *J Vasc Surg* 1992; 16:790-3.
- Siani A, Flaishman I, Napoli F, Schioppa A, Zaccaria A. Rupture of an isolated true superficial femoral artery aneurysm: case report. *G Chir* 2005; 26:215-7.