

Multiple variations of the right renal vessels

Nayak B S

ABSTRACT

Multiple variations of the right renal and testicular vessels were found during routine dissection in a 65-year-old male cadaver. The cadaver was healthy and did not have any other anomalies. The variations found were: presence of three right renal arteries, origin of the right inferior suprarenal artery from the middle right renal artery, two right renal veins, origin of the right testicular artery from the inferior right renal artery and the termination of the right testicular vein into the right renal vein. A sound knowledge of vascular variations in relation to the right kidney and right suprarenal gland is important in kidney transplantation and suprarenal surgery.

Keywords: renal artery variants, renal vascular variations, renal vein variants, testicular artery variants, testicular vein variants, vascular variations

Singapore Med J 2008;49(6):e153-e155

INTRODUCTION

Renal arteries are a pair of lateral branches from the abdominal aorta. Normally, each kidney receives one renal artery. The venous drainage of each kidney is through one renal vein, which drains the blood from the kidney into the inferior vena cava. The left renal vein also receives left suprarenal and left gonadal veins, in addition to that coming from the kidney. The gonadal (testicular or ovarian) arteries are the lateral branches of abdominal aorta. Normally, each gonad receives one gonadal artery. Gonadal veins of the two sides terminate in different vessels. The right gonadal vein is a tributary of the inferior vena cava and the left gonadal vein is a tributary of the left renal vein. The right inferior suprarenal artery is normally a branch of the right renal artery. We observed variations of the right renal, right inferior suprarenal and gonadal vessels. Knowledge of these variations is important for urologists, radiologists and surgeons in general. The objective of this case report is to bring awareness to clinicians about the variations in the renal vascular region. This report may also be useful to clinicians performing invasive techniques.

CASE REPORT

During a gross anatomy dissection of the abdomen of

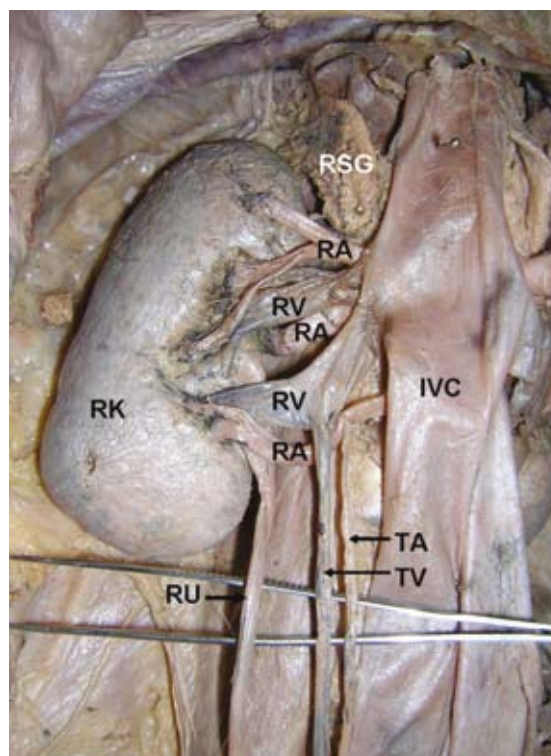


Fig. 1 Photograph taken during dissection shows the right renal and testicular vessels.

IVC: inferior vena cava; RK: right kidney; RA: right renal arteries; RV: right renal veins; TA: testicular artery; TV: testicular vein; RSG: right suprarenal gland; RU: right ureter.

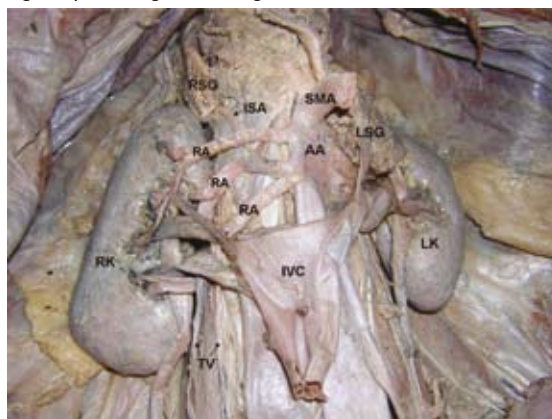


Fig.2 Photograph taken during dissection shows the right renal arteries and veins. The inferior vena cava is reflected downwards. SMA: superior mesenteric artery; RA: right renal arteries; ISA: right inferior suprarenal artery; AA: abdominal aorta; IVC: inferior vena cava; RSG: right suprarenal gland; LSG: left suprarenal gland; RK: right kidney; LK: left kidney; TV: right testicular vessels.

a 65-year-old male cadaver, we observed multiple variations in the right renal and testicular vessels (Figs. 1 & 2). The right kidney received three renal arteries, two of which took their origin from the lateral aspect and one from the anterior aspect of the

Department of
Anatomy,
Melaka Manipal
Medical College
(Manipal Campus),
International Centre
for Health Sciences,
Madhav Nagar,
Manipal,
Udupi District,
Karnataka 576104,
India

Nayak BS, MSc, PhD
Associate Professor

Correspondence to:
Dr Satheesha Nayak B
Tel: (91) 820 292 2519/
984 400 9059
Fax: (91) 820 257 1905
Email: nayaksathish@yahoo.com

abdominal aorta. The superior renal artery was divided into three branches, and the middle and inferior renal arteries were divided into two branches each before entering the kidney. Among these seven branches of the three renal arteries, two branches entered the kidney by piercing through its anterior surface and the other five entered through the hilum. The right inferior suprarenal artery originated from the middle right renal artery and reached the suprarenal gland by passing deep to the superior renal artery (Fig. 2). The inferior renal artery gave origin to the right testicular artery (Fig. 1). The right kidney had two renal veins of almost equal size, both of which terminated into the inferior vena cava. The lower among the two renal veins received the right testicular vein (Fig. 1). The renal, suprarenal and testicular vessels on the left side were normal.

DISCUSSION

The renal arteries arise from the aorta just below the level of origin of the superior mesenteric artery. The accessory renal arteries are seen frequently.⁽¹⁻³⁾ They enter the kidney either above or below the hilum. Their relations with the nearby structures can vary. Bayramoglu et al reported bilateral additional renal arteries originating from the abdominal aorta and an additional right renal vein accompanying the additional right renal artery.⁽⁴⁾ These anomalies were associated with unrotated kidneys with extrarenal calyces and pelvis. The abnormalities in the renal arteries are mainly due to the various developmental positions of kidney.⁽⁵⁾ The kidneys begin their development in the pelvic cavity and then ascend to their final position in the lumbar region. When the kidneys are situated in the pelvis, they are supplied by the branches of common iliac arteries. While the kidneys ascend to lumbar region, their arterial supply also shifts from common iliac artery to the abdominal aorta. Accessory renal arteries arise from the abdominal aorta either above or below the main renal artery and follow it to the hilum. It is important to be aware that accessory renal arteries are end arteries; therefore, if an accessory artery is damaged, the part of kidney supplied by it is likely to become ischaemic.

The suprarenal arteries are multiple in numbers. The superior suprarenal arteries usually arise as a number of branches from the inferior phrenic artery, the middle suprarenal artery from the abdominal aorta, and the inferior from the renal artery. Variations in the origin of these arteries have also been reported,⁽⁶⁻⁷⁾ with the middle suprarenal artery being the most variable among the three suprarenal arteries.⁽⁸⁾ The testicular arteries arise from the abdominal aorta just below the level of renal arteries. The variations are common in these arteries and have been reported. The testicular arteries

may vary at their origin. They may be absent; one or both arteries may arise from the renal artery, suprarenal artery or lumbar artery. They may arise from a common trunk, and may be two, three or four on one side.⁽⁹⁾

The renal veins are the tributaries of the inferior vena cava. The right renal vein receives blood only from the right kidney, whereas the left renal vein receives blood from the left suprarenal gland and left gonad, through the suprarenal and gonadal veins. Variations of renal veins are rare compared to the renal arteries. Variations of right renal veins are more common than left renal veins. Janschek et al reported cases of multiple renal veins. In their study, variations were more common on the right side (23%) than on the left (6.7%).⁽¹⁰⁾ Doubling of the right renal veins has been reported by Malcic-Gürbüz et al.⁽¹¹⁾ Senecail et al reported two uncommon anatomical variations of the left renal vein. They found a circum-aortic venous ring and a retro-aortic bifid left renal vein. The first anomaly resulted from the persistence of the embryonic renal venous collar. The second one was due to a particular pattern of left inferior vena cava.⁽¹²⁾ Malcic-Gürbüz et al reported the branching of the left renal vein. According to their report, the left renal vein divided into three branches and the upper branch among the three drained into the azygos vein, while the lower two branches drained into the inferior vena cava. In an extensive study on left renal vein variations by Satyapal et al, renal collars were found in 0.3%, retro-aortic vein in 0.5%, additional veins in 0.4%, and posterior primary tributary in 23.2% of cases.⁽¹³⁾

The right testicular vein is a tributary of the inferior vena cava. Variations of the right testicular vein are very rare. Asala et al have reported the termination of the testicular vein into the right renal vein.⁽¹⁴⁾

The variations which are reported here, have already been reported as individual cases of variations, but occurrence of variations of the renal, suprarenal, and testicular vessels in the same person have not yet been reported. In the present case, the right inferior suprarenal vein may get compressed by the superior renal artery. The presence of three renal arteries and two renal veins may compress the renal pelvis and result in hydronephrosis. The arterial variations, like any other anatomical variations, cannot be ignored during the surgical procedures of the abdomen. The awareness of these variations in the origin of the arteries in this region of hilum of the kidney, and para-aortic region, may be of utmost importance to urologists who perform nephron-preserving surgery, kidney transplantation, and the management of renal vascular hypertension. These variations can be demonstrated preoperatively by selective angiography. Knowledge of these variations may also provide safety guidelines for endovascular

procedures like therapeutic embolisation and angioplasties. Multiple vascular variations near the hilum of the kidney are present in seemingly normal patients and a sound knowledge of possible variations is very useful for radiologists, urologists and surgeons in general.

REFERENCES

1. Singh G, Ng YK, Bay BH. Bilateral accessory renal arteries associated with some anomalies of the ovarian arteries – a case study. *Clin Anat* 1998; 11:417-20.
2. Satyapal KS, Haffejee AA, Singh B, et al. Additional renal arteries: incidence and morphometry. *Surg Radiol Anat* 2001; 23:33-8.
3. Bordei P, Sapte E, Iliescu D. Double renal arteries originating from the aorta. *Surg Radiol Anat* 2004; 26:474-9.
4. Bayramoglu A, Demiryurek D, Erbil KM. Bilateral additional renal arteries and an additional right renal vein associated with unrotated kidneys. *Saudi Med J* 2003; 24:535-7.
5. Moore KL, Persaud TVN. *The Developing Human: Clinically Oriented Embryology*. 7th ed. Philadelphia: WB Saunders, 2002.
6. Brohi RA, Sargon MF, Yener N. High origin and unusual suprarenal branch of a testicular artery. *Surg Radiol Anat* 2001; 23:207-8.
7. Bordei P, St Antohe D, Sapte E, Iliescu D. Morphological aspects of the inferior suprarenal artery. *Surg Radiol Anat* 2003; 25:247-51.
8. Manso JC, DiDio LJ. Anatomical variations of the human suprarenal arteries. *Ann Anat* 2000; 182:483-8.
9. Bergman RA, Cassell MD, Sahinoglu K, Heidger PM Jr. Human doubled renal and testicular arteries. *Ann Anat* 1992; 174:313-5.
10. Janschek EC, Rothe AU, Hölzenbein TJ, et al. Anatomic basis of right renal vein extension for cadaveric kidney transplantation. *Urology* 2004; 63:660-4.
11. Malcic-Gürbüz J, Akalin A, Gümüşcü B, Cavdar S. Clinical implications of concomitant variations of the testicular, suprarenal and renal veins: a case report. *Ann Anat* 2002; 184:35-9.
12. Senecaïl B, Bobeuf J, Forlodou P, Nonent M. Two rare anomalies of the left renal vein. *Surg Radiol Anat* 2003; 25:465-7.
13. Satyapal KS, Kalideen JM, Haffejee AA, Singh B, Robbs JV. Left renal vein variations. *Surg Radiol Anat* 1999; 21:77-81.
14. Asala S, Chaudhary SC, Masumbuko-Kahamba N, Bidmos M. Anatomical variations in the human testicular blood vessels. *Ann Anat* 2001; 183:545-9.