

# C-reactive protein as an indicator of aqueductal gliosis and hydrocephaly in neonatal meningitis

Hemmati F, Pishva N

## ABSTRACT

**Serial C-reactive protein (CRP) measurements appear to be helpful in following clinical course and response to treatment of serious bacterial infections in neonates, such as meningitis, septicaemia and osteomyelitis. In previous studies, serial determination of serum CRP could detect potential complications of meningitis, such as subdural effusion, purulent arthritis and osteomyelitis, and secondary skin infection. We report an 11-day-old full-term male neonate with persistent positive CRP after treatment of bacterial meningitis, and who developed hydrocephaly at follow-up. We concluded that positive CRP was secondary to aqueduct gliosis; therefore monitoring of serum CRP levels in infants with bacterial meningitis represented useful information, not only in persistent or secondary infection, but also for destructive complications of meningitis.**

**Keywords: aqueduct gliosis, C-reactive protein, hydrocephaly, meningitis, neonatal diseases**

*Singapore Med J 2008;49(6):e163-e165*

## INTRODUCTION

The acute phase response to infection or trauma clinically is manifested by malaise, anorexia, fever, leucocytosis and hepatic production of acute-phase proteins (APRs). APRs are proteins produced by hepatocytes in response to inflammation. The inflammation may be secondary to infection, trauma, or other processes of cellular destruction.<sup>(1)</sup> There are many different APRs, including C-reactive protein (CRP), fibrinogen, C3 complement and  $\alpha_1$ -antitrypsin. Elevated APRs do not distinguish between infectious and noninfectious causes of inflammation.<sup>(1)</sup> Serial CRP measurements appear to be helpful in the follow-up of clinical course and response to treatment of serious bacterial infections in neonates, such as meningitis, septicaemia and osteomyelitis.<sup>(2,3)</sup>

Peltola et al<sup>(4)</sup> reported that serial determination of serum CRP detects potential complications of childhood purulent meningitis, such as subdural effusion, transient widening of the ventricles, purulent arthritis with osteomyelitis, and relapse of meningitis. Dias Leite et al prospectively studied 22 children with bacterial

meningitis to follow serial CRP in serum.<sup>(5)</sup> Patients with a complicated meningitis according to clinical evolution (n = 10) had CRP levels that showed either secondary elevation or remained high continuously. Clinical complications observed were relapse of fever, persistent fever, arthritis, ventriculomegaly, subdural effusion, subdural empyema, ataxia, acute otitis media and secondary skin infection. We describe a neonate with persistent high CRP after the treatment of bacterial meningitis. No other site of infection was detected but upon follow-up, the patient developed increased head circumference and hydrocephaly.

## CASE REPORT

An 11-day-old full-term male neonate was admitted for fever and six episodes of cyanosis, since four days and one day prior to admission, respectively. There was no history of maternal infection, chorioamnionitis or use of any medication. His birth weight was 3 kg (25th percentile based on CDC growth charts.) and his head circumference was 35.5 cm (25th–50th percentile). On physical examination, he was febrile with a temperature of 38.6°C axillary, pulse rate 160/min, respiratory rate 36/min and blood pressure 80 mmHg with pulse. He was alert. The anterior fontanelle was full and mildly bulged, the lungs were clear and cardiac examination was normal. Neurological examination showed normal suck, grasp and Moro reflexes. There was no hepatosplenomegaly and rash, and no sign of dehydration was detected. At the time of the physical examination, he had one episode of lip cyanosis and eye-staring lasting about 1.5 min. During this episode, he had tachycardia, and then he became lethargic.

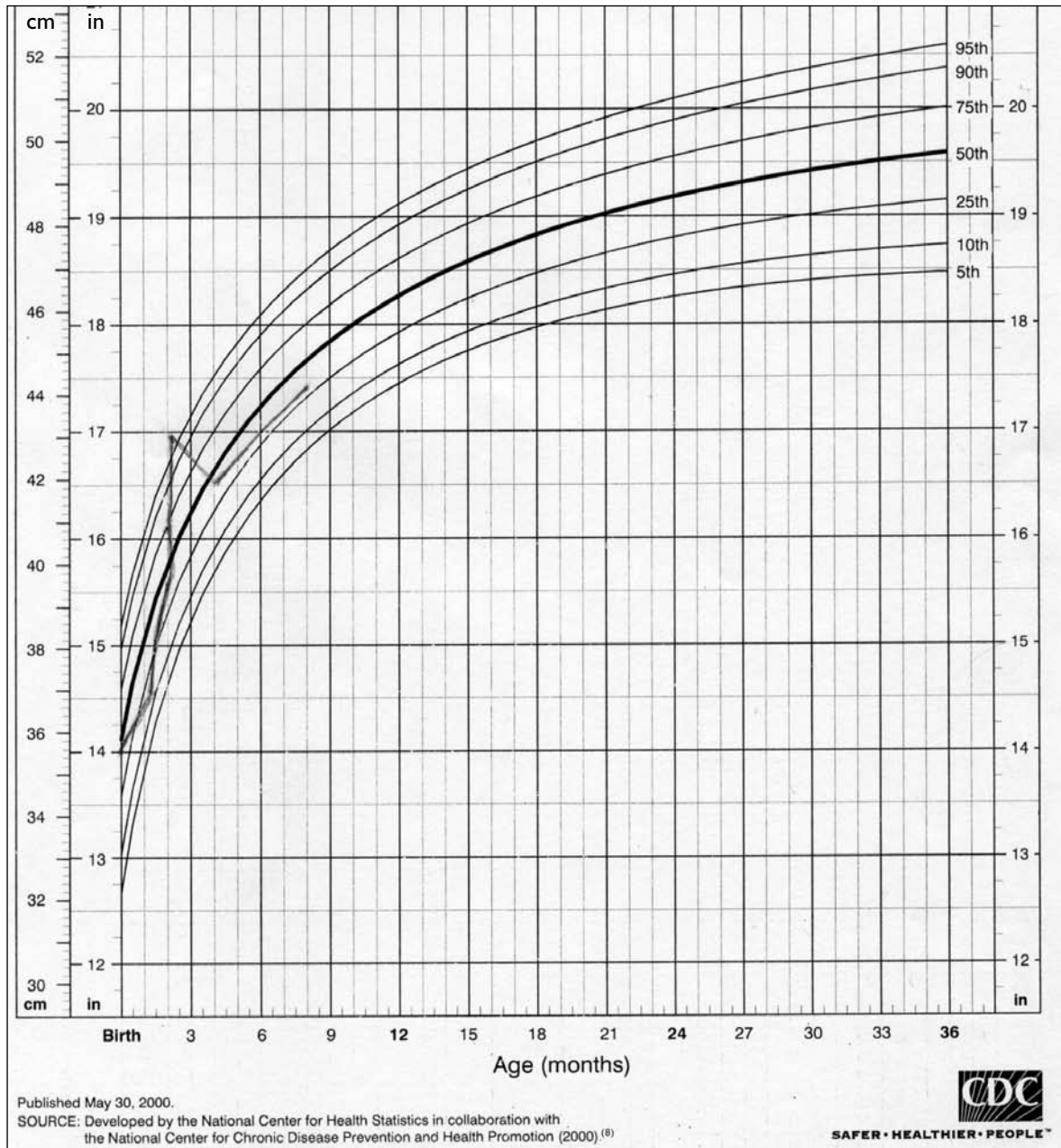
Laboratory studies showed blood sugar 80 mg/dL, serum calcium 9.6 mg/dL, serum sodium 141 meq/L and serum potassium 5.4 meq/L. Haemoglobin was 16.7 g/dL, white blood cells (WBC) 16,300 cells/mm<sup>3</sup> with 83% neutrophil and 17% lymphocyte, and platelet 340,000/mm<sup>3</sup>. CRP was elevated at 20 mg/L. The cerebrospinal fluid (CSF) analysis showed CSF pleocytosis with a WBC count of 1,040 cells/ $\mu$ L with 90% neutrophil and 10% lymphocyte, sugar was 15 mg/dL and protein 140 mg/dL. CSF cultures revealed *Streptococcus* group B and on blood culture, *Staphylococcus* coagulase-negative was also detected, which was sensitive to vancomycin. With the impression

Department of  
Paediatrics,  
Namazi Hospital,  
Shiraz University of  
Medical Science,  
Shiraz 71937-11351,  
Iran

Hemmati F, MD  
Neonatologist and  
Assistant Professor

Pishva N, MD,  
Neonatologist and  
Professor

Correspondence to:  
Dr Hemmati Fariba  
Tel: (98) 91 7111 0281  
Fax: (98) 71 1626  
5024  
Email: hemmatif@  
sums.ac.ir



**Fig. 1** Chart shows the head circumference-for-age percentiles for boys from birth to 36 months.<sup>(8)</sup>

of bacterial meningitis, he was treated with ampicillin (high dose) and cefotaxime. The patient became afebrile 48 hours after antibiotic therapy and no episode of cyanosis occurred. Lumbar puncture was performed again, about 72 hours after treatment, which showed improvement and CSF culture became negative.

On the sixth day of admission, the patient had a relapse of fever, but he did not have any symptoms of infection, and physical examination was normal except for episodes of fever. The patient had normal grasping and Moro reflexes, and no change in head circumference was detected. No skin infections or phlebitis were noticed. complete blood count, CRP, chest radiograph and all cultures were repeated. He had a WBC count of 24,400 cells/mm<sup>3</sup> with 76% neutrophil and 23% lymphocyte and 1% monocyte. Serial CRP was checked on admission, on

the second and sixth days of treatment, which increased to 20, 40 and 80 mg/L, respectively. Chest radiographs, urine analysis and urine culture were normal. A second blood culture (repeated on the sixth day of treatment) was negative and CSF analysis was undertaken that showed WBC of 20 cells/ $\mu$ L with 18 neutrophils and 2 lymphocytes, proteins 89 mg/dL and sugar 30 mg/dL, demonstrating improvement. Gram stain and culture of the CSF were negative.

A brain computed tomography (CT) was done. The results showed hypoattenuated white matter in the periventricular area similar to ischaemic change, no signs of hydrocephaly were detected and the sizes of ventricles were normal. This CT scan of the brain was reported by three radiologists. Vancomycin was added to the antibiotics and the patient became afebrile three

days later. CRP became 10 mg/L, but serial CRP again increased to 40 mg/L and erythrocyte sedimentation rate (ESR) was 50 mm/h. Bone scintiscan done for exclusion of occult osteomyelitis was normal. The patient was well and no site of infection was detected. Head circumference was checked by one physician each day and no abnormal change in head circumference was seen. The patient received ampicillin and cefotaxime for three weeks and vancomycin for two weeks. The patient was discharged with a CRP of 40 mg/L, and the parents were asked to check the patient's temperature and return to the clinic as scheduled.

At clinical follow-up at 40 days of age, the patient had a head circumference of 37 cm (10th–25th percentiles) and weight of 3,750 g (25th percentile). His physical examination results were normal. No episodes of fever were reported by the parents. The patient had a WBC count of 11,300 cells/mm<sup>3</sup> with 40% segment, ESR 19 mm/hour, CRP 60 mg/L. The patient was referred two weeks later, at age of 54 days, and had a head circumference of 39.5 cm (25th–50th percentile) and weight of 4,300 g (25th percentile). One week later (at 60 days of age), the head circumference was 40.7 cm (75th percentile) and weight was 4,600 g (25th percentile), with a bulged fontanelle. He was referred for brain magnetic resonance imaging, but his parents refused and seven days later, was referred to the hospital with head circumference of 43 cm (> 95th percentile) and sign of sun-setting eyes. The brain CT showed severe dilatation of both lateral and third ventricles in favor of aqueduct obstruction, so an emergency ventriculoperitoneal shunt was inserted. At follow-up after operation, the patient had normal growth and development, up to eight months of age.

## DISCUSSION

Although in previous reports<sup>(4-6)</sup> C-reactive protein was used as a detector of complications during recovery from childhood purulent meningitis, complications that were reported were due to central nervous system (CNS) or other systemic infections. But in our case, no site of infection was detected after treatment. After discharge from the hospital, the patient did not develop any fever and the elevated CRP was thought to be due to aqueduct gliosis. As a result of neonatal meningitis, the ependymal lining of aqueduct is interrupted and a brisk glial response resulted into complete obstruction.<sup>(7)</sup> Our patient was referred four days after fever, so risk of complications due to age of the patient and delay in treatment was high. We followed-up the patient with serial CRP with secondary

elevation, and the patient was evaluated for infection in other sites or CNS complications. The patient had a normal increase in head circumference during the hospital course and in the first outpatient department follow-up, but in the second and third outpatient follow-up and in the second hospital admission, the patient had a significant abnormal increase in head circumference especially in the three days prior to the second hospital admission (Fig. 1). The patient had periventricular hypoattenuated area in the first CT, so the ependymal lining of aqueduct was interrupted. Coupled with the increase of the positive CPP of the glial response during the three days prior to the second admission, complete obstruction of the aqueduct occurred due to brisk glial response and a significant hydrocephalus was observed.

We conclude that serum CRP monitoring in infants with bacterial meningitis provides useful and objective information about the clinical evaluation, and this is not only due to infectious complications, but also inflammation due to cellular destruction. This procedure is inexpensive and suitable in areas lacking sophisticated laboratories.

## ACKNOWLEDGEMENTS

The authors wish to thank the Office of the Vice Chancellor for Research of Shiraz University of Medical Sciences for financial support, and Dr D Mehrabani at Centre for Development of Clinical Studies for editorial assistance.

## REFERENCES

1. Edwards MS. Postnatal bacterial infection. In: Martin RJ, Fanaroff AA, Walsh MC, eds. *Fanaroff and Martin's Neonatal-Perinatal Medicine: Diseases of the Fetus and Infant*. 8th ed. Philadelphia: Mosby and Elsevier, 2006: 797-8.
2. Nudelman R, Kagan BM. C-reactive protein in pediatrics. *Adv Pediatr* 1983; 30:517-47.
3. Jaye DL, Waites KB. Clinical applications of C-reactive protein in pediatrics. *Pediatr Infect Dis J* 1997; 16:735-47.
4. Peltola H, Luhtala K, Valmari P. C-reactive protein as a detector of organic complications during recovery from childhood purulent meningitis. *J Pediatr* 1984; 104:869-72.
5. Dias Leite R, Alves Riberio M, Farhat CK. C-reactive protein follow-up of children with acute bacterial meningitis. *Braz J Infect Dis* 1999; 3:15-22.
6. Singh UK, Sinha RK, Suman S, Singh VK. C-reactive protein as an indicator of complications in bacterial meningitis. *Indian Pediatr* 1996; 33:373-6.
7. Johnston MV, Kinsman S. Congenital anomalies of the central nervous system. In: Behrman RE, Kliegman RM, Jenson HB, eds. *Nelson Textbook of Pediatrics*. 17th ed. Philadelphia: WB Saunders, 2004: 1990-1.
8. Ogden CL, Kuczmarski RJ, Flegal KM, et al. Centers for Disease Control and Prevention 2000 growth charts for the United States: improvements to the 1977 National Center for Health Statistics version. *Pediatrics* 2002; 109:45-60.