

# Systemic Wegener's granulomatosis with severe orbito-ocular involvement

Chua J, Lim L

## ABSTRACT

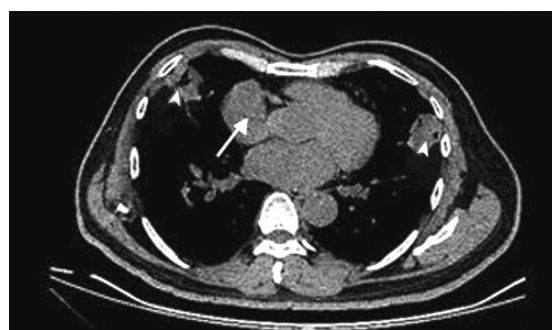
Orbito-ocular involvement in Wegener's granulomatosis is the result of both focal ischaemic vasculitis and granulomatous soft tissue inflammation. Necrotising keratoscleritis and orbital inflammation are two most characteristic ophthalmic presentations. We describe a 56-year-old man with systemic limited Wegener's granulomatosis, presenting with pulmonary fibrosis, pansinusitis and left mastoiditis. This was complicated by the development of a left severe necrotising anterior scleritis, peripheral ulcerative keratitis and orbital apex syndrome. Both c-ANCA and anti-PR3 were positive. Despite mainstay systemic immunosuppressive therapy with cyclophosphamide and prednisolone, the visual prognosis remained very poor. This was largely due to the presence of an irreversible ischaemic optic neuropathy, extensive corneoscleral melt and corneal neovascularisation. This case highlights the possible extent of orbital and ocular surface involvement in Wegener's granulomatosis, and hence the importance of vigilance by the physician.

**Keywords:** anterior necrotising scleritis, orbital inflammation, peripheral ulcerative keratitis, Wegener's granulomatosis

*Singapore Med J 2008;49(10):e259-e262*

## INTRODUCTION

The multisystemic clinical involvement in Wegener's granulomatosis is a result of an underlying primary vasculitis involving the arteriolar system. This is supported histologically by the presence of granulomatous inflammation of arterioles with parenchymal necrosis. Pulmonary consolidation, necrotising inflammation of the upper respiratory tract and glomerulonephritis are common systemic features seen in the classical or complete form of Wegener's granulomatosis. A limited form of this condition, with the absence of renal involvement, has been previously described. Ophthalmic involvement can occur in both forms of Wegener's granulomatosis, with a reported



**Fig. 1** Axial CT image of the thorax shows enlarged mediastinal lymph nodes (white arrow) and bilateral lung nodules (arrowheads) located adjacent to the pleura. Cavitation within nodules can be seen.

incidence ranging from 28%<sup>(1)</sup> to 60%.<sup>(2)</sup> A retrospective review of 40 pathologically-confirmed cases with orbito-ocular involvement by Bullen et al showed that orbital inflammatory disease was the commonest ophthalmic manifestation, followed by scleral and episcleral involvement.<sup>(1)</sup> Extent and severity of anterior sclera involvement ranges from a mild sectoral non-necrotising scleritis to one associated with scleral necrosis. In a case series described by Charles et al,<sup>(3)</sup> the presence of scleral necrosis is usually associated with severe limbal ischaemia and corneal stromalysis, and is also shown to be a good reflection of the severity of the underlying systemic involvement. Pulsed systemic methylprednisolone and cyclophosphamide followed by oral maintenance dosing has been shown to be effective in inducing remission of the inflammatory process.<sup>(3,4)</sup> We describe a case of unilateral severe necrotising anterior scleritis, peripheral ulcerative keratitis and orbital apex syndrome in a patient with a limited form of Wegener's granulomatosis, involving the pulmonary and upper respiratory tract. This case illustrates the aftermath of a resolved orbito-ocular inflammatory disease, after successful remission with systemic immunosuppression.

## CASE REPORT

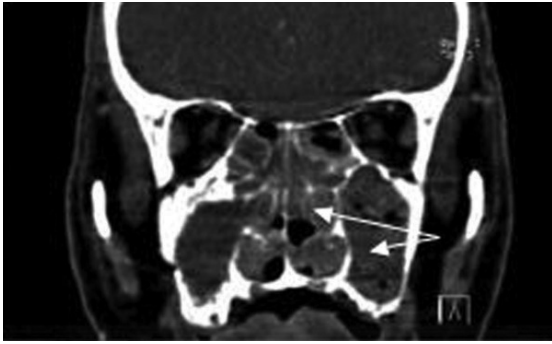
A 56-year-old man presented with a one-month history of non-productive cough, dyspnoea, lethargy and progressive weight loss. Chest radiograph showed bilateral homogeneous well-defined pleural-based

Singapore National Eye Centre,  
11 Third Hospital Avenue,  
Singapore 168751

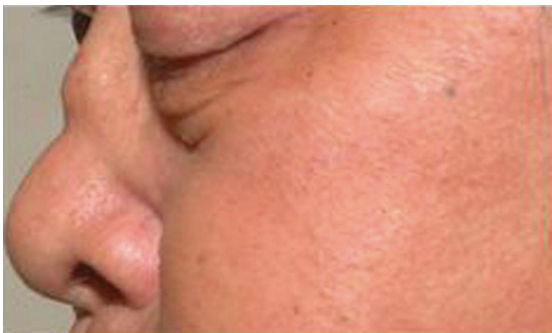Chua J, MMed,  
MRCSE  
Registrar

Lim L, MMed,  
FRCSE, FAMS  
Senior Consultant,  
Corneal Service

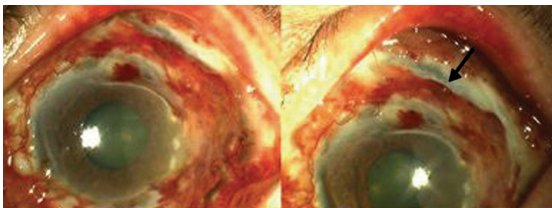
**Correspondence to:**  
Dr Lim Li  
Tel: (65) 6227 7255  
Fax: (65) 6226 3395  
Email: limli98@yahoo.com



**Fig. 2** Coronal CT image of the paranasal sinuses shows bilateral pansinusitis (arrows).



**Fig. 3** Photograph shows a saddle-shaped nose as a result of inflammatory destruction of the nasal septum.



**Fig. 4** Photographs of the eye shows the extent of necrotising scleritis with sectoral thinning (arrow) and associated peripheral ulcerative keratitis.

opacities. Computed tomography of the thorax and paranasal sinuses demonstrated bilateral cavitating nodules (Fig. 1) associated with scarring, pansinusitis (Figs. 2 & 3) and left mastoiditis. Nasal biopsy showed vasculitis with fibrinoid necrosis and granuloma formation. Both c-ANCA and anti-protease 3 were positive. Mantoux test was negative. Biochemical renal function was normal. The patient was treated with pulsed intravenous cyclophosphamide and a three-day course of 1g/day methylprednisolone, followed by oral prednisolone of 1g/kg/day by the rheumatologist.

One month later, he presented with an acute onset of left eye redness, orbital pain and decreased vision. Examination of the left eye revealed a Marcus Gunn pupil, light perception visual acuity and a 23-mm proptosis. His left extraocular movements were limited in all gaze positions, and was associated with a complete ptosis and fixed dilated pupil. The presence

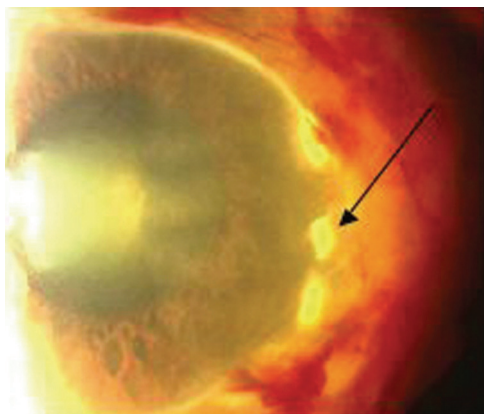
of an ipsilateral pupil-involved complete third, fourth and sixth nerve palsies, optic neuropathy and proptosis were consistent with a left orbital apex syndrome. Severe necrotising anterior scleritis associated with extensive subconjunctival haemorrhage was also noted (Fig. 3). Peripheral ulcerative keratitis was seen adjacent to the areas of scleritis (Fig. 4). A mild left anterior uveitis was also present. Anterior segment examination of the right eye was normal. The posterior segment examinations of the both eyes were unremarkable. Intraocular pressure was within normal range in both eyes. In addition to systemic immunosuppression, topical Pred Forte 1%, levofloxacin, maxidex and atropine 1% eyedrops were also administered to his left eye.

Over the next eight months of systemic and topical immunosuppression, progressive corneoscleral melt followed resolution of ocular surface inflammation. Severe scleromalacia with extensive uveal prominence was seen, with up to 90% scleral melt (Fig. 6). This was also associated with circumferential corneal guttering and conjunctivalisation. There was no ocular surface perforation noted during the course of his disease. His left vision deteriorated to no light perception but some recovery of his left ptosis and ophthalmoplegia was observed. His systemic condition remained in remission.

## DISCUSSION

Wegener's granulomatosis is an uncommon multisystemic autoimmune granulomatous vasculitic disease, associated with significant morbidity and mortality. It is more prevalent in the West and relatively rare in the East. In a National Institute of Health case series of 158 patients with Wegener's granulomatosis, "other nonwhites" made up only 1% of the case population.<sup>(5)</sup> A retrospective case series by Biswas et al reported only nine cases over a 15-year period in Chennai.<sup>(6)</sup> This disease condition can affect both the paediatric and aged population, with a mean age of presentation of 41 years. To date, Wegener's granulomatosis is still thought to be a largely sporadic disease, although there has been some poorly-supported data suggesting a possible genetic preponderance.<sup>(5)</sup>

Ophthalmic involvement is a common feature of Wegener's granulomatosis and is potentially sight-threatening. Relevant medical literature from 1966 to 2005 reviewed by Pakrou et al showed that ocular involvement occur in up to 60% of cases, and presentations varied in extent and severity.<sup>(2)</sup> The myriad of ophthalmic manifestations described in the literature include non-specific conjunctivitis, tarso-conjunctival granulomatous inflammation

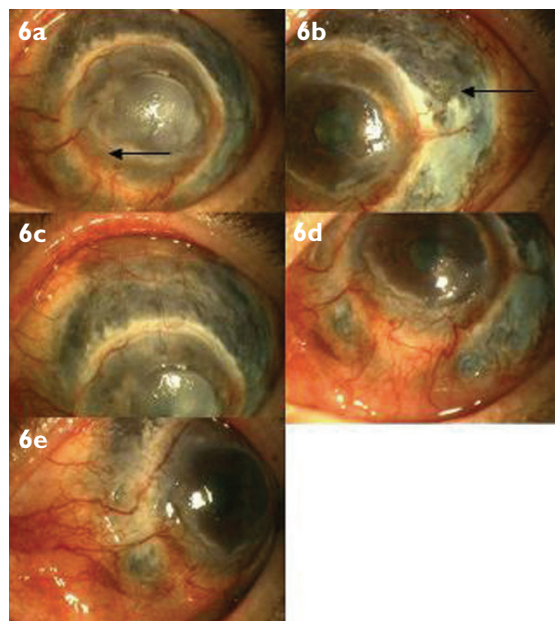


**Fig. 5** Photograph of the eye shows peripheral ulcerative keratitis adjacent to an area of scleritis, which are seen as whitish infiltrates at the corneal periphery (arrow).

with scarring, episcleritis, scleritis, peripheral ulcerative keratitis, uveitis, retinitis, retinal vasculitis, exudative retinal detachment, retinal vascular disease, nasolacrimal duct obstruction, orbital inflammatory disease, optic neuropathy and ocular motor cranial neuropathy.<sup>(1-3,5-7)</sup> Of these, necrotising sclerokeratitis and orbital inflammatory disease are the two most characteristic ophthalmic presentations,<sup>(5)</sup> usually associated with systemic involvement.<sup>(2,3,7)</sup>

Orbital inflammation in Wegener's granulomatosis occurs as a result of either a primary granulomatous vasculitic process or due to a contiguous spread from the paranasal sinuses. Proptosis is the commonest clinical finding.<sup>(5)</sup> It can be an isolated sign of orbital involvement or part of a constellation of signs. The latter presentation is illustrated in our patient with an orbital apex syndrome. Paralysis of the third, fourth, sixth, first division of fifth nerves as well as optic neuropathy occur due to proximity of the cranial nerves and blood vessels within the enclosed apex of the orbit. Poor vision (usually < 6/60) occurs in up to 50% of orbital cases, as a result of ischaemic or compressive optic neuropathy.<sup>(1,2)</sup> Other possible causes of poor vision in orbital inflammatory disease include exposure keratopathy secondary to proptosis, neurotrophic keratopathy and glaucoma. Scleritis in Wegener's granulomatosis reflects the presence and severity of systemic involvement.<sup>(1-3)</sup> Its pathological process is due to primary granulomatous vasculitis with consequent ischaemia. This can potentially result in limbal ischaemia and scleral necrosis with risk of perforation. Peripheral keratitis is usually associated with anterior scleritis, especially so with the necrotising type.<sup>(1)</sup> Chronic inflammation of the peripheral cornea leads to stromal thinning, guttering and neovascularisation.

Serum c-ANCA has been proven invaluable in the diagnosis of both ocular and systemic forms of



**Fig. 6** Photographs of the eye show the extent of circumferential scleral and peripheral corneal thinning with vascularisation (arrows). The severity of scleral thinning can be appreciated by (a) the presence of extensive uveal prominence; (b) close-up with the eye in right gaze; (c) eye in downgaze; (d) eye in upgaze; and (e) eye in left gaze.

the disease. The return of c-ANCA titres to normality has been shown to be associated with maintenance of remission and hence better prognosis.<sup>(3,4)</sup> Prompt administration of systemic immunosuppressives is the mainstay of treatment for both ocular and systemic complications in Wegener's granulomatosis. This includes corticosteroids as well as steroid-sparing drugs, such as cyclophosphamide or mycophenolate mofetil.<sup>(8)</sup> More than one immunosuppressive agent are usually required to induce and maintain remission.<sup>(9)</sup> Due to the chronicity of the disease and frequent relapses, immunosuppressive treatment is usually prolonged. This increases the risk of side effects secondary to steroid use. Side effects due to steroid-sparing drugs are also potentially debilitating and life-threatening, requiring regular biochemical monitoring. Cases refractory to conventional immunosuppression have prompted the recent development of biological agents, which aim to target the underlying immunological process that is believed to have played an important role in the pathogenesis of the disease. Agents that target lymphocytes, such as rituximab and alemtuzumab, as well as TNF blockers, such as infliximab, have been shown to be as efficacious in inducing remission in cases of refractory Wegener's granulomatosis.<sup>(10,11)</sup>

Our case demonstrates the extent of ocular morbidity despite successful treatment of anterior necrotising scleritis. Although immunosuppressive therapy is capable of inducing remission, postinflammatory

severe thinning of the scleral coat may follow with a high risk of globe perforation. It is thus important that physicians are aware of the possible ophthalmic complications in Wegener's granulomatosis and symptomatic patients referred for an early ophthalmic assessment.

## REFERENCES

1. Bullen CL, Liesegang TJ, McDonald TJ, DeRemee RA. Ocular complications of Wegener's granulomatosis. *Ophthalmology* 1983; 90:279-90.
2. Pakrou N, Selva D, Leibovitch I. Wegener's granulomatosis: Ophthalmic manifestations and management. *Semin Arthritis Rheum* 2006; 35:284-92.
3. Charles SJ, Meyer PAR, Watson PG. Diagnosis and management of systemic Wegener's granulomatosis presenting with anterior ocular inflammatory disease. *Br J Ophthalmol* 1991; 75:201-7.
4. Power WJ, Rodriguez A, Neves RA, Lane L, Foster CS. Disease relapse in Wegener's granulomatosis. *Ophthalmology* 1995; 102:154-60.
5. Harman LE, Margo CE. Wegener's granulomatosis. *Surv Ophthalmol* 1998; 42:458-80.
6. Biswas J, Babu K, Gopal L, et al. Ocular manifestations of Wegener's granulomatosis: Analysis of nine cases. *Indian J Ophthalmol* 2003; 51:217-23.
7. Sadiq SA, Jennings CR, Jones NS, Downes RN. Wegener's granulomatosis: The ocular manifestations revisited. *Orbit* 2000; 19:253-61.
8. Sen HN, Suhler EB, Shadi Q, et al. Mycophenolate mofetil for the treatment of scleritis. *Ophthalmology* 2003; 110:1750-5.
9. Jampol LM, West C, Goldberg MF. Therapy of scleritis with cytotoxic agents. *Am J Ophthalmol* 1978; 86:266-71.
10. Lim L, Suhler EB, Smith JR. Biologic therapies for inflammatory eye disease. *Clin Experiment Ophthalmol* 2006; 34:365-74.
11. Cheung CMG, Murray PI, Savage COS. Successful treatment of Wegener's granulomatosis associated with scleritis with rituximab. *Br J Ophthalmol* 2005; 89:1542.