

# Lumbosacral transitional vertebra: clinical and forensic implications

Kanchan T, Shetty M, Nagesh K R, Menezes R G

## ABSTRACT

**The identification of skeletal remains is one of the classic problems faced by forensic experts. Congenital and acquired malformations can prove to be an important tool for identification, provided antemortem records are available. A lumbosacral transitional vertebra is one such rare congenital anomaly that has clinical and medicolegal implications. We report a case of unilateral lumbosacral transitional vertebra, detected during medicolegal examination of skeletal remains that were recovered from a forested area in coastal Karnataka, India. The congenital anomaly of the transitional vertebra helped in the forensic identification of the deceased.**

**Keywords: congenital sacral anomaly, forensic science, lumbosacral vertebra, remains identification, transitional vertebra**

*Singapore Med J 2009;50(2):e85-e87*

## INTRODUCTION

Identifying personal features in the form of congenital malformations can be compared with antemortem records in order to establish identity. Forensic anthropologists may come across such rare congenital abnormalities during the examination of skeletal remains. These individuals are likely to have hospital records for treatment of the condition that may be obtained and matched with the condition observed during skeletal remains examination.<sup>(1)</sup> A transitional lumbosacral vertebra is a common congenital anomaly first observed by Bertolotti.<sup>(2)</sup> Such a transitional vertebra may have varying formations, the common feature being an atypical lumbosacral articulation between the transverse process of the most inferior lumbar vertebra and the sacrum. When the L5 vertebra is fused to the sacrum completely (sacralisation of L5), there are only four lumbar vertebrae, whereas when S1 is separated from the sacrum (lumbarisation of S1), there are six lumbar vertebrae, and many intermediate variations are reported. We report a case of unilateral lumbosacral transitional vertebra, detected during the medicolegal examination of skeletal remains that were recovered from a forested area in coastal Karnataka, India. The clinical and forensic significance of the lumbosacral transitional vertebra is discussed.

## CASE REPORT

A student of environmental sciences, who was studying the Indian environment and forestry, went missing in June 2006. He had set up a tent inside the forest about five miles from the village. He would go to the village once in a while and had developed a good rapport with a local, who used to help him. Once, when the student had not visited the village for 3–4 days, the local went with his friends to the tent to enquire about his well-being. They found that the goods had been stolen from the tent and the student was found hanging from a nearby tree. The locals were too frightened to inform the police. About nine months later, the villagers came across a newspaper notification about the same student who was stated to be missing from the Mangalore district of southwestern India, and that the police were investigating his whereabouts. The local, along with some other villagers, then approached the police and disclosed the facts known to them. The investigating team visited the crime scene and recovered the belongings in the tent and the skeletal remains from under the nearby tree. The belongings recovered from the tent were positively identified by the father of the deceased. Later, the police recovered some of the student's belongings from a villager's house; the villager confessed that the student had been strangled, hit with a stone on the head and then hanged off a nearby tree. The primary task of the investigating agency was to confirm the identity of the skeletal remains, which was sent to forensic experts for the task of establishing its identity.

The skeletal remains received at the state medicolegal consultant's office in Mangalore included a skull without a mandible, manubrium, all ribs, 23 vertebrae along with the sacrum, both clavicles, scapulae, humerus, ulna, tibia with broken ends, hip bones, left radius, left femur, and a few carpal and metacarpal bones. Ten loose teeth and a desiccated scalp layer with attached brownish hair were also received. The dry soiled bones were free of soft tissues. Examination revealed that the bones belonged to a male aged 25–35 years. Gender determination was based on the inspectional method of sexually dimorphic morphological traits in the skull, hip bone and femur. Age estimation was based on the fusion of ossification centres in the long bones, symphyseal changes on the articular surface of the pubis, and obliteration of cranial sutures. The stature of the individual was calculated as 183–188 cm by applying the regression formula to the lengths of the femur and humerus.

**Department of Forensic Medicine, Kasturba Medical College, Mangalore 575001, India**

Kanchan T, DFM, MD  
Assistant Professor

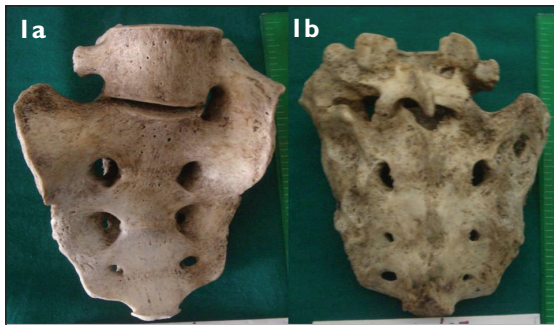
Nagesh KR, MD  
Associate Professor

Menezes RG, MD,  
DNB  
Assistant Professor

**Department of Forensic Medicine, KS Hegde Medical Academy, Mangalore 575018, India**

Shetty M, MD  
Associate Professor

**Correspondence to:**  
Dr Tanuj Kanchan  
Tel: (91) 824 242 2271  
ext 5565  
Fax: (91) 824 242 8183  
Email: tanujkanchan@yahoo.co.in



**Fig. 1** (a) Anterior and (b) posterior photographs of the transitional vertebra.

Maxillary dental examination revealed impacted third molars on both sides, and dental filling in the second right premolar, both first molars and second left molar. Evidence of root canal treatment was obvious in the second right molar tooth. Postmortem loss of the remaining teeth was evident from the appearance of sockets. The maxillary part of the skull was radiographed. The investigating agency was provided with an orthopantomogram of the missing person, who had undergone dental treatment. Antemortem dental records and radiographs were matched to confirm the identity of the individual. Lumbosacral transitional vertebra was identified (Fig. 1) and antemortem records were matched that further confirmed the identity of the deceased.

## DISCUSSION

A transitional vertebra is a birth defect that has the characteristics of two types of vertebrae. Normally, five sacral vertebrae fuse to form the wedge-shaped sacrum with ossification of the intervertebral joints. Broadest superiorly, the sacrum articulates with the fifth lumbar vertebra, while inferiorly, it narrows to articulate with the coccyx. The first sacral vertebra may not fuse with the second, in which case there is lumbarisation of S1 and the person appears to have six lumbar vertebrae. The converse can also occur, called sacralisation of L5, where the individual appears to have four lumbar vertebrae.<sup>(3)</sup> The condition is more often bilateral and has medicolegal and clinical implications. The clinical significance of a lumbosacral transitional vertebra has been frequently debated and estimates in the general population vary greatly, ranging from 4% to 24%.<sup>(2)</sup> A transitional vertebra at the lumbosacral junction signifies that one vertebra in the lower back forms a part of the spine above, and is a part of the pelvis below. The resulting overwork can cause arthritis, disc changes or spinal cord compression. The person usually is asymptomatic or may present with symptoms clinically that include spinal or radicular pain, disc degeneration, L4/L5 disc prolapse, lumbar scoliosis and lumbar extradural defects.<sup>(4,5)</sup>

The most significant aspect of the lumbosacral transitional vertebra is the change in mechanics of the lumbar spine due to its presence. No study has documented the actual change in biomechanics with a transitional vertebra, but it has been postulated that a bilateral articulation between the transverse processes of the most inferior lumbar vertebra and the sacrum limits the motion of this joint.<sup>(6,7)</sup> This results in greater forces being imparted to the segment above, and potentially more translation and rotation occurring with movement at this superior level. It is hypothesised that biomechanical loading conditions are similar between a L5–S1 transitional vertebra and a surgical fusion at this same level, and imparts more stress on the level above. The disc at the level above the fused segment has been found to be at increased risk of degeneration.<sup>(4)</sup> Unilateral incomplete articulation frequently results in increased local stress, potentially resulting in joint pain. A literature review makes it apparent that having a transitional vertebra does not necessarily result in symptoms, but those with a transitional vertebra who are asymptomatic tend to have a specific pathology. Early internal disc disruption of the level above, spondylosis concentrated at the level above, contralateral facet pain and pain from the articulation with the transverse process, have all been shown to be common entities associated with a transitional vertebra.<sup>(2)</sup> The condition has been associated with a cervical rib. The presence of a cervical rib might be a clue to the existence of sacralisation or vice versa.<sup>(8)</sup> In addition, it has known implications in the field of disc surgery. There are reports of surgery being performed at the wrong lumbar level,<sup>(9)</sup> and the presence of a transitional vertebra may contribute to this error. Thus, the presence of a transitional vertebra has tremendous clinical significance.

The importance of the sacrum in the identification of an individual is well known. The sacrum is implicated in the determination of gender, age and stature. It has been studied extensively, probably because of its contribution to the pelvic girdle and the functional differences in the region between the sexes.<sup>(1)</sup> Flander has developed a technique to assess gender and race simultaneously by using sacra from American Blacks and Whites.<sup>(10)</sup> Base wing index is another simpler method of sexing the sacrum.<sup>(1)</sup> The transitional vertebra has obvious implications in various indices used for sex determination from the sacrum. Age estimation from the sacrum is based on the fusion of five sacral vertebrae that occur from below upwards. The five sacral vertebrae are separated by cartilage until puberty. The fusion of epiphysis takes place and ossification of intervertebral discs extends from below upwards. The sacrum becomes a single bone between 21 and 25 years of age. A gap may be present between S1 and S2 until 32 years of age due to a

“lapsed union.”<sup>(1)</sup> Recently, stature has been successfully determined from the sacrum using regression analysis.<sup>(11)</sup> Lundy discussed the implications of sacralisation on stature estimation and found that the accuracy of the anatomical method is enhanced by including the height of the actual S1 segment in the calculation, while the accuracy of the Trotter and Glesser estimate is enhanced by adding the height of the extra vertebra to the stature estimate.<sup>(12)</sup>

During medicolegal investigations, some congenital abnormalities are detected which are of vital importance in identification, especially when antemortem records are available. A person with lumbosacral transitional vertebra is likely to seek medical advice if the condition is symptomatic, and thus there is a high chance that antemortem medical records exist. From the medicolegal perspective, this has implications for the determination of primary indicators of identification. Thus, when skeletal remains are brought in for examination, the transitional vertebra can be helpful in confirming identity.

## REFERENCES

1. Krogman WM, Iscan MY. *The Human Skeleton in Forensic Medicine*. Springfield: Charles C Thomas, 1986.
2. Delpont EG, Cucuzzella TR, Kim N, et al. Lumbosacral transitional vertebrae: incidence in a consecutive patient series. *Pain Physician* 2006; 9:53-6.
3. Williams PL, Warwick R, Dyson M, Bannister LH. *Gray's Anatomy*. 37th ed. New York: ELBS-Churchill Livingstone, 1989.
4. Luoma K, Vehmas T, Raininko R, Luukkonen R, Riihimaki H. Lumbosacral transitional vertebra: relation to disc degeneration and low back pain. *Spine* 2004; 29:200-5.
5. Castellvi AE, Goldstein LA, Chan DP. Lumbosacral transitional vertebrae and their relationship with lumbar extradural defects. *Spine* 1984; 9:493-5.
6. Otani K, Konno S, Kikuchi S. Lumbosacral transitional vertebrae and nerve-root symptoms. *J Bone Joint Surg Br* 2001; 83:1137-40.
7. McCulloch JA, Waddell G. Variation of the lumbosacral myotomes with bony segmental anomalies. *J Bone Joint Surg Br* 1980; 62:475-80.
8. Erken E, Ozer HT, Gulek B, Durgun B. The association between cervical rib and sacralization. *Spine* 2002; 27:1659-64.
9. Wiese M, Kramer J, Bernsmann K, Ernst Willburger R. The related outcome and complication rate in primary lumbar microscopic disc surgery depending on the surgeon's experience: comparative studies. *Spine J* 2004; 4:550-6.
10. Flander LB. Univariate and multivariate methods for sexing the sacrum. *Am J Phys Anthropol* 1978; 49:103-10.
11. Pelin C, Duyar I, Kayahan EM, et al. Body height estimation based on dimensions of sacral and coccygeal vertebrae. *J Forensic Sci* 2005; 50:294-7.
12. Lundy JK. Sacralization of a sixth lumbar vertebra and its effect upon the estimation of living stature. *J Forensic Sci* 1988; 33:1045-9.