

Tuberculosis of the chest wall: unusual presentation as a breast lump

Teo T H P, Ho G H, Chaturverdi A, Khoo B K J

ABSTRACT

A 33-year-old woman presented with a painless right breast lump of four weeks' duration. There were no symptoms such as fever or night sweats. Mammogram revealed an elliptical lesion in the retromammary region. Ultrasonography showed a hypoechoic collection deep in the right breast. As the lesion was localised to the chest wall, computed tomography of the thorax was performed. This confirmed a fluid collection in the right anterior chest wall and also bilateral upper lobe consolidations, suggestive of pulmonary tuberculosis with an abscess in the anterior chest wall. Ultrasound-guided core needle biopsy confirmed a *Mycobacterium tuberculosis* infection. It is unusual for a tuberculous abscess of the chest wall to present as a painless breast lump. We also present a companion case of tuberculous mastitis to illustrate their distinct imaging features.

Keywords: breast mass, chest wall tuberculosis abscess, *Mycobacterium tuberculosis*, retromammary lesion, tuberculosis

Singapore Med J 2009; 50(3): e97-e99

INTRODUCTION

Tuberculosis (TB) of the chest wall constitutes 1%–5% of all cases of musculoskeletal TB,⁽¹⁻⁴⁾ which in turn is far less frequently encountered than pulmonary infection alone, and represents between 1% and 2% of TB overall.⁽⁵⁻⁷⁾ The low incidence may be because the breast tissue, along with the skeletal muscle and spleen, appears to be relatively resistant to TB.^(1,8) TB abscesses of the chest wall are most frequently found at the margins of the sternum and along the rib shafts, and can also involve the costochondral junctions, costovertebral joints and the vertebrae.⁽⁹⁾ Constitutional symptoms of fever, weight loss and night sweats were present in 21% of patients with mammary TB in a series by Khanna et al.⁽¹⁰⁾ The duration of the presenting symptoms in breast TB is usually less than a year but may vary from a few months to several years.^(11,12)

CASE REPORT

A 33-year-old female factory worker, with no past medical history of note, presented to her general practitioner with a

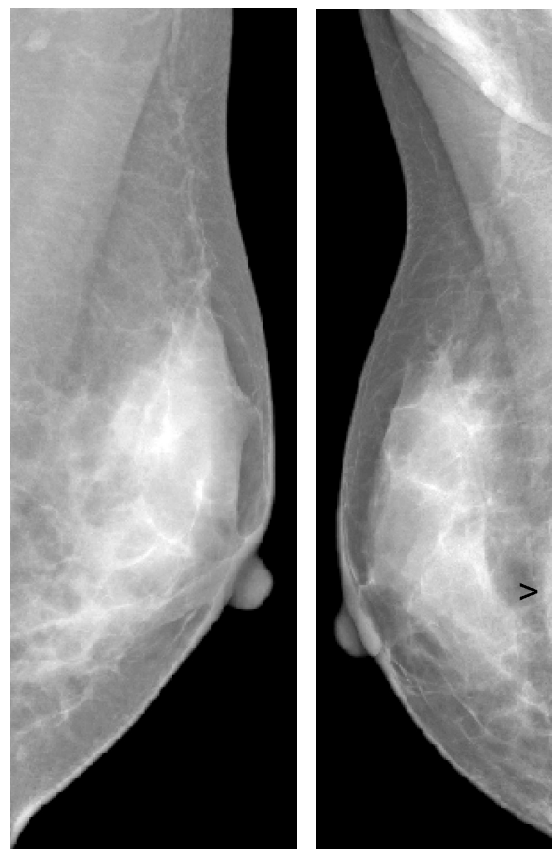


Fig. 1 Bilateral medial lateral oblique mammograms show an elliptical density (arrow) in the retromammary area of the right breast.

painless right breast lump of four weeks' duration. There was no constitutional symptom such as fever or night sweats. Clinical examination revealed a firm 3.5-cm lump in the lower inner quadrant of the right breast. The nipple and skin were normal. Systemic examination revealed no significant abnormality. Mammography showed a well-defined crescentic density in the deep retromammary space, adjacent to the chest wall (Fig. 1). Supplementary ultrasonography (US) showed an elliptical hypoechoic collection deep to the right mammary layer in the lower inner quadrant of the right breast, which corresponded to the mammographic abnormality and the clinically palpable lump (Fig. 2). Further evaluation with computed tomography (CT) of the thorax revealed a necrotic mass in the right anterior chest wall extending through the fourth and fifth intercostal space into the anterior pleura. Patchy airspace consolidations were seen in both upper

Department of
Oncologic Imaging,
National Cancer
Centre Singapore,
11 Hospital Drive,
Singapore 169610

Teo THP, MBBS,
FRCR
Registrar

Khoo BKJ, MBBS,
FRCR
Senior Consultant
and Head

Department of
Surgical Oncology

Ho GH, MBBS, MD,
FRCSE
Senior Consultant

Department of
Radiology and
Imaging,
Rajiv Gandhi Cancer
Institute & Research
Centre,
Sector V,
Rohini,
Delhi 110085,
India

Chaturverdi A, MD
Medical Director

Correspondence to:
Dr Tze Hern Patrick Teo
Tel: (65) 9199 8947
Fax: (65) 6224 1407
Email: thteo76@
gmail.com

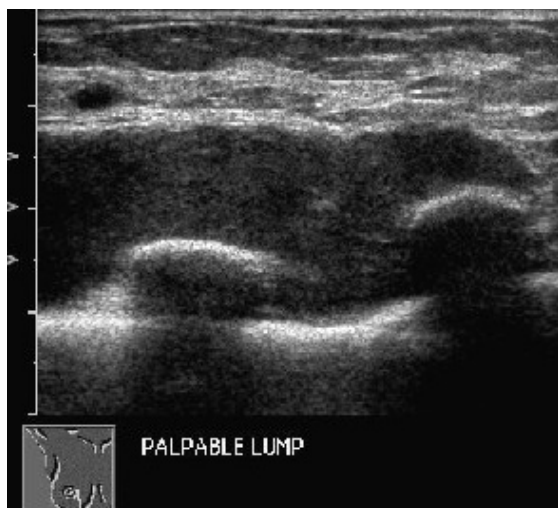

Fig. 2 US image of the right breast shows an elliptical hypoechoic collection deep in the right mammary layer in the lower inner quadrant of the right breast.

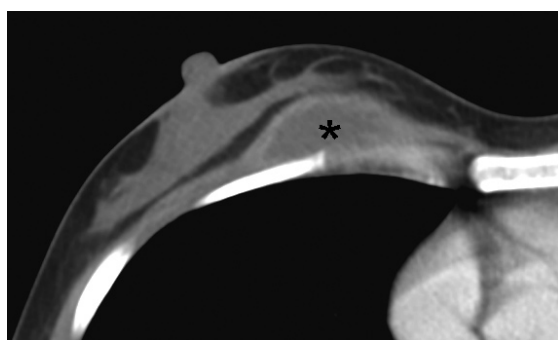

Fig. 4 CT image of the thorax shows a hypodense collection in the right chest wall (asterisk), corresponding to the fluid collection seen on US.

lobes and in the superior segment of the right lower lobe. Ultrasound-guided 14-gauge core needle biopsy was performed and this revealed necrotising granulomatous inflammatory tissue with rare acid-fast bacilli, consistent with a tuberculous infection.

DISCUSSION

TB of the chest wall usually presents with a painful mass. In our case, the clinical presentation of a painless breast lump is unusual. Moreover, TB of the chest wall occurs eight times more frequently in men than in women.⁽¹³⁾ The palpable mass is frequently described as doughy or soft, and may fluctuate but it may sometimes be firm,⁽¹⁴⁾ as in our case. Another related but distinct entity is TB of the breast or tuberculous mastitis. The overall incidence of tuberculous mastitis is reported to be 0.1% of all breast lesions, while in developing countries, this constitutes approximately 3.0% of surgically-treated breast disease.⁽¹⁵⁾ There is, however, a recent increase in incidence in both developed and developing countries, and this is thought to be related to migration from endemic areas and the increased numbers of immunocompromised patients. Patients with TB mastitis also usually present

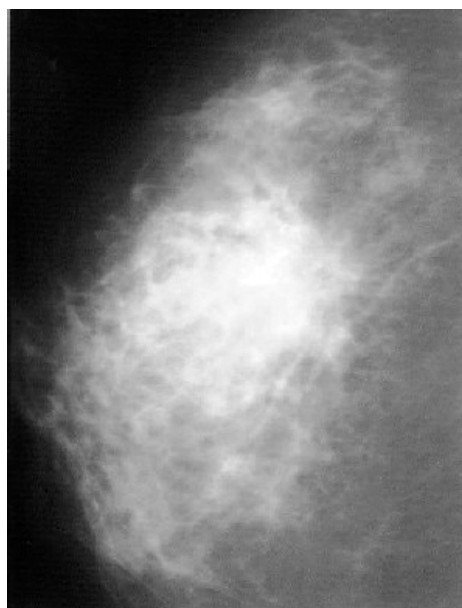


Fig. 3 Craniocaudal mammogram of the right breast of a companion case of TB mastitis in a 32-year-old woman shows an ill-defined mass.

with a painful lump,^(8,16) most often in the central or upper outer quadrant of the breast.⁽¹⁷⁾ The lump is often indistinguishable clinically from breast carcinoma, being irregular, hard, and at times, fixed to either the skin or muscle, or even the chest wall.⁽¹⁸⁾

As a companion case, we present the right mammogram of another patient, a 32-year-old woman with TB mastitis. The mammogram showed an ill-defined density in the right breast (Fig. 3). This is in contrast to the mammogram of our first patient who had chest wall TB, where the well-defined abnormality was clearly in the retromammary space. While mammography has enabled us to identify the clinical abnormality to be arising from the chest wall and not from within the breast, it is often of limited value in distinguishing TB mastitis from breast carcinoma.^(18,19) The disseminated variety can also mimic inflammatory carcinoma and the radiographs also show a dense breast with thickened skin.⁽¹⁹⁾ This is further compounded by the fact that breast TB is usually found in young women 20–40 years of age, and the dense fibroglandular tissues often make the interpretation of a mammogram difficult.

US of the breast is cheap, easily accessible and there is no radiation risk.⁽¹⁹⁾ In our patient, US confirmed the mammographic finding of a chest wall abnormality and identified it as a fluid collection rather than a solid mass. Youk et al has recently demonstrated the usefulness of using US in evaluating chest wall lesions in the breast.⁽²⁰⁾ US may sometimes identify a fistula or sinus tract which can be seen in cases of TB mastitis.^(19,21) CT is seldom

required in the investigation of TB mastitis other than to define the involvement of the chest wall in patients presenting with a deeply adhered breast lump.⁽²²⁾ In our case, CT showed the extent of the collection in the chest wall and also the concomitant consolidation in the lungs that are typical of pulmonary TB (Fig. 4). The association of breast TB with pulmonary TB is variable, and ranges from 17.4% to 62.5%.^(13,23,24) The diagnosis of chest wall TB must be based on bacteriological or histological confirmation. An initial needle aspiration of the mass is necessary to establish a diagnosis and to exclude other diagnoses, such as malignancy and other infectious diseases like actinomycosis.^(25,26)

Medical treatment consisting of a four-drug regimen forms the basis of treatment. Surgical intervention is reserved for the aspiration of cold abscesses, and the excision of residual sinuses and masses. In refractory cases with destruction of the breast, a simple mastectomy may be performed. Extrapulmonary TB occurring in the breast is rare and presentation as a painless breast lump, as in our case, is unusual and rarely reported in the literature. As TB mastitis and chest wall TB are uncommon, even in countries where the incidence of pulmonary and extrapulmonary TB is high, it can be mistaken for more common entities such as breast cancer or a pyogenic breast abscess. Our case report illustrates how the complementary imaging modalities of mammography, US and CT contribute toward the diagnosis and management of this uncommon disease.

REFERENCES

- Bannerjee SN, Ananthkrishnan N, Mehta RB. Tuberculous mastitis: a continuing problem. *World J Surg* 1987; 11:105-9.
- Hulnick DH, Naidich DP, McCauley DI. Pleural tuberculosis evaluated by computed tomography. *Radiology* 1983; 149:759-65.
- Gayler BW, Donner MW. Radiographic changes of the ribs. *Am J Med Sci* 1967; 253:586-619.
- Mathlouthi A, Ben M'Rad S, Merai S, et al. Tuberculosis of the thoracic wall. Presentation of 4 personal cases and review of the literature. *Rev Pneumol Clin* 1998; 54:182-6.
- Eid A, Chaudry N, el-Ghoroury M, et al. Multifocal musculoskeletal cystic tuberculosis without systemic manifestations. *Scand J Infect Dis* 1994; 26:761-4.
- Garcia S, Combalia A, Serra A, Segur JM, Ramon R. Unusual locations of osteoarticular tuberculosis. *Arch Orthop Trauma Surg* 1997; 116:321-3.
- Chang DS, Rafii M, McGuinness G, Jagirdar JS. Primary multifocal tuberculous osteomyelitis with involvement of the ribs. *Skeletal Radiol* 1998; 27:641-5.
- Alagaratnam TT, Ong GB. Tuberculosis of the breast. *Br J Surg* 1980; 67:125-6.
- Morris BS, Varma R, Garg A, Awasthi M, Maheshwari M. Multifocal musculoskeletal tuberculosis in children: appearances on computed tomography. *Skeletal Radiol* 2002; 31:1-8.
- Khanna R, Prasanna GV, Gupta P, et al. Mammary tuberculosis: report on 52 cases. *Postgrad Med J* 2002; 78:422-4.
- Dubey MM, Agrawal S. Tuberculosis of the breast. *J Indian Med Assoc* 1968; 51:358-9.
- Mukerjee P, George M, Maheshwari HB, Rao CP. Tuberculosis of the breast. *J Indian Med Assoc* 1974; 62:410-2.
- Faure E, Souilamas R, Riquet M, et al. Cold abscess of the chest wall: a surgical entity? *Ann Thorac Surg* 1998; 66:1174-8.
- Tatelman M, Drouillard EJP. Tuberculosis of the ribs. *Am J Roentgenol Radium Ther Nucl Med* 1953; 70:923-35.
- Hamit HF, Ragsdale TH. Mammary tuberculosis. *J R Soc Med* 1982; 75:764-5.
- Gupta R, Gupta AS, Duggal N. Tubercular mastitis. *Int Surg* 1982; 6:422-4.
- Shukla HS, Kumar S. Benign breast disorders in nonwestern populations: Part II - benign breast disorders in India. *World J Surg* 1989; 13:746-9.
- Shinde SR, Chandawarkar RY, Deshmukh SP. Tuberculosis of the breast masquerading as carcinoma: a study of 100 patients. *World J Surg* 1995; 19:379-81.
- Popli MB. Pictorial essay: tuberculosis of the breast. *Indian J Radiol Imaging* 1999; 9:127-32.
- Youk JH, Kim EK, Kim MJ, I. Imaging findings of chest wall lesions on breast sonography. *J Ultrasound Med* 2008; 27:125-38.
- Schnarkowski P, Schmidt D, Kessler M, Reiser MF. Tuberculosis of the breast: US, mammographic and CT findings. *J Comput Assist Tomogr* 1994; 18:970-1.
- Romero C, Carreira C, Cereceda C, et al. Mammary tuberculosis: percutaneous treatment of a mammary tuberculous abscess. *Eur Radiol* 2000; 10:531-3.
- Tatelman M, Drouillard EJP. Tuberculosis of the ribs. *Am J Roentgenol Radium Ther Nucl Med* 1953; 70:923-35.
- Lee G, Im JG, Kim JS, Kang HS, Han MC. Tuberculosis of the ribs: CT appearance. *J Comput Assist Tomogr* 1993; 17:363-6.
- Ward AS. Superficial abscess formation: an unusual presenting feature of tuberculosis. *Br J Surg* 1971; 58:540-3.
- Chen CH, Shih JF, Wang LS, Perng RP. Tuberculous subcutaneous abscess: analysis of seven cases. *Tuber Lung Dis* 1996; 77:184-7.