

Pseudoaneurysm of a high origin radial artery treated by ultrasound-guided compression

Esfe A R G, Bozorg S M V, Yazdi H R

ABSTRACT

A high origin of the radial artery from the brachial artery is the most frequently encountered arterial anomaly in an upper extremity, and is reported in seven percent of individuals. This variant is vulnerable to injury because of its more superficial location. A 59-year-old man developed a pseudoaneurysm following the inadvertent cannulation of a high origin radial artery. We report the successful treatment of the pseudoaneurysm by ultrasound-guided compression. Ultrasound-guided compression is an available and simple method for the repair of arterial pseudoaneurysms, and delayed complete thrombosis can be expected even if a residual flow remains after the initial compression.

Keywords: pseudoaneurysm, radial artery, radial arterial pseudoaneurysm, ultrasonography, ultrasound-guided compression

Singapore Med J 2009;50(7):e250-e252

INTRODUCTION

Ultrasound-guided compression (UGC) is a non-invasive technique for the repair of a pseudoaneurysm (PA) that has been applied widely for PAs of different arteries, especially the femoral artery.⁽¹⁻⁶⁾ However, we have not found any report on the treatment of a radial artery PA using UGC. We treated a large PA of a high origin radial artery with UGC. No complications arose, and thrombosis of the PA and the patency of the underlying radial artery were confirmed by angiography.

CASE REPORT

A 59-year-old man was referred to our department for evaluation of a pulsatile cubital fossa mass. He had been on chronic haemodialysis for 1.5 years because of chronic renal failure of unknown aetiology. His haemodialysis access was a native radiocephalic fistula, which had failed ten days prior to his hospital admission for uraemic confusion. Emergency dialysis was performed via peripheral vascular access on his left arm following

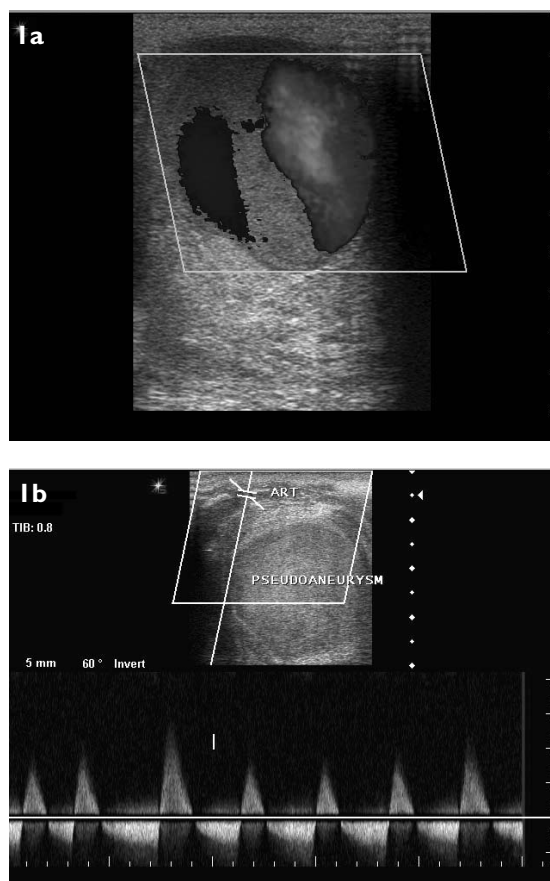


Fig. 1 Colour Doppler US image shows (a) a unilocular 60 mm × 40 mm pseudoaneurysm with a small amount of peripheral thrombosis, and (b) a characteristic to-and-fro flow in its neck, which originates from a superficial artery, proven to be a high origin radial artery.

the unsuccessful placement of a central venous catheter. After approximately half an hour of dialysis, a mass appeared at the puncture site.

We encountered this painful mass two weeks later, situated just above the cubital fossa on the anteromedial side of the distal left arm. Colour Doppler ultrasonography (US) (Siemens G40, Erlangen, Germany) revealed a unilocular 60 mm × 40 mm PA with a small amount of peripheral thrombosis and the characteristic to-and-fro flow on its neck (Figs. 1a & b). The feeding artery was a high origin radial artery incorrectly cannulated instead of the brachial artery, at the time of dialysis. The patient

Department of
Radiology and
Imaging,
Imam Khomeini
Hospital,
Keshavarz Blvd,
Tehran,
Iran

Esfe ARG, MD
Radiology Resident

Bozorg SMV, MD
Radiology Resident

Yazdi HR, MD
Associate Professor
and Consultant

Correspondence to:
Dr Hadi Rokni Yazdi
Tel: (98) 21 6119 2670
Fax: (98) 21 6691 0201
Email: rokniyaz@sina.tums.ac.ir

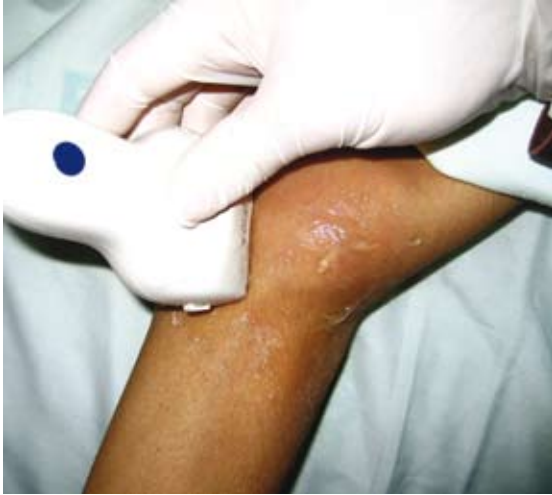

Fig. 2 Photograph of the left cubital fossa shows compression of the pseudoaneurysm neck under ultrasound guidance.

was not receiving anticoagulants, and platelet count and coagulation studies were normal. After obtaining verbal informed consent, the compression of the PA neck was applied for two 20-minute periods with a two-minute interval (Fig. 2). The distal pulse at the wrist was checked frequently by an assistant. Although compression was difficult because of the size and site of the PA, and flow did not stop completely within the pseudoaneurysm, a clot gradually filled most of the PA, and the patient became asymptomatic. Follow-up US one and four days later confirmed near complete thrombosis.

We noted a pressure effect of the thrombosed PA on the brachial and radial arteries, and also a small residue of the PA. The patient then underwent digital subtraction angiography (GE Innova, Fairfield, CT, USA) of the left upper limb, which revealed a high origin radial artery as the feeding vessel, its patency, the patency of the brachial artery and a small residual flow in the neck of the PA (Fig. 3). This residue resolved completely on follow-up colour Doppler US two weeks later.

DISCUSSION

The treatment of a PA can be either surgical or non-surgical. Surgery is indicated when the PA is infected, when it leads to a significant mass effect, e.g. when it is associated with distal ischaemia or neuropathy requiring rapid removal, and in cases of failed attempts at non-surgical treatment. Surgery may include a bypass procedure, arterial ligation and the partial or complete removal of the organ containing the PA.⁽⁷⁾ Non-surgical treatment of a PA may consist of UGC, a US-guided thrombin injection and endoluminal management.⁽⁷⁾ These procedures have been extensively evaluated for femoral artery PA,^(1,2) but there are few case reports of PAs in

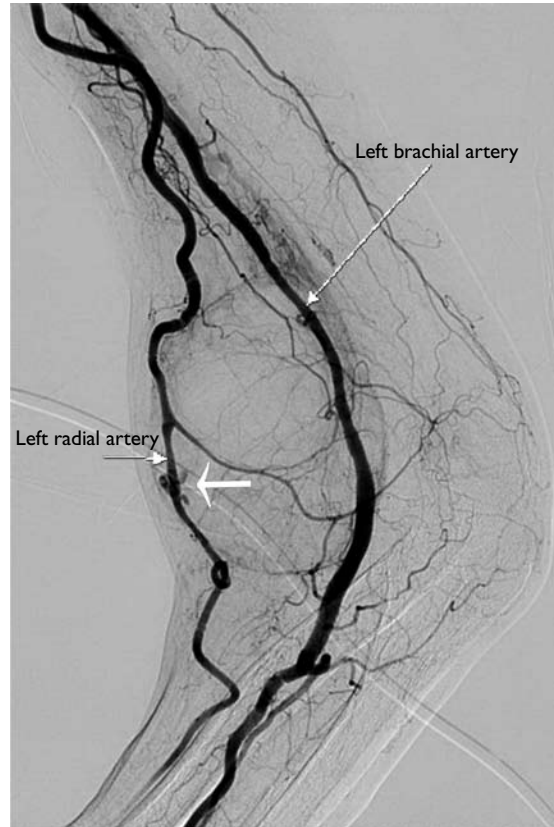


Fig. 3 Digital subtraction angiography of the left upper limb shows a high origin radial artery as the feeding vessel of the pseudoaneurysm. A small residual flow in the neck of the pseudoaneurysm (white arrow) is shown, which was resolved completely at two weeks' follow-up. The mild dilatation and tortuosity of the radial artery is due to a native radiocephalic shunt which was recently occluded.

other locations due to its rare occurrence elsewhere.⁽³⁻⁶⁾

UGC is a safe and effective approach for the treatment of a femoral artery PA,⁽²⁾ and has even been reported to be used in cases of a ruptured PA.⁽⁸⁾ It is also simple and more widely available than other techniques. Typically, the PA neck is compressed for 10–20 minutes in order to eliminate the flow within the PA, and this can be repeated for up to one hour. Pressure may be exerted on the entire PA if compression of the neck is not possible. Perfusion of the limb should not be compromised. The risk factors for failure are a large size (> 4 cm) PA and concomitant anticoagulant therapy.^(6,7) Thus, before the procedure, anticoagulants should be discontinued, if possible. Complications are rare, and failure rates of 15%–38% have been reported.⁽⁷⁾

A US-guided thrombin injection consists of a continuous injection of thrombin via a needle placed in the centre of the PA sac, until the cessation of flow in it. The most commonly-used concentration of thrombin is 1,000 IU/ml, and usually 0.5–1.0 ml is required. It can be used for both superficial and deep visceral arteries. The reported success rate for a post-catheterisation PA

is 90% and the complication rate is 4%. Complications may include thromboembolism (following the entrance of thrombin into the arterial system) and allergic reactions.⁽⁷⁾

Endoluminal management includes embolisation and stenting. If the donor artery is expendable, embolisation of the donor artery alone is suitable, otherwise a stent graft placement or embolisation with a stent or balloon remodelling is required.⁽⁷⁾ Because of the superficial location of the PA in our case, the first choice of treatment was either UGC or a US-guided thrombin injection. Our case is notable because UGC was performed successfully despite anatomical constraints which limit the compression of the PA neck (the radial artery is smaller and more mobile than the femoral artery), the large size of the PA, the inability to completely cease flow in the PA during compression, and the delayed complete thrombosis of the PA, indicating that the persistence of flow at the termination of the procedure does not necessarily mean failure.

To our knowledge, this is the first reported case of a high origin radial artery PA treated with UGC. A high origin of the radial artery from the brachial artery is the most frequently encountered arterial anomaly in an upper extremity, having been reported in 7% of individuals.⁽⁹⁾ This may result in a more superficial location of the artery, making it more vulnerable to injury and more prone to an inadvertent drug injection or cannulation. The consideration of this possibility is also important for

an evaluation of upper extremity penetrating trauma and during vascular surgical procedures of the upper limb, such as the construction of haemodialysis fistula and cases of traumatic amputation or replantation.

REFERENCES

1. Steinkamp HJ, Werk M, Felix R. Treatment of postinterventional pseudoaneurysms by ultrasound-guided compression. *Invest Radiol* 2000; 35:186-92.
2. Eisenberg L, Paulson EK, Kliwer MA, et al. Sonographically guided compression repair of pseudoaneurysms: further experience from a single institution. *Am J Roentgenol* 1999; 173:1567-73.
3. Szendro G, Goleman L, Klimov A, et al. Successful non-surgical management of traumatic pseudoaneurysm of the axillary artery by duplex guided compression obliteration. *Eur J Vasc Endovasc Surg* 1997; 13:513-4.
4. Kehoe ME. US-guided compression repair of a pseudoaneurysm in the brachial artery. *Radiology* 1992; 182:896.
5. Skibo L, Polak JF. Compression repair of a postcatheterization pseudoaneurysm of the brachial artery under sonographic guidance. *Am J Roentgenol* 1993; 160:383-4.
6. Witz M, Werner M, Bernheim J, et al. Ultrasound-guided compression repair of pseudoaneurysms complicating a forearm dialysis arteriovenous fistula. *Nephrol Dial Transplant* 2000; 15:1453-4.
7. Saad NE, Saad WE, Davies MG, et al. Pseudoaneurysms and the role of minimally invasive techniques in their management. *Radiographics* 2005; 25 Suppl 1:S173-89.
8. Beer M, Beissert M, Sandstede J, et al. Compression repair of ruptured pseudoaneurysms guided by color Doppler ultrasonography: report of two cases. *J Ultrasound Med* 2001; 20:409-12.
9. Uglietta JP, Kadir S. Arteriographic study of variant arterial anatomy of the upper extremities. *Cardiovasc Intervent Radiol* 1989; 12:145-8.