

Metastatic renal cell carcinoma presenting as a breast lump in a treated breast cancer patient

Durai R, Ruhomaully S N, Wilson E, Hoque H

ABSTRACT

Metastatic malignancy in the breast is uncommon. A 68-year-old woman with a past medical history of breast cancer presented with a lump in the opposite breast. A mammogram suggested a possible benign lump. An ultrasonography-guided core needle biopsy was taken to complete the triple assessment. The histology on the breast core biopsy showed it to be a metastatic renal cell carcinoma. Subsequent computed tomography of the abdomen confirmed a renal primary tumour. The patient was referred to the renal oncologist for palliative treatment.

Keywords: breast mass, breast metastatic tumour, breast neoplasm, metastasis, renal cell carcinoma

Singapore Med J 2009;50(8):e277-e279

INTRODUCTION

The commonest breast malignancy is a primary breast cancer. Rarely, the breast can be a site of metastatic spread.^(1,2) We describe a patient with a past medical history of carcinoma of the breast presenting with a breast lump on the opposite side. Although the lump appeared benign radiologically, the histology showed it to be a metastatic renal cell carcinoma. Subsequent computed tomography (CT) confirmed a renal primary tumour. The aim of this article is to increase awareness of secondaries to the breast.

CASE REPORT

A 68-year-old woman presented in 2008 with a one-week history of a lump in her left breast. Her past medical history included carcinoma of the right breast (T2N0MX) for which she had undergone a wide local excision and level III axillary node clearance in 1996. This was followed by radiotherapy to the breast and a five-year course of tamoxifen. Examination confirmed a 2 cm × 1 cm firm, non-tender lump underneath the left areola at the 6 o'clock position, which was clinically benign. A mammogram showed a parenchymal deformity in the

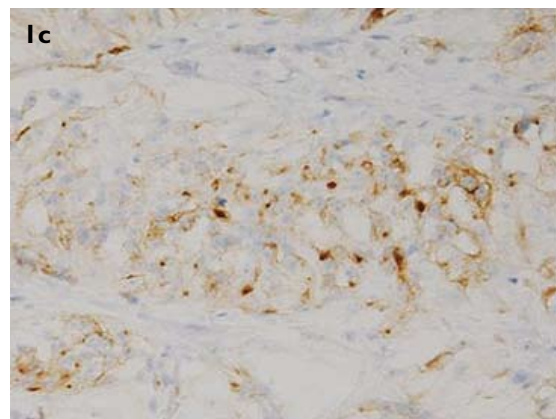
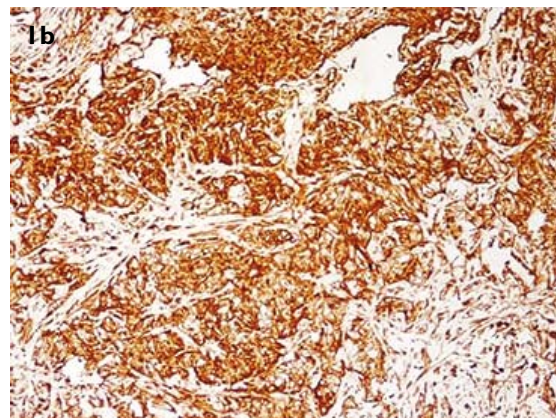
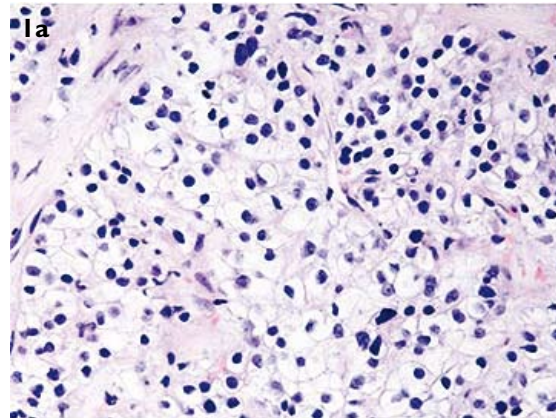


Fig.1 Photomicrographs show (a) tumour cells with clear cytoplasm (Haematoxylin & eosin, × 30). The tumour cells were positive for (b) vimentin (× 10) and (c) CD10 (× 10).

upper outer quadrant of the right breast, consistent with scarring from the previous operation. On the oblique view

Department of
Surgery,
Queen Mary's
Hospital,
Froggnal Avenue,
Sidcup,
Kent DA14 6LT,
The United Kingdom

Durai R, MD, MRCS
Specialist Registrar

Ruhomaully SN, FRCS
Consultant

Hoque H, FRCS
Consultant

Department of
Pathology

Wilson E, FRCPath
Consultant

Correspondence to:
Mr Rajaraman Durai
Department of Surgery,
University Hospital
Lewisham,
Lewisham High Street,
London SE13 6LH,
The United Kingdom
Tel: (44) 20 8530 6277
Fax: (44) 20 8333 3333
Email: dr_durai@
yahoo.com

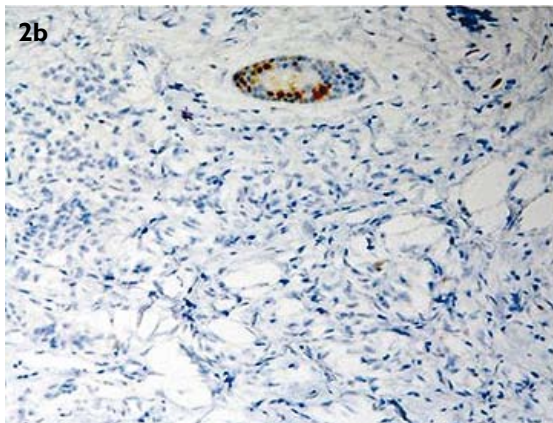
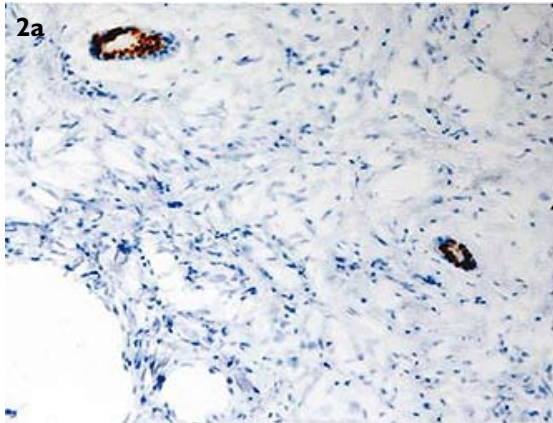


Fig. 2 Photomicrographs show that the tumour was histologically negative for (a) oestrogen receptors (ER -ve) ($\times 10$) and (b) progesterone receptors (PR -ve) ($\times 10$). Normal breast ducts show nuclear staining which serves as internal control.

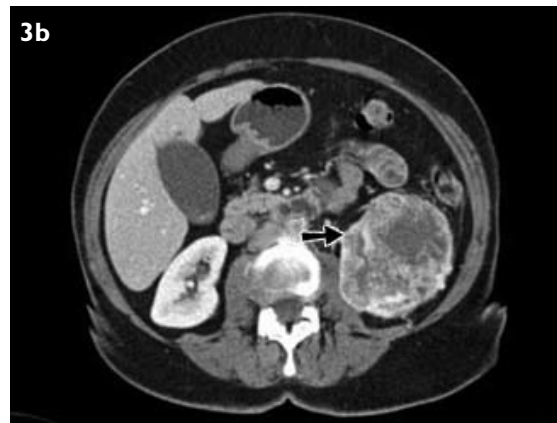
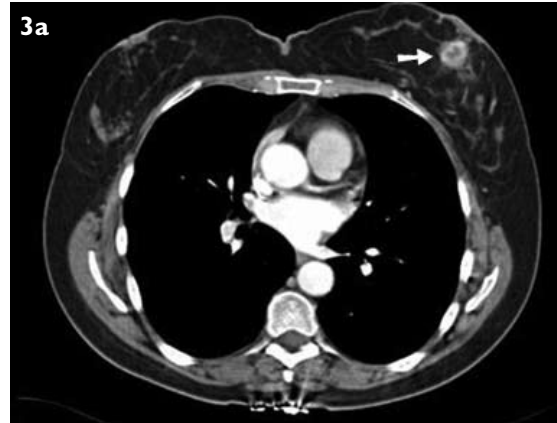
Fig. 3 Axial CT images show (a) a tumour in the left breast (arrow) and (b) a tumour of the left kidney.

of the left breast, there was a discrete soft tissue mass in the inferior aspect. This was reported as radiologically benign. Ultrasonography (US) of the left breast showed indeterminate features, and an US-guided core needle biopsy of the lump was performed.

Imprint cytology from the core biopsy was reported as benign. Histology of the core biopsy sample was reported as malignant. It revealed breast tissue infiltrated by large areas of cohesive tumour cells in alveolar groups. The tumour cells had clear cytoplasm that was positive on periodic acid-Schiff stain, indicating glycogen content. They also had slightly enlarged, low-grade nuclei (Fig. 1). They were positive for CD56 but negative for two other neuroendocrine markers (chromogranin and synaptophysin). The tumour cells were focally weakly positive for CD10, and strongly positive for vimentin (Fig. 1). Immunohistochemistry showed that the tumour cells were negative for oestrogen receptors (ER), progesterone receptors (PR) (Fig. 2), E-cadherin, CK7, CK20 and CD68, and for myoepithelial markers p63, SMA and calponin. The morphology and immunoprofile were that of a metastatic renal clear cell carcinoma.

When the patient was reviewed in the clinic, she did not have any abdominal or urinary symptoms, and her abdomen was clinically unremarkable. CT confirmed a 2-cm mass in the subcutaneous tissue of the left breast and an 8-cm left renal mass (Fig. 3). Five pulmonary nodules were identified on the right, in both upper and lower lobes. The largest nodule measured 7 mm. Two pulmonary nodules were identified at the left base, the larger of which measured 1.5 cm. A small pulmonary embolus (PE) was identified in the right upper lobe. There was a 1.2-cm left hilar node. Multiple simple liver cysts were noted. In addition, two metastases were noted in liver segments 4b and segment 5/6 which were each 3 cm in size. There was an 11-mm focal lesion in the spleen with soft tissue attenuation. There was a 1-cm left para-aortic lymph node at the level of the renal vessels and a 4.5-cm left adrenal mass. In summary, CT showed a metastatic renal tumour and a PE. The patient was treated with low-molecular-weight heparin and warfarin for the PE. The case was discussed in the multidisciplinary meeting, and the patient was referred to the regional renal oncologist for consideration of chemotherapy.

DISCUSSION

Secondary deposits account for 0.4%–6% of breast malignancy. Reported primary tumours that spread to the breast include melanoma, kidney,^(3,4) stomach, uterine leiomyosarcoma,⁽⁵⁾ vulval carcinoma,⁽⁶⁾ lung carcinoma,⁽⁷⁾ colon cancer⁽⁸⁾ and neuroendocrine tumours. Renal cell carcinoma is notorious for its spread, partly because of its increased vascularity. Breast metastasis from a renal cancer is rare,⁽⁹⁾ and has been reported as the first manifestation of the disease. The metastasis can appear many years after nephrectomy.⁽³⁾ Secondaries in the breast commonly arise from haematogenous spread. Renal oncocytoma is also known to spread to the breast. Breast cancer can also spread to the kidneys.⁽¹⁰⁾ Triple assessment should be performed in all breast lumps. In the case of breast metastasis, fine-needle aspiration cytology will show atypical cells which are different when compared to a primary breast cancer.⁽¹¹⁾ If a biopsy is not performed, then one may miss the diagnosis. ER and PR negativity raises the possibility of a metastasis. Immunohistochemistry will help to characterise the primary tumour.

This patient presented with a left-sided breast lump and a past medical history of breast cancer on the right breast. Imaging and histology confirmed it to be a metastatic renal cancer. The mammograms, US and imprint cytology were reported as benign or indeterminate, and represented false negatives. The benign imprint cytology may reflect the low-grade tumour cell nuclei seen on histology. A cure is unlikely with metastatic renal

malignancy and palliative chemotherapy may be the only option. If there is only a single-site breast metastasis and none elsewhere, both the primary and secondary tumours may be excised, followed by suitable adjuvant therapy, and the patient should be treated in a specialist centre dealing with renal cancers.

REFERENCES

1. Lee WK, Cawson JN, Hill PA, Hoang J, Rouse H. Renal cell carcinoma metastasis to the breast: mammographic, sonographic, CT, and pathologic correlation. *Breast J* 2007; 13:316-7.
2. O'Sullivan AW, Kelly PM, Smith JM, Gorey TF. Renal cell carcinoma metastasis to breast. *Ir J Med Sci* 2003; 172:48.
3. Forte A, Peronace MI, Gallinaro LS, et al. Metastasis to the breast of a renal carcinoma: a clinical case. *Eur Rev Med Pharmacol Sci* 1999; 3:115-8.
4. McLaughlin SA, Thiel DD, Smith SL, Wehle MJ, Menke DM. Solitary breast mass as initial presentation of clinically silent metastatic renal cell carcinoma. *Breast* 2006; 15:427-9.
5. Hsiao HH, Liu YC, Hou MF, Lin SF. Uterine leiomyosarcoma metastasis to the breast. *Eur J Gynaecol Oncol* 2008; 29:191-2.
6. Khouchani M, Benchakroun N, Tahri A, et al. [Breast metastasis from vulvar carcinoma: case report and review of literature]. *Cancer Radiother* 2008; 12:120-5. French.
7. Lee AH. The histological diagnosis of metastases to the breast from extramammary malignancies. *J Clin Pathol* 2007; 60:1333-41.
8. Ho YY, Lee WK. Metastasis to the breast from an adenocarcinoma of the colon. *J Clin Ultrasound* 2009; 37:239-41.
9. Alzaraa A, Vodovnik A, Montgomery H, Saeed M, Sharma N. Breast metastasis from a renal cell cancer. *World J Surg Oncol* 2007; 5:25.
10. Gacci M, Orzalesi L, Distanti V, et al. Renal cell carcinoma metastatic to the breast and breast cancer metastatic to the kidney: two rare solitary metastases. *Breast J* 2005; 11:351-2.
11. Kannan V. Fine-needle aspiration of metastatic renal-cell carcinoma masquerading as primary breast carcinoma. *Diagn Cytopathol* 1998; 18:343-5.