

Juxtarenal/pararenal Wilms' tumour in a six-year-old Malay girl

Ngan K W, Shaari S, Subramaniam T

ABSTRACT

We report a six-year-old Malay girl who presented with a right retroperitoneal tumour that measured 7.5 cm in diameter. A wide excision of the lesion was performed. The tumour was separated from a normal-appearing right kidney by a capsule. Microscopically, this well-encapsulated tumour was composed of classical triphasic components: epithelial, mesenchymal and blastemal areas. The immunohistochemical study showed WT1 expression in the blastemal area. Thus, a diagnosis of Wilms' tumour with favourable histology was made. The patient was well for 12 months. Extrarenal Wilms' tumour is uncommon, with the majority of cases occurring in the retroperitoneal and inguinal areas. Wilms' tumour that is not arising from the intrarenal area but shares a common capsule with the ipsilateral kidney, is even rarer. Indeed, our case would be more appropriately classified as juxtarenal/pararenal Wilms' tumour. Despite its rarity, an extrarenal or even juxtarenal/pararenal Wilms' tumour should be included in the differential diagnosis of retroperitoneal tumour.

Keywords: extrarenal Wilms' tumour, juxtarenal Wilms' tumour, pararenal Wilms' tumour, retroperitoneal tumour, Wilms' tumour

Singapore Med J 2009;50(9):e329-e331

INTRODUCTION

Extrarenal Wilms' tumour (WT) is a rare entity. The majority of the cases occur in the retroperitoneal and inguinal areas.⁽¹⁾ We present another case which would be more appropriately classified as juxtarenal/pararenal WT.

CASE REPORT

A six-year-old Malay girl presented with abdominal pain for five days prior to admission. The preoperative diagnosis was perforated acute appendicitis. Upon surgery, a right retroperitoneal tumour adjacent to the right kidney was noted. It was at the inferior pole of the kidney and separated from the normal-appearing right

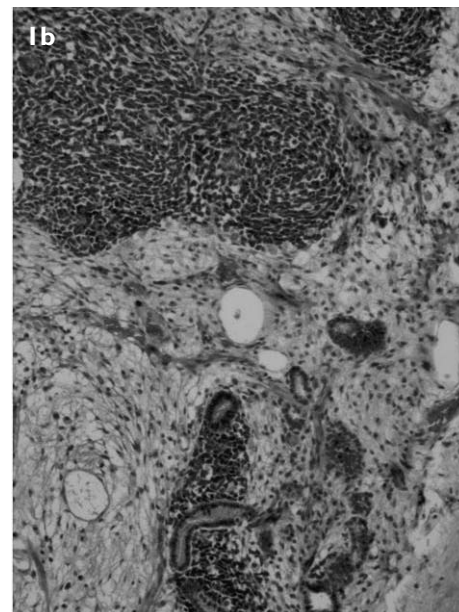
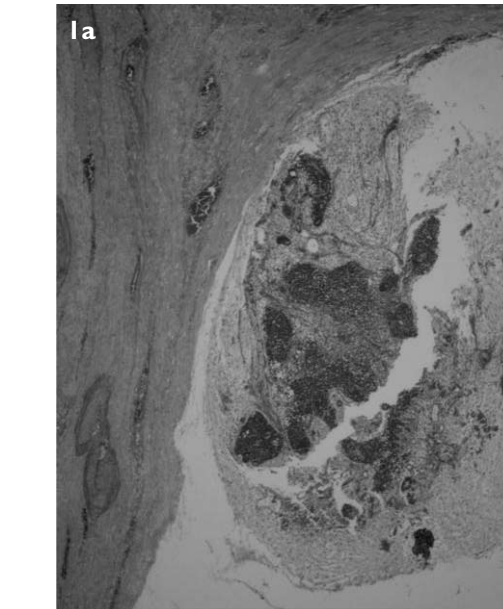


Fig. 1 Photomicrographs show (a) the tumour rimmed by a thick fibrous capsule (left) (Haematoxylin & eosin, $\times 25$); and (b) blastemal cell nests with or without epithelial components (Haematoxylin & eosin, $\times 100$).

kidney by a capsule. A wide excision of the tumour was performed. This well-circumscribed and encapsulated mass measured 7.5 cm in greatest diameter. Its cut surface was variegated, soft and fragile. The tumour showed extensive haemorrhage and necrosis, with a viable

Department of
Pathology,
Serdang Hospital,
Jalan Puchong,
Kajang 43000,
Malaysia

Ngan KW, MD
Pathologist

Shaari S, MPath
Senior Pathologist

Department of
General Surgery

Subramaniam T,
MBBS, MS
Senior Consultant

Correspondence to:
Dr Ngan Kah Wai
Tel: (60) 3 8947 5555
ext 1685
Fax: (60) 3 8947 5210
Email: ngan751@
hotmail.com.tw

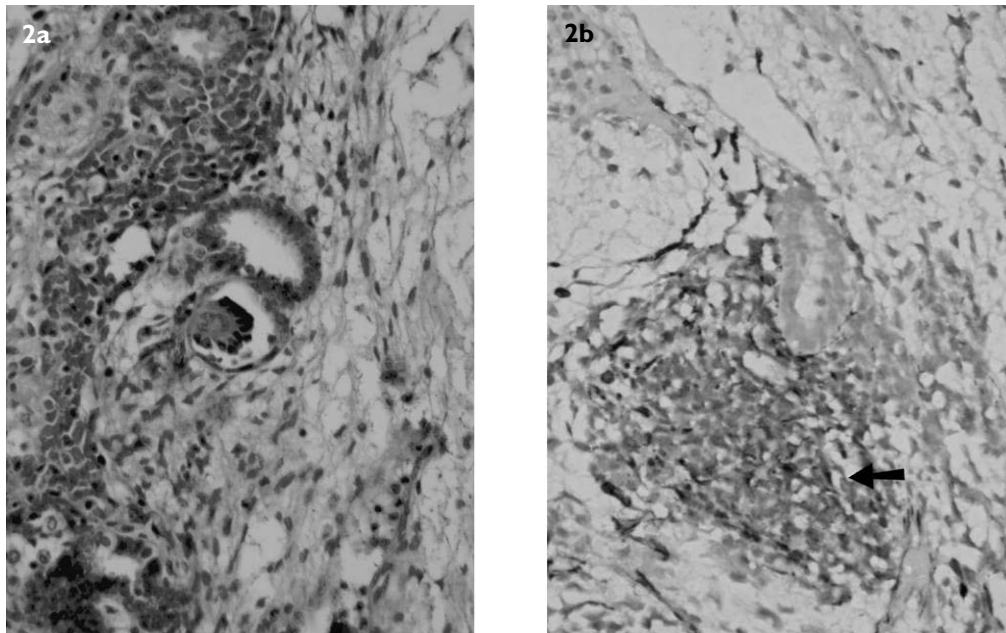


Fig. 2 (a) Photomicrograph taken at a higher magnification shows primitive renal tubules and glomerular structure surrounded by hyperchromatic blastemal cells (Haematoxylin & eosin, $\times 200$). (b) Photomicrograph shows the blastemal cells (arrow) are immunoreactive for WT1 stain (Immunostain, $\times 200$).

Table I. Summary of reported cases of juxtarenal/pararenal Wilms' tumour.

Study	Age (month)	Gender	Site	Histology	Stage	Follow-up (months)
Andrew et al ⁽¹⁶⁾	NA	Male	Adjacent to right kidney	F	II	7, NED
	NA	Male	Adjacent to left kidney	F	IV	24
	NA	Female	Adjacent to right kidney	F	I	33, NED
Wakely et al ⁽¹⁷⁾	21	Female	Adjacent to right kidney	F	NA	72, NED
	48	Female	Adjacent to right kidney	F	NA	60, NED
	48	Male	Adjacent to right kidney	F	NA	72, NED
Current case	72	Female	Adjacent to right kidney	F	I	12, NED

NA: not available; F: favourable histology; NED: no evidence of disease

portion found at the peripheral rim. Microscopically, this tumour showed classical triphasic components: epithelial, mesenchymal and blastemal areas (Figs.1 and 2a). There was no teratomatous component. The immunohistochemical study showed WT1 expression in the blastemal area (Fig. 2b). A diagnosis of WT with favourable histology was made. The postoperative imaging of both kidneys was unremarkable. There was no evidence of recurrence after 12 months of follow-up.

DISCUSSION

Extrarenal WT is rare. According to Sastri et al, there have been 48 well-documented cases and they added another three.⁽¹⁾ Since then, a few more cases have been described in the English language literature.⁽²⁻⁷⁾ Other than the retroperitoneal and inguinal regions, the reported extrarenal sites are mediastinal,⁽⁸⁾ chest wall,⁽⁹⁾ lumbosacral,^(10,11) sacrococcygeal,⁽¹²⁾ presacral regions,⁽⁷⁾

and both the male and female genital tracts.⁽¹⁾ Currently, no characteristic imaging findings are available to diagnose extrarenal WT preoperatively;⁽⁷⁾ the diagnosis could only be made postoperatively.^(1,7,8,13) The differential diagnoses include primary intrarenal tumour with metastasis to the extrarenal site, supernumerary kidney, teratoma with a component of WT, and other primitive mesenchymal tumours. The first two diseases can be excluded by image study and intraoperatively. An adequate sampling is important to exclude teratoma with a component of WT. In addition, immunoreaction to the WT1 protein, confined to the nuclei, is present in the areas of blastemal component and early epithelial differentiation. The presence of WT1 expression in primitive tumour supports the diagnosis of WT.⁽¹⁴⁾

Theories regarding the origin of extrarenal WT remain controversial. Many believe that extrarenal WT arises from heterotopic metanephric blastema cells, and

is similar to renal WT.^(14,15) However, there is no report in the literature that documents the presence of extrarenal metanephric blastema in the retroperitoneum of the foetus.⁽¹⁶⁾ Another possible mechanism is the tumour is derived from the immature mesodermal elements, probably the mesonephric duct remnants.⁽¹⁶⁾ WT not arising from the intrarenal region, but shares a common capsule with the ipsilateral kidney, was regarded as extrarenal WT in most reports.^(16,17) Reported cases since 1981 are summarised in Table I. It has been suggested by some authors that “juxtarenal” or “pararenal” WT would be the more appropriate terms to describe these tumours, after ruling out supernumerary kidney. For cases of juxtarenal/pararenal WT, it is believed that the tumour arises from the extrusion of the subcapsular metanephric blastema.^(14,16) Our case could not provide convincing evidence to confirm this pathogenesis as nephrectomy was not performed. It would be more informative if the presence of nephroblastomatosis could be demonstrated in the renal parenchyma.

As with other reports, the diagnosis of extrarenal WT in our case was made after the surgery. The role of the frozen section has not been discussed in previous reports. In summary, despite its rarity, an extrarenal or even juxtarenal/pararenal WT should be included in the differential diagnosis of a retroperitoneal tumour. Currently, the principle of treatment of extrarenal and juxtarenal/pararenal WT is to follow the National Wilms’ Tumor Study protocols for intrarenal WT. The case numbers of juxtarenal/pararenal WT are too small to see the exact difference in prognosis. Perhaps a precise tumour classification coupled with the documentation of more cases would be beneficial for the analysis of the mortality rate data.

REFERENCES

- Sastri J, Dedhia R, Laskar S, et al. Extra-renal Wilms’ tumor – is it different? *Pediatr Nephrol* 2006; 21:591-6.
- Ratnam GV, Abu-Eshy S, Morad N, Almutawa AM. Adult extrarenal Wilms’ tumour: A case report and review of literature. *West Afr J Med* 2006; 25:75-8.
- Apoznanski W, Sawicz-Birkowska K, Pietras W, Dorobisz U, Szydelko T. Extrarenal Wilms tumour. *Eur J Pediatr Surg* 2005; 15:53-5.
- Sharma MC, Sarat Chandra P, Goel S, Gupta V, Sarkar C. Primary lumbosacral Wilms tumor associated with diastematomyelia and occult spinal dysraphism. A report of a rare case and a short review of literature. *Childs Nerv Syst* 2005; 21:240-3.
- Houben CH, Tong JH, Chan AW, et al. Familial extrarenal Wilms tumor. *J Pediatr Surg* 2007; 42:1826-30.
- García-Galvis OF, Stolnicu S, Muñoz E, et al. Adult extrarenal Wilms tumor of the uterus with teratoid features. *Hum Pathol* 2009; 40:418-24.
- Jia HM, Zhang KR, Shu H, Tian BL, Wang WL. Presacral extrarenal Wilms tumor in a child. *Urology* 2009; 74:308-10.
- Moyson F, Maurus-Desmarez R, Gompel C. [Mediastinal Wilms’ Tumour?] *Acta Chir Belg* 1961; suppl 2:118-28. French.
- Madanat F, Osborne B, Cangir A, Sutow WW. Extrarenal Wilms tumor. *J Pediatr* 1978; 93:439-43.
- Fahner JB, Switzer R, Freyer DR, Mann JD, Mann RJ. Extrarenal Wilms’ tumor. Unusual presentation in the lumbosacral region. *Am J Pediatr Hematol Oncol* 1993; 15:117-9.
- Arda IS, Tuzun M, Demirhan B, Sevmis S, Hicsonmez A. Lumbosacral extrarenal Wilms’ tumor: a case report and literature review. *Eur J Pediatr* 2001; 160:617-9.
- Ward SP, Dehner LP. Sacrococcygeal teratoma with nephroblastoma (Wilm’s tumor): a variant of extragonadal teratoma in childhood. A histologic and ultrastructural study. *Cancer* 1974; 33:1355-63.
- Deshpande AV, Gawali JS, Sanghani HH, et al. Extrarenal Wilms’ tumor- a rare entity. *Pediatr Surg Int* 2002; 18:543-4.
- Murphy WM, Grignon DJ, Perlman EJ. Tumors of the kidney, bladder and related urinary structures. In: *Atlas of Tumor Pathology*. 4th series. Fascicle 1. Washington DC: Armed Forces Institute of Pathology, 2004; 101-240.
- Bernnington JL, Beckwith JB. Tumors of the kidney, renal pelvis and ureter. In: *Atlas of Tumor Pathology*. 2nd series. Fascicle 12. Washington DC: Armed Forces Institute of Pathology, 1975; 31-59.
- Andrews PE, Kelalis PP, Haase GM. Extrarenal Wilms’ tumor: results of National Wilms’ Tumor Study. *J Pediatr Surg* 1992; 27:1181-4.
- Wakely PE Jr, Sprague RI, Kornstein MJ. Extrarenal Wilms’ tumor: an analysis of four cases. *Hum Pathol* 1989; 20:691-5.