

# Scrotal pyoderma gangrenosum associated with Crohn's disease

Ho S A, Tan W P, Tan A W, Wong S N, Chua S H

## ABSTRACT

**Scrotal pyoderma gangrenosum is uncommon. We present a 17-year-old Chinese male patient with newly diagnosed Crohn's disease presenting with scrotal pyoderma gangrenosum. Biopsy and other investigations were done to diagnose and look for associated diseases of pyoderma gangrenosum. Treatment with high-dose prednisolone failed. Subsequent treatment with oral cyclosporine was successful.**

**Keywords:** Crohn's disease, cyclosporine, infliximab, scrotal pyoderma gangrenosum

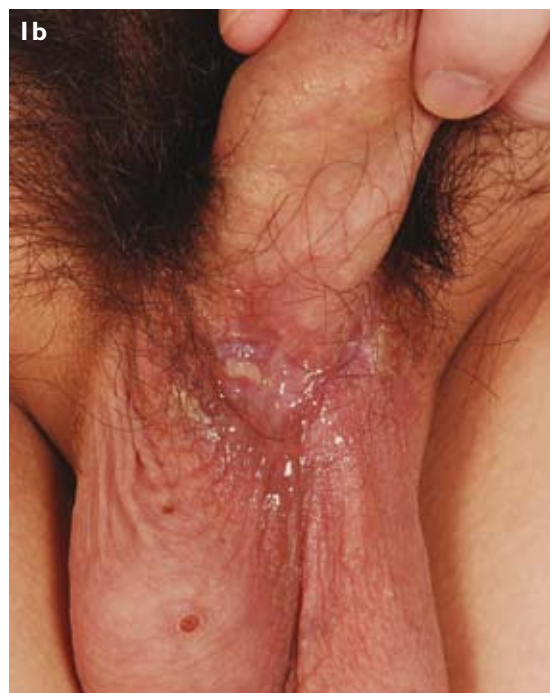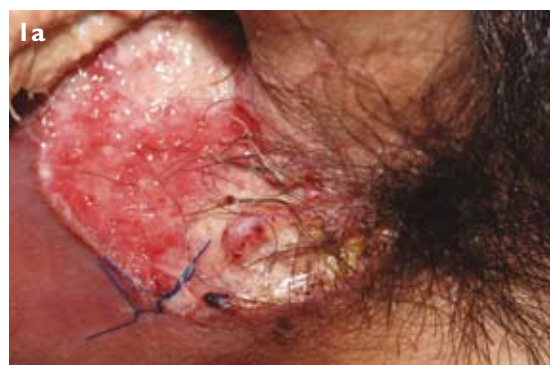*Singapore Med J 2009;50(12):e397-e400*

## INTRODUCTION

Pyoderma gangrenosum (PG) is a neutrophilic dermatosis characterised by recurrent painful cutaneous ulcerations. It is frequently associated with inflammatory bowel disease, rheumatoid arthritis and haematological disorders.<sup>(1-4)</sup> Diagnosis is based on a history of underlying disease, evolving clinical features and exclusion of other diseases that would present with ulceration.<sup>(3,4)</sup> The mainstay of treatment is immunosuppression,<sup>(1,4,5)</sup> and the most commonly used drugs are corticosteroids and cyclosporine.<sup>(5)</sup> We present a case of scrotal pyoderma gangrenosum associated with inflammatory bowel disease that was refractory to high-dose steroids and treated with oral cyclosporine. However, as the bowel symptoms persisted, the patient was offered therapeutic surgical intervention. The site of occurrence is rare. A literature review of the treatment of pyoderma gangrenosum in association with Crohn's disease is also presented.

## CASE REPORT

A 17-year-old Chinese man presented with a painful scrotal ulcer of 2–3 months' duration. It had started as a papule that ulcerated and progressively enlarged. He recounted a previous episode of a small scrotal ulceration about one year ago, which had then healed spontaneously. No other skin or mucosal abnormalities was detected. The patient also gave a history of four episodes of passing stools mixed with blood four



**Fig. 1** Photographs show (a) a sloughy tender ulcer with erythematous edges and undermined borders at the anterior aspect of the scrotum, and (b) reepithelialisation of the ulcer one month after starting oral cyclosporine.

months prior to presentation. In addition, he had been experiencing episodic frequent loose stools over the past two years. At the time of presentation, his bowel symptoms were quiescent. He did not have any joint or eye complaints and has never had sexual intercourse. On examination, there was a 3-cm sloughy tender ulcer with erythematous edges and undermined borders on the anterior scrotal wall (Fig. 1a). Systemic examination did not reveal any abnormalities, and no skin lesion was seen at the previous venepuncture sites to suggest

**National Skin Centre,  
1 Mandalay Road,  
Singapore 308205**

Ho SA, MBBS  
Medical Officer

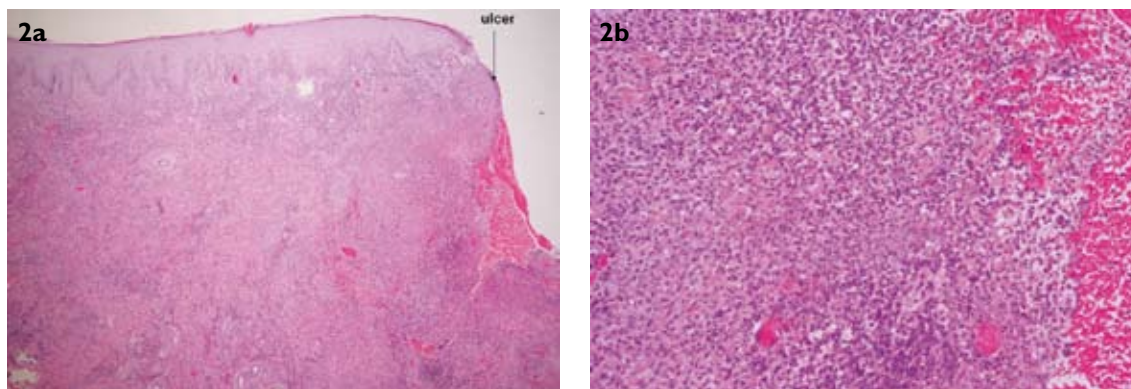
Tan WP, MBBS,  
MRCP  
Associate Consultant

Tan AW, MBBS,  
MRCP, FAMS  
Consultant

Wong SN, MBBS,  
MRCP, Dip Derm  
Senior Consultant

Chua SH, MBBS,  
FRCP, FAMS  
Senior Consultant

**Correspondence to:**  
Dr Sue-Ann Ho  
Tel: (65) 9830 2853  
Email: dechild@  
gmail.com



**Fig. 2** Photomicrographs show (a) epidermal ulceration with surface fibrinopurulent debris (Haematoxylin & eosin,  $\times 40$ ), and (b) diffuse suppurative dermatitis and secondary vasculitis (Haematoxylin & eosin,  $\times 400$ ).

positive pathology. There was no lymphadenopathy.

A punch biopsy done showed epidermal ulceration with surface fibrinopurulent debris (Fig. 2). There were superficial and deep dermal infiltrates of the lymphocytes, plasma cells, histiocytes and polymorphs, and a secondary lymphocytic vasculitis. Periodic acid-Schiff and Ziehl-Neelson stains did not show any organisms. Fungal smears, acid-fast bacilli smears and cultures, herpes simplex virus culture, rapid plasma reagin, human immunodeficiency virus (HIV) serology and blood culture were all negative. Pyogenic culture from the ulcer isolated *Staphylococcus aureus*, for which he was treated with a course of augmentin. His full blood count showed a mildly-elevated total white cell count at  $14.1 \times 10^9/L$ , with normal haemoglobin and platelet counts. The erythrocyte sedimentation rate and C-reactive protein level were both elevated.

In view of the patient's bowel symptoms, he was referred to a gastroenterologist. Colonoscopy showed an abnormal-looking caecum with inflammation and nodularity. Caecal and transverse colon biopsies showed focal active colitis with ulceration and no granulomas, organisms or evidence of malignancy. Oesophageoduodenoscopy and small bowel enema were normal. These endoscopic findings were consistent with Crohn's disease. Computed tomography of the gut confirmed findings that were compatible with Crohn's disease. Rheumatoid factor, anti-neutrophilic cytoplasmic antibodies, anti-nuclear antibody and hepatitis markers were normal. No monoclonal gammopathy was detected on protein electrophoresis. The Mantoux test was negative.

Our patient was diagnosed with PG associated with Crohn's disease. Despite one week of high-dose prednisolone of 1 mg/kg/day, he did not have any improvement of symptoms or reepithelialisation of the ulcer. He was then commenced on cyclosporine

2 mg/kg/day. After one month of treatment with cyclosporine, significant reepithelialisation of the ulcer was seen (Fig. 1b). Three months after the initial presentation, he had a flare-up of bowel symptoms and was started on azathioprine in combination with high-dose prednisolone. Despite this, his colitis remained poorly controlled, with active ulceration and fistulae formation. He was offered an option of infliximab or a right hemicolectomy, of which he chose the latter. Of note, his PG remained quiescent despite the flare-up of gastrointestinal disease.

## DISCUSSION

PG commonly presents between the second and the fifth decades of life. About 4% of cases occur in infants and adolescents.<sup>(3)</sup> Other than classical PG, recognised clinical variants of PG include the bullous, pustular, vegetative and peristomal variants.<sup>(5)</sup> They differ based on their clinical presentation, site and associated diseases.<sup>(4)</sup> The differential diagnosis of PG include vasculitis such as Wegener's disease, venous diseases including calciphylaxis, cutaneous and haematological malignancies, infectious diseases (bacterial, mycobacterial or fungal), trauma and drug reactions.<sup>(3)</sup> Aside from these, in particular for scrotal ulcers, the differential should also include Behçet's disease. Direct immunofluorescence as an additional tool may help exclude vasculitis; however, it can be negative in 20%–40% of cases. Juvenile gangrenous vasculitis, a scrotal ulcer of unknown origin, characterised by acute onset exclusively affecting young patients below 30 years of age, has been hypothesised to be part of the PG spectrum.<sup>(6)</sup>

Scrotal and penile PG are rare,<sup>(7)</sup> with even fewer case reports on scrotal PG. Genital and buttock PG present more in the infantile age group than in other age groups.<sup>(8)</sup> We considered the differential of Behçet's disease in

**Table I. Common and uncommon associations in pyoderma gangrenosum.**

## Common associations

- **Inflammatory bowel diseases:** Ulcerative colitis, Crohn's disease.
- **Arthritis:** Seropositive and seronegative rheumatoid arthritis, seronegative spondyloarthritis.
- **Haematological malignancies:** Acute myeloid leukaemia, myelodysplasia and monoclonal gammopathies.

## Less common associations

- **Gastrointestinal-related diseases:** Diverticulosis, gastritis, gastric or duodenal ulcer, gastric adenocarcinoma, intestinal polyp.
- **Hepatobiliary-related diseases:** Chronic active hepatitis, hepatitis C and cryoglobulinaemia, autoimmune hepatitis, primary biliary cirrhosis, sclerosing cholangitis.
- **Haematological disorders:** Myeloproliferative diseases, lymphoma, other leukaemias (chronic myeloid, lymphoid, hairy cell leukaemia), myeloma, Waldenström syndrome, congenital hypogammaglobulinaemia, afibrinogenemia, thrombocythaemia, autoimmune neutropenia, paroxysmal nocturnal haemoglobinuria, splenomegaly.
- **Joint-related diseases:** Juvenile rheumatoid arthritis, osteoarthritis, polychondritis, familial recurrent arthritis – PAPA\* syndrome.
- **Rheumatological-related diseases:** Takayasu's arteritis, Cogan's syndrome, lupus erythematosus, antiphospholipid syndrome, systemic sclerosis, Wegener's granulomatosis.
- **Neoplasia:** Colon, prostate, breast, bronchial or parotid cancer, carcinoid tumour.
- **Drugs:** Granulocyte colony-stimulating factor – pegfilgrastim, interferon, propylthiouracil, cocaine.
- **Other neutrophilic dermatosis:** Subcorneal pustular dermatosis, Sweet's syndrome, erythema elevatum diutinum, Behçet's disease.
- **Others:** Aseptic pulmonary nodules, human immunodeficiency viral infection, immunosuppression, post-caesarian delivery, retinoid treatment of acne, acne conglobata, hidradenitis suppurativa, chronic recurrent multifocal osteomyelitis.

Adapted from Reichrath et al,<sup>(2)</sup> Wollina,<sup>(3)</sup> Bhat,<sup>(4)</sup> Brooklyn et al,<sup>(5)</sup> and Chevrant-Breton et al.<sup>(16)</sup>

\* pyogenic arthritis, pyoderma gangrenosum and acne

the work-up of our patient. Skin biopsy specimens for appropriate fungal and mycobacterial stains and cultures can aid in the exclusion of these cutaneous infections which may mimic PG. Meliodosis is endemic in Southeast Asia and may present with necrotic skin ulcers. Culture in Ashdown's medium may show *Burkholderia pseudomallei* in these instances. In sexually-active patients with high-risk behaviour, sexually transmitted infections like chancroid, lymphogranuloma venereum, chancre and granuloma inguinale need to be considered in patients with genital ulcers. Stains and microscopy did not reveal any organism in our patient.

PG is associated with inflammatory bowel disease (IBD), arthritis (commonly, seropositive rheumatoid arthritis), monoclonal gammopathies and myoproliferative disorders.<sup>(4,5)</sup> Less common associations reported are with hidradenitis suppurativa, sarcoidosis, Takayasu's arteritis and HIV (Table I). In HIV-associated PG, the commonest site affected is the perineum.<sup>(4)</sup> 30% of PG cases are associated with IBD,<sup>(5)</sup> but only 1%–2% of IBD have PG as its extraintestinal manifestation.<sup>(5,9)</sup> Treating the underlying associated disease can result in healing of the PG, but it may have a completely independent course to the IBD, necessitating specific therapy. Our patient did not have active bowel disease at the time of presentation.

Treatment is via immunosuppression.<sup>(1,4,5)</sup> No single specific treatment exists. The vegetative variant

of PG and early superficial lesions may respond to local therapy.<sup>(2)</sup> Some forms of local therapies reported include highly-potent intralesional steroids, topical tacrolimus, topical 5-aminosalicylic acid, benzoyl peroxide, topical sodium cromoglycate, intralesional cyclosporine and topical nitrogen mustard.<sup>(4,5)</sup> Systemic therapy may be employed in patients who fail local therapy, or in widespread and rapidly progressive cases, and in cases where no underlying disease is detected or where treatment of the underlying disease did not result in remission.<sup>(2-4)</sup> The best documented treatments are with corticosteroids or cyclosporine,<sup>(3)</sup> and they should be considered as the first-line therapy.<sup>(2)</sup> Corticosteroids at a high-dose of 1–2 mg/kg/day is effective, and pulsed intravenous methylprednisolone at 1 g/day for 3–5 days induces rapid response (Grade B evidence).<sup>(2-5)</sup> Alternative immunosuppressive agents may be introduced as steroid sparing agents or when the PG is refractory to corticosteroids. Cyclosporine is the most widely-used alternative. Doses at 2–5 mg/kg/day have been used with efficacy in PG.<sup>(3,5)</sup> It induces early response but has no impact on recurrence.<sup>(3)</sup> There are case reports of other immunosuppressants used in PG, and they include azathioprine, sulfa drugs, mycophenolate mofetil, thalidomide, clofazimine, colchicines, cyclophosphamide and chlorambucil.<sup>(2-4)</sup>

Specific treatments of PG in Crohn's disease stem from a few case series using sulfasalazine, 5-

aminosalicylic acid, corticosteroids, azathioprine or 6-mercaptopurine, methotrexate, infliximab, adalimumab, etanercept and cyclosporine or tacrolimus.<sup>(10)</sup> However, most of the data came from extrapolating from patients who did not have Crohn's disease. When the underlying disease is ulcerative colitis or Crohn's disease, azathioprine and sulfasalazine are good options.<sup>(3)</sup> Others have used intravenous cyclosporine in steroid refractory PG in IBD.<sup>(11)</sup> In a case series, six out of 11 patients had Crohn's disease, and the remaining five who had ulcerative colitis, were treated with intravenous cyclosporine. They had bowel activity ranging from moderate to mild to inactive. All patients had healed within a mean period of 1.4 months, and bowel activity went into remission. They were discharged on oral cyclosporine and maintained on azathioprine. Resolution of penile PG has been reported with therapeutic colectomy in ulcerative colitis.<sup>(7)</sup>

Currently, the role of infliximab, a tumour necrosis factor-alpha inhibitor, has been increasing. Its use has been applied to refractory PG associated with concomitant Crohn's disease as a first-line therapy (Grade B evidence).<sup>(2,12)</sup> Case reports have shown successful treatment of both Crohn's disease and PG after failed treatment with intravenous methylprednisolone, and high-dose of oral prednisolone, azathioprine, cyclosporine or sulfasalazine.<sup>(1,9,13,14)</sup> Ferkolj et al reported good response with infliximab 5 mg/kg at zero, two and six weeks in a patient with active Crohn's disease and refractory PG. Both bowel activity and PG went into remission, and the patient was maintained on an eight-weekly infliximab infusion and azathioprine.<sup>(1)</sup> Infliximab was given solely for refractory PG in a patient with inactive Crohn's disease, and the patient was in remission one year after the infusion.<sup>(13)</sup> Tan et al reported two cases of fistulating Crohn's disease and refractory PG which responded well to infliximab. PG recurred but the patients responded again to the infliximab.<sup>(14)</sup> In a retrospective study of 13 patients, a full or partial response to infliximab was shown in refractory PG associated with IBD. Most patients required repeated infusions and some were maintained on infliximab.<sup>(13)</sup> Further studies are needed to determine the number of infliximab infusions needed for induction or maintenance. Long-term risks and benefits remain to be determined as well. A randomised, double-blind, multicentre trial showed that infliximab was superior to a placebo in the treatment of PG.<sup>(15)</sup> A subgroup analysis suggested that there was no difference in the response according to the coexistence of IBD, but cautioned its interpretation as the numbers were small.

In conclusion, no single specific treatment exists for PG associated with inflammatory bowel disease. There are many options of treatment for refractory PG, but it is difficult to conclude what the best steroid sparing agent is, due to the exiguity of data available. Our case also illustrates the rare presentation of scrotal PG. With the combination of such clinical features and histopathologic findings, the diagnosis of PG should be part of the differentials.

## REFERENCES

1. Ferkolj I, Hocevar A, Golouh R, Dolenc Voljc M. Infliximab for treatment of resistant pyoderma gangrenosum associated with Crohn's disease. *Acta Dermatovenerol Alp Panonica Adriat* 2006; 15:173-7.
2. Reichrath J, Bens G, Bonowitz A, Tilgen W. Treatment recommendations for pyoderma gangrenosum: an evidence-based review of the literature based on more than 350 patients. *J Am Acad Dermatol* 2005; 53:273-83.
3. Wollina U. Pyoderma gangrenosum--a review. *Orphanet J Rare Dis* 2007; 2:19.
4. Bhat RM. Management of pyoderma gangrenosum--an update. *Indian J Dermatol Venereol Leprol* 2004; 70:329-35.
5. Brooklyn T, Dunnill G, Probert C. Diagnosis and treatment of pyoderma gangrenosum. *BMJ* 2006; 333:181-4.
6. Caputo R, Marzano AV, Di Benedetto A, Ramoni S, Cambiaghi S. Juvenile gangrenous vasculitis of the scrotum: Is it a variant of pyoderma gangrenosum? *J Am Acad Dermatol* 2006; 55:S50-3.
7. Badgwell C, Rosen T. Penile pyoderma gangrenosum. *Dermatol Online J* 2006; 12:8.
8. McAleer MA, Powell FC, Devaney D, O'Donnell BF. Infantile pyoderma gangrenosum. *J Am Acad Dermatol* 2008; 58:S23-8.
9. López San Román A, Bermejo F, Aldanondo I, et al. Pyoderma gangrenosum associated with ulcerative colitis: response to infliximab. *Rev Esp Enferm Dig* 2004; 96:420-4.
10. Juillerat P, Mottet C, Pittet V, et al. Extraintestinal manifestations of Crohn's disease. *Digestion* 2007; 76:141-8.
11. Friedman S, Marion JF, Scherl E, Rubin PH, Present DH. Intravenous cyclosporine in refractory pyoderma gangrenosum complicating inflammatory bowel disease. *Inflamm Bowel Dis* 2001; 7:1-7.
12. Regueiro M, Valentine J, Plevy S, Fleisher MR, Lichtenstein GR. Infliximab for treatment of pyoderma gangrenosum associated with inflammatory bowel disease. *Am J Gastroenterol* 2003; 98:1821-6.
13. Kouklakis G, Moschos J, Leontiadis GI, et al. Infliximab for treatment of pyoderma gangrenosum associated with clinically inactive Crohn's disease. A case report. *Rom J Gastroenterol* 2005; 14:401-3.
14. Tan MH, Gordon M, Lebwohl O, George J, Lebwohl MG. Improvement of Pyoderma gangrenosum and psoriasis associated with Crohn disease with anti-tumor necrosis factor alpha monoclonal antibody. *Arch Dermatol* 2001; 137:930-3.
15. Brooklyn TN, Dunnill MG, Shetty A et al. Infliximab for the treatment of pyoderma gangrenosum: a randomised, double blind, placebo controlled trial. *Gut* 2006; 55:505-9.
16. Chevrant-Breton J, Logeais B, Pibouin M. [Pyoderma gangrenosum (phagedenic pyoderma)]. *Ann Dermatol Venereol* 1989; 116:577-89. French.