

CME Article

Fingertip injuries

Yeo C J, Sebastin S J, Chong A K S

ABSTRACT

Fingertip injuries are commonly seen by family and emergency physicians. Many of the cases are simple to treat and do not need specialised treatment by a hand surgeon. However, there are certain conditions where early intervention by a hand surgeon is warranted for better functional and aesthetic outcomes. Common injuries include mallet finger injury, crush injuries to the fingertip with resultant subungual haematoma, nail bed laceration, partial or complete amputation of the fingertips, pulp amputations and fractures of the distal phalanges.

Keywords: fingertip, injuries, fingertip injuries, fingertip amputation, nail bed injuries

Singapore Med J 2010;51(1):78-87

INTRODUCTION

A stable, mobile and sensate fingertip is important to the overall function of the hand. In addition, the face and hand are the most looked at parts of our body. When faced with a fingertip injury, clinicians will need to manage both functional and aesthetic considerations in their treatment plan.

A fingertip injury is any soft tissue, nail or bony injury distal to the insertions of the long flexor and extensor tendons of a finger or thumb.⁽¹⁾ Fingertip injuries are commonly seen by family and emergency physicians. Many of these cases are simple to treat and do not need specialised treatment by a hand surgeon. However, there are certain conditions where early intervention by a hand surgeon is warranted for better functional and aesthetic outcomes.

Common injuries include crush injuries to the fingertip (with resultant subungual haematoma, nail bed laceration, partial or complete amputation of the fingertips, pulp amputations and fractures of the distal phalanges), mallet finger, flexor digitorum profundus (FDP) avulsion, and distal interphalangeal joint dislocations.

EPIDEMIOLOGY

Hand and finger injuries can be crippling and affect all ages, none more so than the working-class adults and children. In adults, injuries are commonly due to occupational activities. In this setting, lacerations are

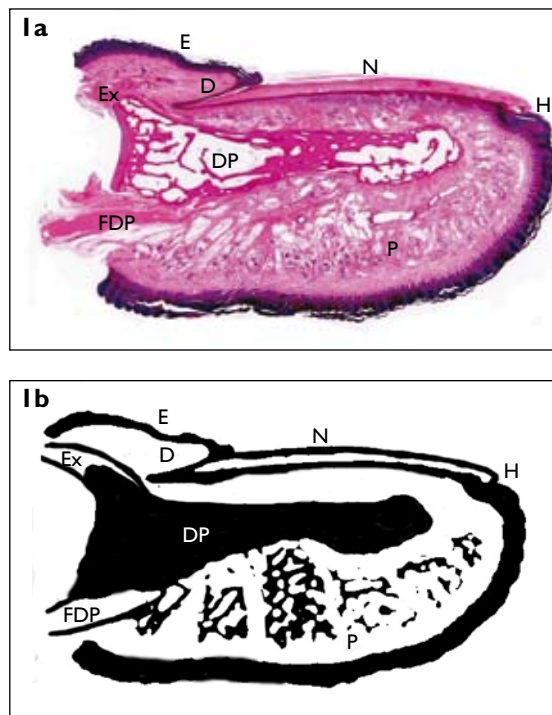


Fig. 1 Cross section of the fingertip. (a) Haematoxylin & eosin stain (Original magnification). (b) Cartoonised.

E: eponychium; D: dorsal nail fold; H: hyponychium; N: nail with underlying nail complex; P: pulp; Ex: extensor tendon; FDP: flexor digitorum profundus; DP: distal phalanx

the major type of injury, followed by crush and avulsion injuries. Most injuries tend to be singular and of minor severity, and can be treated as an outpatient. However, powered machines and non-powered hand tools are more likely to result in multiple types of injuries.⁽²⁾ The National Institute for Occupational Safety and Health in the United States conducted a survey across multiple emergency departments in 1982, and estimated occupational finger injuries to account for 25.7% of its workload. 1.6% had amputations of one or more fingers.⁽³⁾

With regard to children, the Royal Hospital for Sick Children's (Glasgow) Accident and Emergency Department sees fingertip injuries which account for 1.8% of its workload. Injuries in children limit their daily activities like eating, playing and schoolwork. Parents worry about immediate problems as well as long-term functional and aesthetic outcomes/disabilities. In isolated finger injuries,⁽⁴⁾ the incidence is highest in younger children and boys. Most injuries arise at home and are due to "jamming/crushing", usually by doors, either by their parents or siblings.⁽⁵⁾

Department
of Hand and
Reconstructive
Microsurgery,
National University
Hospital,
5 Lower Kent Ridge
Road,
Singapore 119074

Yeo CJ, MBChB,
MMed, MRCS
Registrar

Sebastin SJ, MBBS,
MCh
Associate Consultant

Chong AKS, MBBS,
MRCSE, FAMS
Consultant

Correspondence to:
Dr Alphonsus Chong
Tel: (65) 6772 5549
Fax: (65) 6773 2558
Email: alfchong@
gmail.com

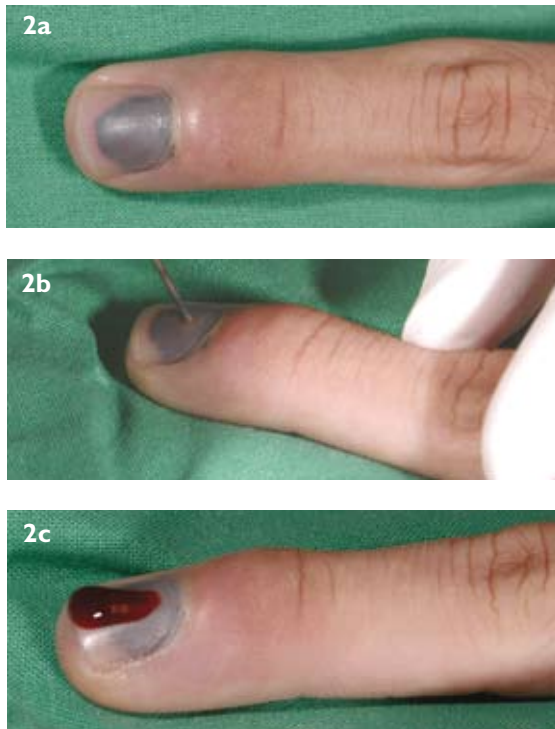


Fig. 2 Subungual haematoma and treatment photographs show (a) subungual haematoma affecting 80% of the nail, associated with pain, (b) trephination with a red hot needle after a digital block was given and (c) release of haematoma and relief of pressure.

In this article, we review important aspects of fingertip injuries relevant to the nonspecialist, including the clinical anatomy and common injuries, and focusing on assessment and treatment.

FINGERTIP ANATOMY

Understanding the fingertip anatomy provides the basis for optimum care of these specialised structures after injury. The nail is the most prominent feature of the finger. It fulfils both an aesthetic and functional role, allowing increased sensory perception in the pad of the finger, and the accurate picking up of objects. The parts include the eponychium, paronychium, hyponychium, lunula, nail matrix and dorsal nail fold (Fig. 1). The eponychium is the soft tissue on the dorsal surface superior of the nail, extending from the dorsal finger skin. The paronychium are the folds on each lateral aspect of the nail that curve into the fingertip. The hyponychium is a plug of keratinous material situated beneath the distal edge of the nail (i.e. where the nail bed meets the skin). The nail fold consists of the dorsal and ventral floors. The dorsal nail fold is responsible for the shine of the nail. The nail bed consists of the sterile and germinal matrix. The germinal matrix is responsible for 90% of the nail growth, and the sterile matrix is where the nail adheres to the nail bed. The white arc on the nail is called the lunula, and it demarcates the sterile from the germinal matrix underneath. The nail itself

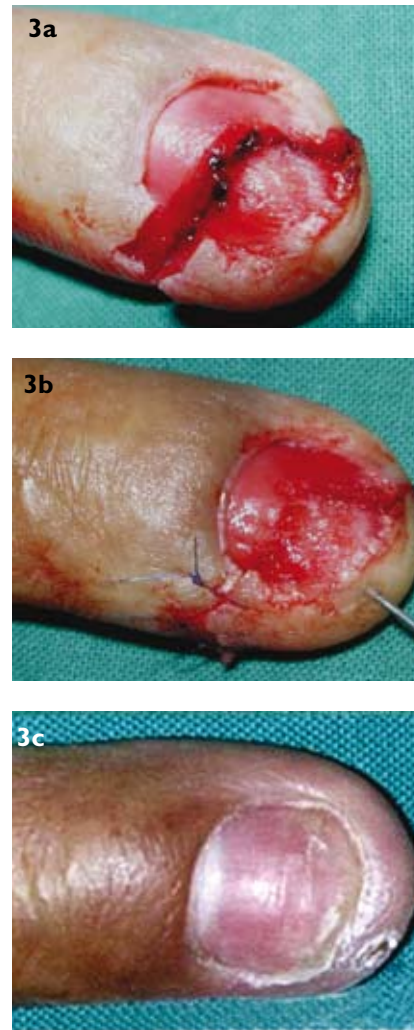


Fig. 3 Simple nail bed laceration. Photographs show (a) a crush injury to the fingertip, (b) the wound washed out and the sterile matrix of the nail bed repaired with fine sutures, and (c) the results three months later.

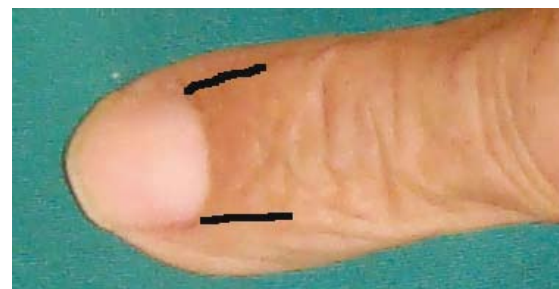

Fig. 4 Solid black lines indicate where back cuts are made for exposure of the germinal matrix.

is composed of onchyn, which is a keratinous material that is produced by the death of the germinal cells as they are pressed upwards.

The pulp consists of multiple fibrous trabeculations arising from the periosteum to the epidermis that divides the pulp into a latticework of separate septal compartments containing fat. The core of the fingertip contains the distal




Fig. 5 Allen's classification.⁽¹¹⁾

phalangeal bone. It is of close proximity to the nail bed. The extensor tendon attaches onto the base of the distal phalanx, and lies about 2 mm from the proximal end of the germinal matrix. The flexor digitorum profundus tendon attaches on the volar aspect of the distal phalanx (Fig. 1).

Each of the two digital nerves splits just proximal to the base of the nail fold, giving one branch into the pulp and another to the nail bed. There are multiple variations to the nerve supply at the fingertip.⁽⁶⁾ In the fingertip are unique structures called glomus bodies. They are intertwined balls of fine nerves and vessels that regulate blood flow to the fingertip. Each digital artery dives into the pulp at the level of the distal phalanx, and gives off a branch parallel to the paronychium. This then becomes multiple small, fine branches going into the nail bed as the vessel traverses distally.⁽⁷⁾ The small veins of the fingertip do not follow the artery as vena concomitants but progress proximally in a random fashion.⁽⁸⁾

COMMON INJURIES

Nail & nail bed injuries

These injuries include simple lacerations, complex stellate lacerations, avulsion injuries, amputations or associated paronychia injuries. Subungual haematomas are usually the result of a crushing injury. A plain radiograph of the affected finger should be taken to rule out an associated fracture. Painless subungual haematomas can be treated conservatively if the nail plate is still adherent to the bed and not displaced out of the nail folds. This is regardless of the size of the haematoma.⁽⁹⁾ For cases of subungual haematomas with an underlying fracture, the nail should be avulsed and the nail bed debrided and repaired.⁽¹⁰⁾ Depending on the configuration of the underlying fracture, the fracture might need to be reduced and fixed.

Subungual haematomas with no underlying fractures can generally be left alone, unless it causes pain for the patient. Trephination of the nail can be carried out

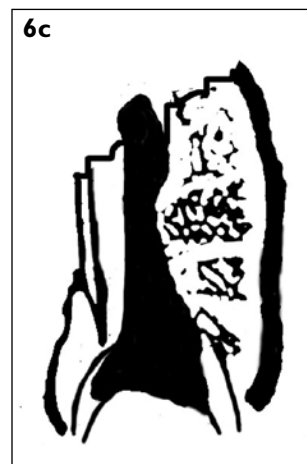

Fig. 6 Additional useful information for the hand surgeon regarding fingertip amputations. (a) Volar unfavourable. (b) Volar neutral. (c) Volar favourable.

as an outpatient procedure to relieve the pain, usually instantaneously. A digital block is performed, followed by trephination using a heated (red hot) paperclip (Fig. 2).

Simple lacerations through the sterile matrix can be sutured in the outpatient setting with 6/0 absorbable sutures. (Fig. 3) Nonabsorbable sutures are avoided. Digital tourniquets applied after the digital block is given will help ease the repair by creating a bloodless field.

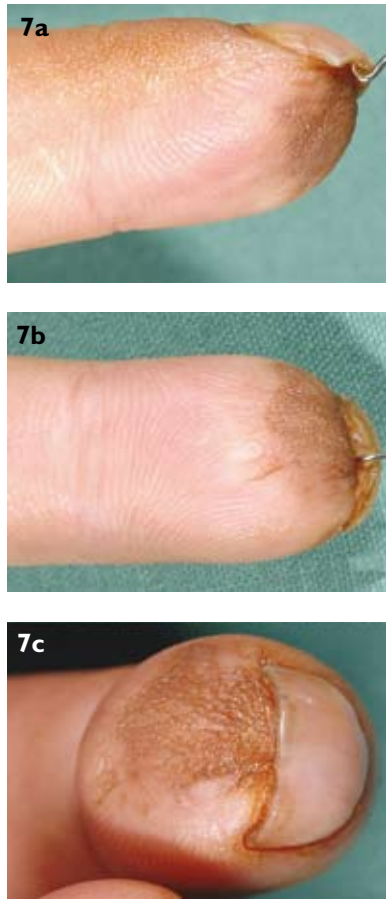


Fig. 7 Results of skin grafting for a small pulp defect. Return of sensation is variable, and there is usually some contractures of the defect site, which can lead to beaking of the nail.

Lacerations through the nail fold, germinal matrix or dorsal roof should also be repaired accurately. Back cuts (Fig. 4) at the two corners of the proximal nail fold can allow one to visualise the germinal matrix and dorsal roof for this purpose. Nail plates removed are usually sutured back to act as a splint, keeping the dorsal roof and germinal matrix from being adherent to each other. Artificial nails, or the silver foil from the suture package cut into shape are used as splints when the patient's own nail is missing, too damaged or too dirty to be utilised. The splints are to prevent the dorsal roof from adhering to the nail bed before the new nail grows. A nonadherent dressing is used to protect the repair. The risk of permanent nail deformity is higher if the germinal matrix is involved in the injury.

In cases with partial or complete nail bed loss, reconstruction of the nail and nail bed might be required. Children with nail bed injuries should be referred as they usually require general anaesthesia for any repair or debridement to be carried out, because they are unable to cooperate with treatment under local anaesthesia.

Fingertip & pulp amputations

Allen's classification is commonly used to describe the

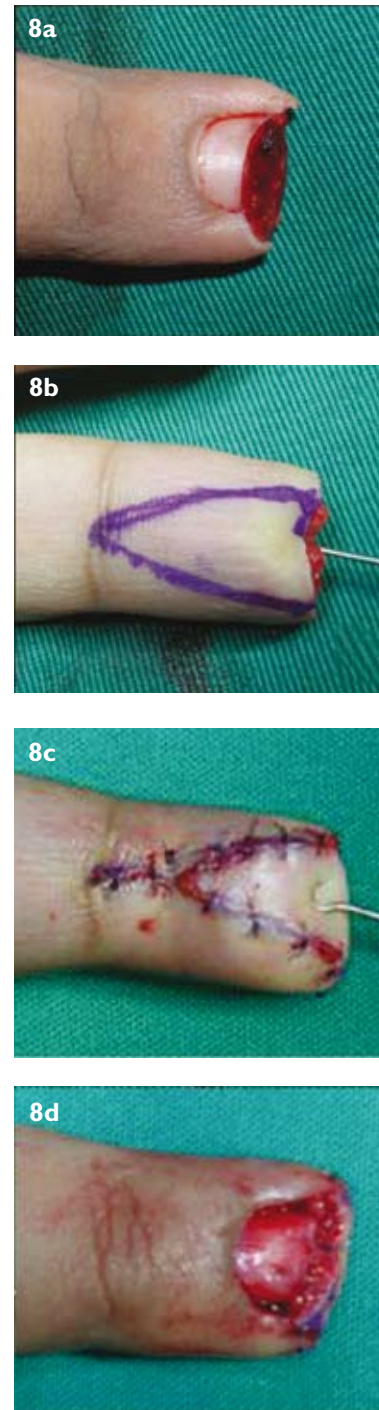


Fig. 8 Photographs show (a) a VY advancement flap for Allen II volar neutral fingertip amputation and (b) the design of the VY advancement flap. (c, d) Postoperation photographs.

level of amputation⁽¹¹⁾ (Fig 5) for fingertip amputations. Type 1 injuries are those involving the pulp only. Type 2 injuries consist of injury to the pulp and nail bed. Type 3 injuries include distal phalangeal fracture with associated pulp and nail loss. Type 4 injuries involve the lunula, distal phalanx, pulp and nail loss. Additional information that is useful to the hand surgeon when receiving a referral is whether the amputation is volar neutral, volar favourable or volar unfavourable (Fig. 6).

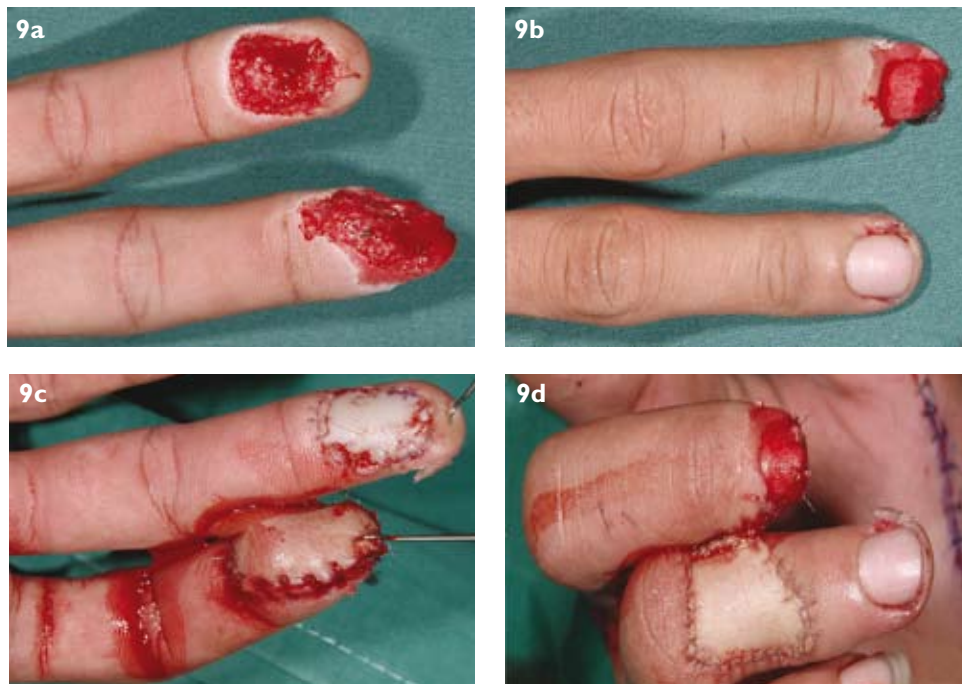


Fig. 9 Cross finger flap. (a, b) The patient presented with a middle finger tip amputation and ring finger pulp shaving injury. (c, d) A full thickness skin graft was used for the ring finger pulp defect, while a cross finger flap was used for the middle finger tip amputation.

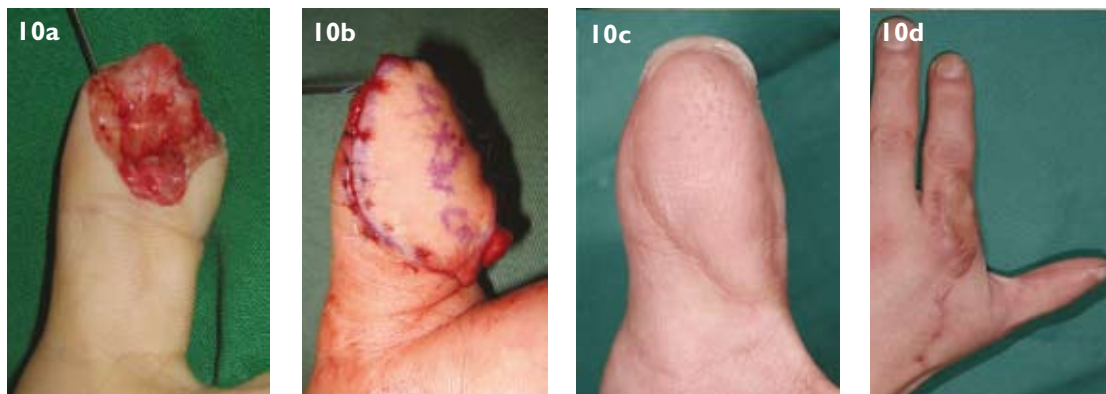


Fig. 10 Foucher flap for thumb pulp reconstruction. (a) The patient presented with a left thumb volar unfavourable tip amputation. (b) A foucher flap was used to cover the defect. (c) The appearance of the flap six months postoperation. (d) The appearance of the donor site six months postoperation.

Diagnosis is usually straightforward, based on the clinical history and examination, as well as the plain radiographs of the affected digit. Treatment options targeted toward the exact kind of defect or pathology the patient presents with include secondary intention healing, skin grafting (Fig. 7), flaps (VY advancement [Fig. 8], cross finger flap [Fig. 9], neurovascular island flap, reverse vascular island flap, foucher flap [Fig. 10], toe pulp transfer), terminalisation or revision amputation (Fig. 11), and distal replantation (Fig. 12).

Secondary intention healing is ideal for superficial clean wounds that are smaller than 1cm² in adults, with no exposed bone.⁽¹²⁾ Recovery usually takes up to six weeks, with regular wound dressings at the clinics. Skin grafting

is considered when the defect is larger but with no exposed bone, or if the patient does not wish to go through the long healing process of allowing healing by secondary intention. However, skin grafting will leave a wound from the donor site. Long-term results from secondary healing and skin grafting are generally good. Complications can include beaking of the nail (Fig. 7), the loss of pulp contour and hypo- or hyperaesthesia.

With finger tip injuries where the bone is exposed or there is a sizeable amount of tissue loss, a local or free flap is required to cover the defect. The site the flap is taken from depends on the size and site of the defect, the experience of the surgeon, and to a certain extent, the patient's choice. The flap can range from a simple VY advancement flap to

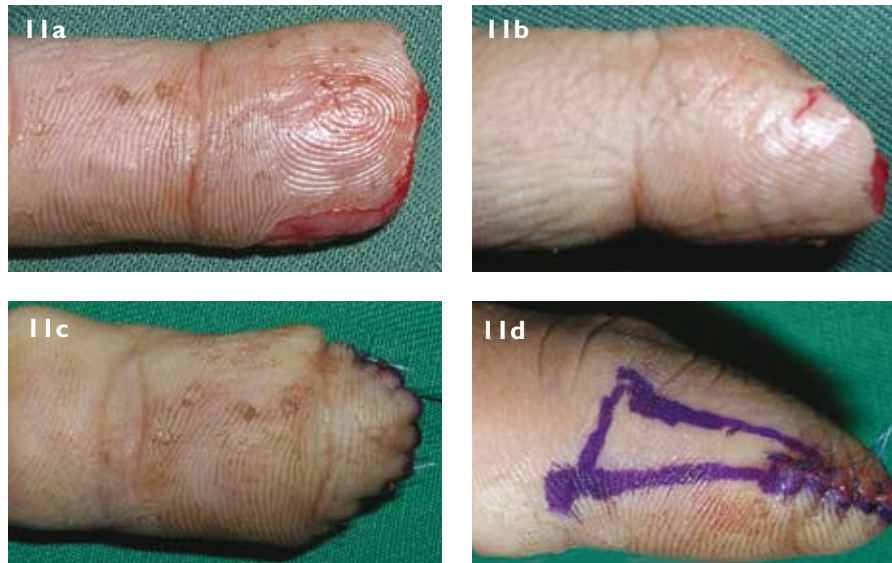


Fig. 11 Terminalisation or revision amputation. (a, b) Fingertip amputation. (c, d) The patient chose to have a revision amputation as this allowed quicker healing and a shorter time off work.

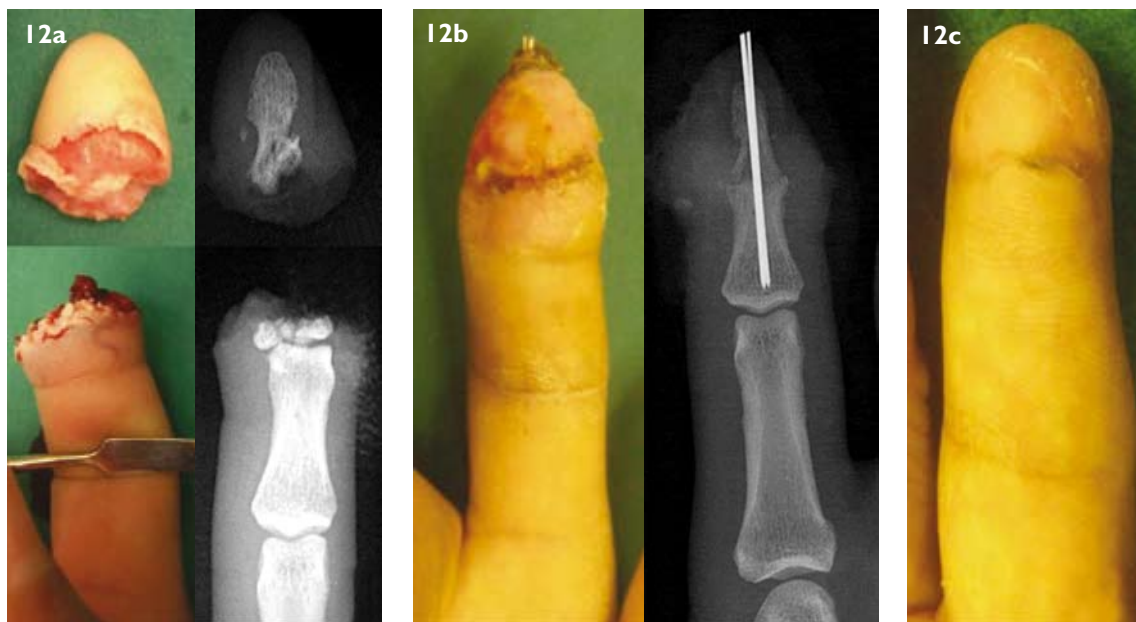


Fig. 12 Distal replantation. Photographs and accompanying radiograph images show (a) a complete amputation through the distal phalanx and (b) the replanted finger one month postoperation, where the distal interphalangeal joint is fused. (c) The final results six months postoperation.

a free toe pulp transfer for thumb pulp defects.

In children, surgical treatment is more conservative in nature, with the aim of preservation of the digit length. Children below the age of five do well with “cap-plasty”, where the amputated tip is sutured back primarily as a composite graft (Fig. 13) after a thorough debridement with minimal defatting.

Distal replantation is defined as the replantation of the fingertip at the level of or distal to the distal interphalangeal joint (DIPJ).⁽¹³⁾ Replantation is attempted when the amputate is present with the normal architecture.

This allows the preservation of finger length and the irreplaceable nail bed. The functional and cosmetic outcomes are usually good, even if the DIPJ is fused for the replant (Fig. 13).⁽¹⁴⁾ Replantations should be attempted in children as they have better cosmetic and functional outcomes compared to adults, although it is technically more challenging to the surgeon due to the smaller vessels. Common complaints from patients following a fingertip amputation include cosmesis, stiffness, cold intolerance, and hyper- or hyposensitivity to the affected digit. This can be regardless of the type of treatment administered.

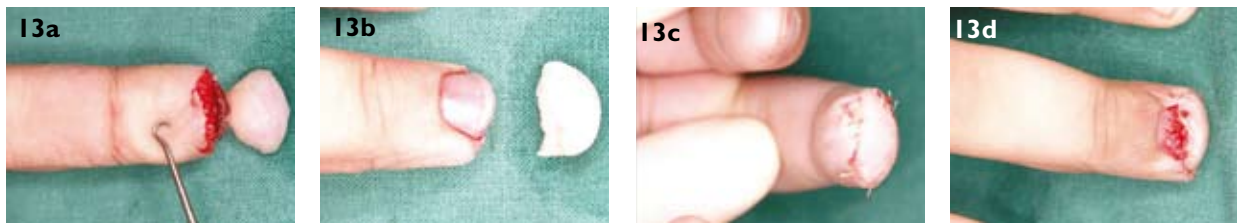


Fig. 13 Composite grafting works well for children under five years of age with finger tip amputation. (a, b) A child with fingertip amputation and salvaged amputate. (c, d) The wounds were cleaned thoroughly, and the amputate was sutured back as a composite graft.

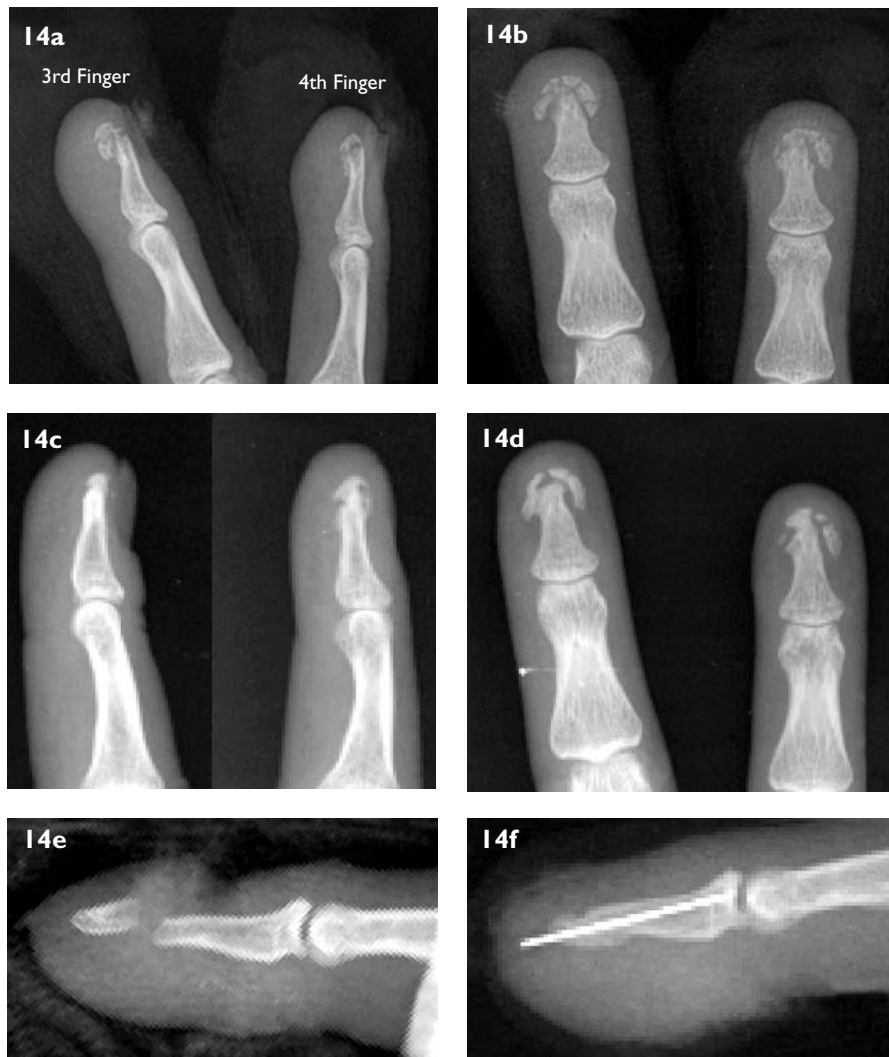

Fig. 14 Distal phalangeal fractures. Tuft fractures (a, b) do not require fixation and can lead to fibrous union (c, d) with no deficit. (e) Distal shaft fracture of the distal phalanx with (f) k-wire inserted for reduction. The wires are removed in the clinic after three to four weeks and patients are started on gentle mobilisation.

Distal phalangeal fractures

No fixation is usually required for tuft fractures (Fig. 14). Patients should be given analgesia and a protective splint for a few weeks until the pain resolves. They should also be counseled that pulp pain on pressure can persist for up to two to three months as the bone is healing. If there is an associated nail bed or pulp laceration, then meticulous toileting of the wound with repair of the lacerations should

be carried out. Open fractures with significant pulp or nail bed defects, unstable or significantly displaced fractures, and fractures in children should be referred to the hand surgeon for further management.

Mallet fingers

Mallet fingers are most commonly the result of a sudden flexion of an extended DIPJ along the long axis of the

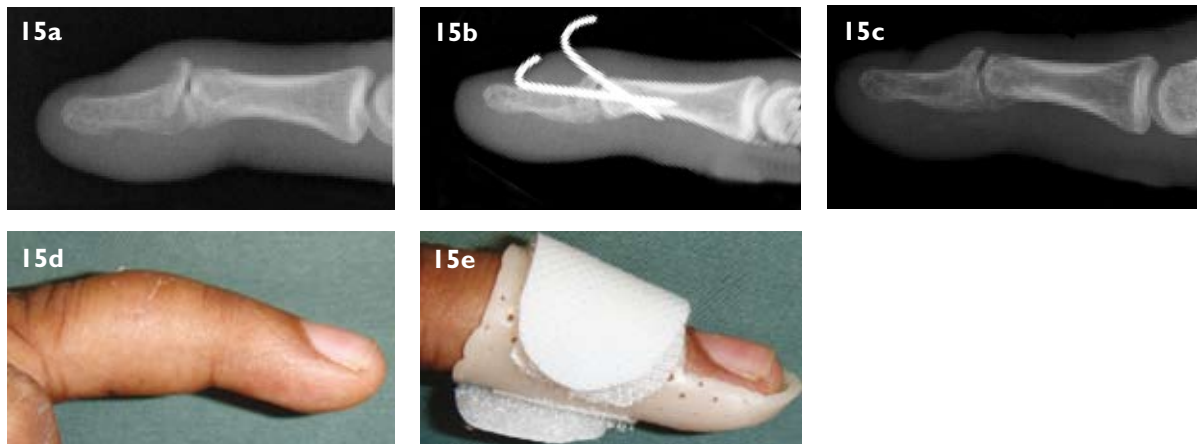


Fig. 15 Mallet finger injuries can involve a bony element, or be purely ligamentous. Radiograph images show (a) a bony mallet finger with displacement of the avulsed intra-articular fragment dorsally, (b) intra-focal k-wires used to reduce and maintain the bone and tendon and (c) the results six weeks postoperation. Patients will usually have a slight extension lag of about 10° and a residual stiffness of the distal interphalangeal joint. (d, e) Mallet fingers that do not require fixation are splinted for a total of six weeks in a mallet splint.

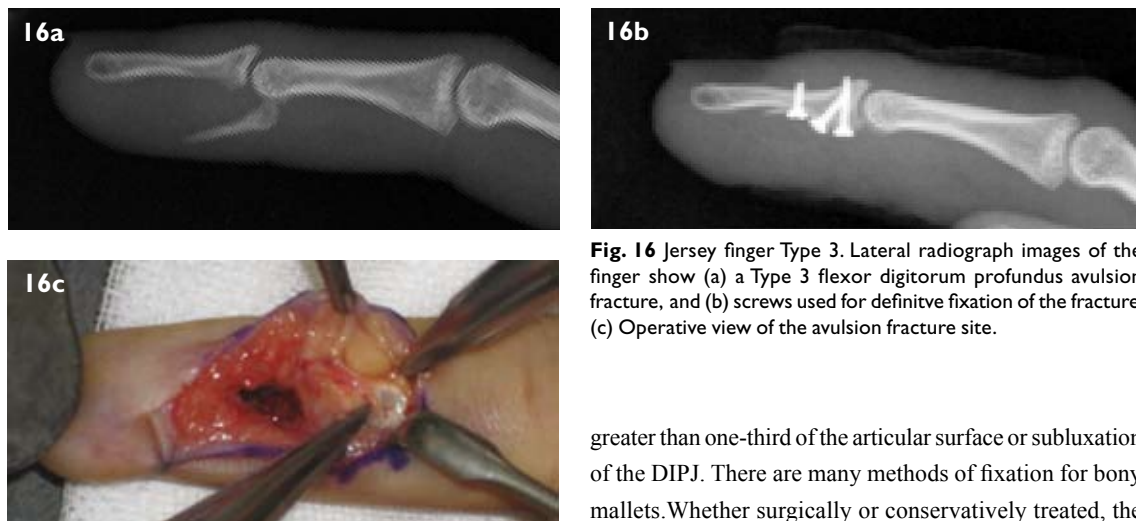


Fig. 16 Jersey finger Type 3. Lateral radiograph images of the finger show (a) a Type 3 flexor digitorum profundus avulsion fracture, and (b) screws used for definitive fixation of the fracture. (c) Operative view of the avulsion fracture site.

finger.⁽¹⁵⁾ This is the commonest closed tendon injury in the hand. The extensor tendon can be stretched, partially torn, ruptured or avulsed with a bony fragment from the base of the distal phalanx. The loss of active extension of the DIPJ is the hallmark sign of a mallet finger. The loss of passive extension with “swan-necking” due to proximal interphalangeal joint hyperextension suggests chronicity of the injury. The diagnosis is mainly a clinical one, with the aid of plain radiographs to rule out or confirm an associated fracture and subluxation of the joint.

Most mallet fingers can be treated effectively with continuous splinting of the DIPJ in extension for a total of six weeks before interval mobilisation, with a further two weeks of night splintage. A Cochrane review has shown that all available splints give similar end results.⁽¹⁶⁾ Surgery is indicated for patients who have failed conservative treatment, have open mallet injuries, are unable to work with the splint in position, and who have a fracture involving

greater than one-third of the articular surface or subluxation of the DIPJ. There are many methods of fixation for bony mallets. Whether surgically or conservatively treated, the patient will likely be left with a residual extension lag of 10° – 20° of the DIPJ⁽¹⁵⁾ (Fig. 15).

JERSEY FINGER (FLEXOR DIGITORUM PROFUNDUS AVULSION)

This injury is a result of forced extension with the DIPJ in active flexion. The ring finger accounts for up to 75% of jersey finger injuries.⁽¹⁷⁾ The end of the avulsed tendon retracts proximally along the finger or to the palm. Diagnosis is based on history, examination and plain radiographs.

The patient will be unable to actively flex the DIPJ after the injury. There will be a loss of the normal finger cascade at rest. Patients will sometimes feel a palpable lump over the proximal interphalangeal joint or in the palm. This is the retracted end of the flexor digitorum profundus tendon. The treatment of jersey fingers requires surgical intervention, which can include fracture fixation, primary tendon repair for early cases and tendon transfers for late diagnosis. The prognosis of jersey finger injuries

usually worsens with delay of treatment. The functional outcome of the affected finger is also usually worse with a more proximal retraction of the flexor digitorum profundus tendon.

CONCLUSION

Fingertip injuries should not be taken lightly as they can result in significant morbidity if poorly treated. Functional as well as aesthetic considerations have to be taken into account when treating fingertip injuries. Most fingertip injuries can be treated by the family or emergency physician, but there are some conditions that require referral to hand surgeons for optimal management.

ACKNOWLEDGEMENTS

We would like to thank Dr Peng Yeong Pin, Senior Consultant, and Dr Mark E Puhaindran, Consultant, from the Department of Hand and Reconstructive Microsurgery, National University Hospital, Singapore, for the use of the materials and photographs.

REFERENCES

1. Murai M, Lau HK, Pereira BP, Pho RW. A cadaver study on volume and surface area of the fingertip. *J Hand Surg* 1997; 22:935-41.
2. Sorock GS, Lombardi DA, Hauser RB, et al. Acute traumatic occupational hand injuries: type, location, and severity. *J Occup Environ Med* 2002; 44:345-51.
3. Coleman PJ, Sanderson LM. Surveillance of occupational injuries treated in hospital emergency rooms – United States, 1982. *Morb Mortal Wkly Rep Surveill Summ* 1983; 32:31SS-37SS
4. Doraiswamy NV, Baig H. Isolated finger injuries in children – incidence and aetiology. *Injury* 2000; 31:571-3.
5. Doraiswamy NV. Childhood finger injuries and safeguards. *Inj Prev* 1999; 5:298-300.
6. Zenn MR, Hoffman L, Latrenta G, Hotchkiss R. Variations in digital nerve anatomy. *J Hand Surg* 1992; 17:1033-6.
7. Strauch B, de Moura W. Arterial system of the fingers. *J Hand Surg Am* 1990; 15:148-54.
8. Lucas GL. The pattern of venous drainage of the digits. *J Hand Surg Am* 1984; 9:448-50.
9. Roser SE, Gellman H. Comparison of nail bed repair versus nail trephination for subungual hematomas in children. *J Hand Surg Am* 1999; 24:1166-70.
10. Simon RR, Wolgin M. Subungual hematoma: association with occult laceration requiring repair. *Am J Emerg Med* 1987; 5:302-4.
11. Allen MJ. Conservative management of finger tip injuries in adults. *Hand* 1980; 12:257-65.
12. Mennen U, Wiese A. Fingertip injuries management with semi-occlusive dressing. *J Hand Surg Br* 1993; 18:416-22.
13. Tamai S. Twenty years' experience of limb replantation – review of 293 upper extremity replants. *J Hand Surg Am* 1982; 7:549-56.
14. Lim BH, Tan BK, Peng YP. Digital replantations including fingertip and ring avulsion. *Hand Clin* 2001; 17:419-31, viii-ix.
15. Jablecki J, Syrko M. Zone 1 extensor tendon lesions: current treatment methods and a review of literature. *Orthop Traumatol Rehabil* 2007; 9:52-62.
16. Handoll HH, Vaghela MV. Interventions for treating mallet finger injuries. *Cochrane Database Syst Rev* 2004; CD004574.
17. Hankin FM, Peel SM. Sport-related fractures and dislocations in the hand. *Hand Clin* 1990; 6:429-53.

SINGAPORE MEDICAL COUNCIL CATEGORY 3B CME PROGRAMME
Multiple Choice Questions (Code SMJ 201001B)

- | | True | False |
|--|--------------------------|--------------------------|
| Question 1. For subungual haematoma: | | |
| (a) Painless haematoma can be treated conservatively only if it is < 50% of the nail bed. | <input type="checkbox"/> | <input type="checkbox"/> |
| (b) Trephination can be done to alleviate the pain and pressure. | <input type="checkbox"/> | <input type="checkbox"/> |
| (c) Nail avulsion with nail bed debridement and repair is done when there is an underlying fracture. | <input type="checkbox"/> | <input type="checkbox"/> |
| (d) An radiograph should be taken. | <input type="checkbox"/> | <input type="checkbox"/> |
| Question 2. For nail bed lacerations: | | |
| (a) Repairs should be done with absorbable sutures. | <input type="checkbox"/> | <input type="checkbox"/> |
| (b) Repair of the germinal matrix gives predictable results. | <input type="checkbox"/> | <input type="checkbox"/> |
| (c) Patient's own nail should be utilised as a splint postrepair. | <input type="checkbox"/> | <input type="checkbox"/> |
| (d) Children might need general anaesthesia for simple nail bed repairs. | <input type="checkbox"/> | <input type="checkbox"/> |
| Question 3. For fingertip and pulp amputations: | | |
| (a) Allen's classification is the only classification for fingertip amputations. | <input type="checkbox"/> | <input type="checkbox"/> |
| (b) Secondary healing is ideal for wounds < 1 cm ² , with or without exposed bone. | <input type="checkbox"/> | <input type="checkbox"/> |
| (c) Children below five years of age do better with composite grafts. | <input type="checkbox"/> | <input type="checkbox"/> |
| (d) Single digit distal replants are contraindicated. | <input type="checkbox"/> | <input type="checkbox"/> |
| Question 4. For distal phalangeal fractures: | | |
| (a) Tuft fractures are usually treated conservatively. | <input type="checkbox"/> | <input type="checkbox"/> |
| (b) Displaced shaft and base fractures require operative fixation. | <input type="checkbox"/> | <input type="checkbox"/> |
| (c) Tuft fractures with associated nail bed injuries should be treated like open fractures. | <input type="checkbox"/> | <input type="checkbox"/> |
| (d) Pulp pain from conservative treatment of tuft fractures can last up to three months. | <input type="checkbox"/> | <input type="checkbox"/> |
| Question 5. For mallet finger injuries: | | |
| (a) This is the most common closed tendon injury. | <input type="checkbox"/> | <input type="checkbox"/> |
| (b) Hallmark sign is the loss of active flexion of the distal interphalangeal joint. | <input type="checkbox"/> | <input type="checkbox"/> |
| (c) Chronic mallet injury is associated with a swan neck deformity. | <input type="checkbox"/> | <input type="checkbox"/> |
| (d) There is no place for surgical fixation for mallet fingers. | <input type="checkbox"/> | <input type="checkbox"/> |

Doctor's particulars:

Name in full: _____

MCR number: _____ Specialty: _____

Email address: _____

SUBMISSION INSTRUCTIONS:(1) Log on at the SMJ website: <http://www.sma.org.sg/cme/smj> and select the appropriate set of questions. (2) Select your answers and provide your name, email address and MCR number. Click on "Submit answers" to submit.**RESULTS:**(1) Answers will be published in the SMJ March 2010 issue. (2) The MCR numbers of successful candidates will be posted online at www.sma.org.sg/cme/smj by 7 April 2010. (3) All online submissions will receive an automatic email acknowledgment. (4) Passing mark is 60%. No mark will be deducted for incorrect answers. (5) The SMJ editorial office will submit the list of successful candidates to the Singapore Medical Council.**Deadline for submission: (January 2010 SMJ 3B CME programme): 12 noon, 31 March 2010.**