

# Hepatoprotective effect of three herbal extracts on aflatoxin B1-intoxicated rat liver

Shyamal S, Latha P G, Suja S R, Shine V J, Anuja G I, Sini S, Pradeep S, Shikha P, Rajasekharan S

## ABSTRACT

**Introduction:** Roots of *Ixora coccinea* (Rubiaceae), and *Rhinacanthus nasuta* (Acanthaceae) and whole plants of *Spilanthes ciliata* (Asteraceae) are extensively used by tribal communities in South India to treat liver diseases. However, the veracity of these tribal claims has not been investigated scientifically using the liver toxin, aflatoxin. This study reports on the protective effects of these three herbal ethanolic extracts on the aflatoxin B1 (AFB1)-intoxicated livers of albino male Wistar rats.

**Methods:** Biochemical parameters, including serum hepatic enzymes (glutamate oxaloacetate transaminase, glutamate pyruvate transaminase and alkaline phosphatase), were studied. Hepatic tissues were processed for assay of reduced glutathione (GSH) and histological alterations.

**Results:** Pre-treatment of the rats with oral administration of the plant ethanolic extracts, *Ixora coccinea* (IC), *Rhinacanthus nasuta* (RN), *Spilanthes ciliata* (SC), prior to AFB1 was found to provide significant protection against toxin-induced liver damage, determined 72 hours after the AFB1 challenge (1.5 mg/kg, intraperitoneally) as evidenced by a significant lowering of the activity of the serum enzymes and enhanced hepatic reduced GSH status. Pathological examination of the liver tissues supported the biochemical findings. The three plant extracts, IC, RN and SC, showed significant antilipid peroxidant effects *in vitro*.

**Conclusion:** It was concluded that the hepatoprotective effects of the three plant extracts observed in this study might result from their potent antioxidative properties.

**Keywords:** aflatoxin-induced liver damage,

hepatoprotective, *Ixora coccinea*, *Rhinacanthus nasuta*, *Spilanthes ciliata*

Singapore Med J 2010;51(4):326-331

## INTRODUCTION

The liver is the first organ to encounter ingested nutrients, drugs and environmental toxicants that enter the hepatic portal vein from the digestive system, and liver function can be detrimentally altered by injury resulting from acute or chronic exposure to toxicants.

Aflatoxin B1 (AFB1) is a hepatotoxic and hepatocarcinogenic compound produced by the fungus, *Aspergillus (A.) flavus*. A variety of human foods, such as cereals, millets and oil seeds, are susceptible to infection by *A. flavus*, which produces aflatoxins during its growth, harvest, transport and storage. AFB1 is also biotransformed by P<sub>450</sub> enzymes to yield an electrophilic epoxide, which attacks the DNA to initiate hepatotoxicity and genotoxicity via oxidative damage.<sup>(1-4)</sup> While searching for hepatoprotective agents in natural products, highly encouraging results were obtained at our laboratory with *Ixora (I.) coccinea* Linn. (Rubiaceae) (IC), *Rhinacanthus (R.) nasuta* Linn. (Kurz.) (Acanthaceae) (RN) and *Spilanthes (S.) ciliata* H.B.K. (Asteraceae) (SC).<sup>(5-8)</sup> These three plants are extensively used in traditional medicines of Kerala to treat liver ailments. We report the protective effect of the ethanolic extracts of these three plants against AFB1-induced hepatotoxicity in Wistar rats.

## METHODS

For preparation of plant extracts, whole plants of *S. ciliata* and roots of *I. coccinea* were collected from the Herbal Garden of the Institute, while *R. nasuta* roots were collected from Kudappanakunnu in the Thiruvananthapuram district of Kerala, India. They were authenticated by Dr Mathew Dan, the plant taxonomist at the Institute, and voucher specimens of all three plants were deposited at the Institute's herbarium. The officinal parts of the three plants were thoroughly washed with tap water, shade-dried and powdered separately. Each

Ethnomedicine and Ethnopharmacology Division, Tropical Botanic Garden and Research Institute, Palode, Thiruvananthapuram 695 562, India

Shyamal S, MSc  
Senior Research Fellow

Latha PG, MSc, PhD  
Scientist

Suja SR, MSc, PhD  
Junior Scientific Assistant

Shine VJ, MSc  
Senior Research Fellow

Anuja GI, MSc  
Senior Research Fellow

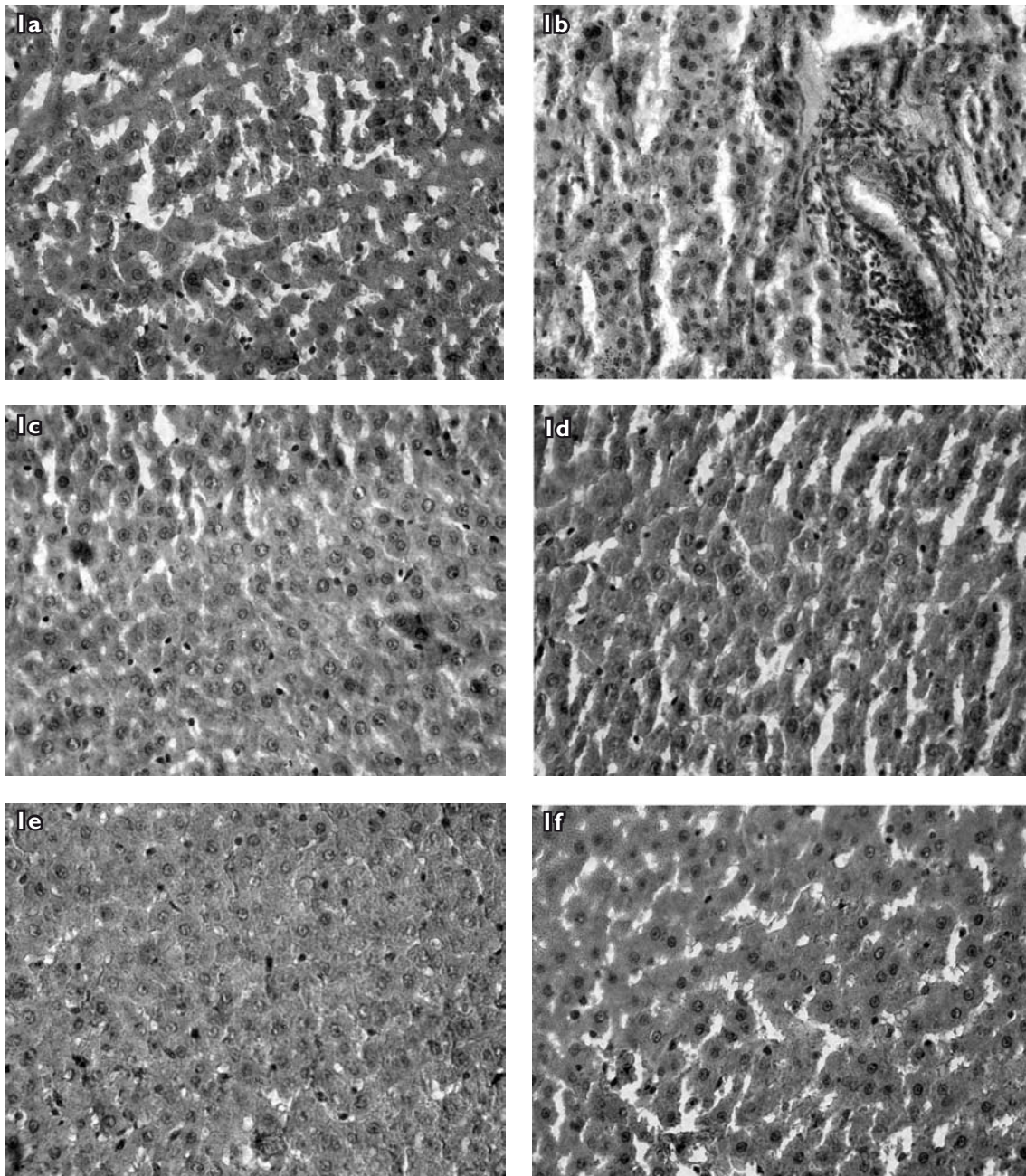
Sini S, MSc  
Senior Research Fellow

Pradeep S, MSc  
Junior Research Fellow

Shikha P, MSc  
Junior Research Fellow

Rajasekharan S, DAM,  
BAM  
Scientist

**Correspondence to:**  
Dr Latha  
Gopalakrishnan  
Tel: (91) 472 2869626  
Fax: (91) 472 2869646  
Email: lathagopala.krishnan@yahoo.com



**Fig.1** Histological evidence for the protective effect of IC/SC/RN ethanolic extracts on aflatoxin-induced hepatic damage in rats. (a) A section of liver of the normal control rat shows hepatic cells with well-defined nuclei and cytoplasm (Haematoxylin & eosin,  $\times 350$ ). (b) A section of aflatoxin-treated rat liver shows broad infiltration of lymphocytes and Kupffer cells, disturbed lobular architecture, fatty degenerative changes and focal necrosis (Haematoxylin & eosin,  $\times 350$ ). (c–e) Sections of IC (500 mg/kg) / SC (300 mg/kg) / RN (200 mg/kg) + aflatoxin-treated rat liver show marked improvement over the aflatoxin control group (Haematoxylin & eosin,  $\times 350$ ). (f) A section of silymarin + aflatoxin-treated rat liver shows marked protection of the hepatic cells (Haematoxylin & eosin,  $\times 350$ ).

type of powder (100 g) was then extracted separately using ethanol overnight with constant stirring. The extract was filtered and the filtrate was concentrated under reduced pressure to yield 8% (*S. ciliata*), 18% (*I. coccinea*) and 1% (*R. nasuta*) of the crude extracts, which were then referred to as SC, IC and RN, respectively. For administration, the plant extracts were suspended separately in 0.5% Tween-80 to the required concentrations.

Wistar albino male rats (200–250 g) and Swiss albino male mice (25–30 g), obtained from the Institute's animal house, were used for the present study. They were housed under standard conditions and fed commercial rat feed (Lipton India Ltd, Mumbai, India) and water *ad libitum*. All experiments involving the animals were conducted according to the National Institutes of Health guidelines, after obtaining approval from the Institute's Animal Ethics Committee.

**Table I. The effects of aflatoxin B1 (AFB1) and plant extracts on serum enzyme levels in rats (n = 3).**

Group	SGOT (IU/L)	SGPT (IU/L)	SAKP (IU/L)
Normal control	72.1 ± 2.76	26.3 ± 1.77	78.7 ± 5.02
AFB1 (1.5 mg/kg)	144.0 ± 3.86**	62.4 ± 7.28**	153.3 ± 8.61**
AFB1 (1.5 mg/kg) + IC (100 mg/kg)	102.4 ± 2.37	57.1 ± 3.14	93.2 ± 2.76
AFB1 (1.5 mg/kg) + IC (200 mg/kg)	78.8 ± 1.62*	30.1 ± 2.31*	60.3 ± 1.65*
AFB1 (1.5 mg/kg) + IC (300 mg/kg)	76.3 ± 1.71	32.3 ± 2.16	62.7 ± 1.65
AFB1 (1.5 mg/kg) + SC (100 mg/kg)	120.0 ± 1.81	56.3 ± 2.13	87.3 ± 4.31
AFB1 (1.5 mg/kg) + SC (200 mg/kg)	95.3 ± 1.61	40.3 ± 1.16	82.3 ± 2.11
AFB1 (1.5 mg/kg) + SC (300 mg/kg)	86.3 ± 1.78*	30.3 ± 1.72*	60.7 ± 3.75*
AFB1 (1.5 mg/kg) + RN (100 mg/kg)	100.3 ± 1.62	50.2 ± 2.15	90.3 ± 6.11
AFB1 (1.5 mg/kg) + RN (200 mg/kg)	76.3 ± 1.72*	32.3 ± 2.61*	56.3 ± 1.11*
AFB1 (1.5 mg/kg) + RN (300 mg/kg)	80.3 ± 2.81	40.3 ± 1.31	62.3 ± 2.75
AFB1 (1.5 mg/kg) + Silymarin (100 mg/kg)	70.1 ± 2.71*	28.3 ± 4.05*	80.1 ± 2.16*

Values are expressed as mean ± SD. \*  $p \leq 0.01$  when compared to the AFB1 control group. \*\*  $p \leq 0.001$  when compared to the normal control group, using Student's *t*-test.

IC: *Ixora coccinea*; SC: *Spilanthes ciliata*; RN: *Rhinacanthus nasuta*; SGOT: glutamate oxaloacetate transaminase; SGPT: glutamate pyruvate transaminase; SAKP: alkaline phosphatase

The procedure for AFB1-induced hepatotoxicity adopted by Dalvi et al<sup>(9)</sup> was followed. Briefly, the animals were divided into 12 groups of three each. Group 1, the normal control group, and Group 2, the AFB1 control group, were administered per orally, the vehicle, Tween-80 (0.5%) for two consecutive days. Groups 3–11, the plant drug-treated groups, received varying doses of the three crude extracts (IC: 100, 200 and 300 mg/kg; SC: 100, 200 and 300 mg/kg; RN: 100, 200 and 300 mg/kg) for two consecutive days (the doses were fixed based on our previous experiments). Group 12 was administered per orally the reference drug, silymarin (100 mg/kg), for two days. On the second day, the rats from Groups 2–12 were challenged with AFB1 (1.5 mg/kg, intraperitoneally) (Sigma Chemicals, Spruce Street, St Louis, MO, USA), as a 0.3% solution in dimethyl sulphoxide (DMSO), 1.5 hours after administration of the vehicle/herbal drug regimen.

All the animals were sacrificed by decapitation 72 hours following the AFB1 treatment, since liver damage following AFB1 administration is found to be severe at 72 hours post-treatment, as measured by significant changes in the activities of microsomal and serum enzymes.<sup>(9)</sup> Blood samples were collected to evaluate the biochemical parameters, and the liver tissue samples were collected for histopathological studies.

Biochemical parameters, including serum enzymes, glutamate oxaloacetate transaminase (SGOT), glutamate pyruvate transaminase (SGPT) and alkaline phosphatase (SAKP), were assayed according to the standard methods.<sup>(10,11)</sup> Reduced glutathione (GSH) was estimated by its reaction with dithio-bis-2-nitrobenzoic acid

(DTNB) that gives a yellow coloured complex with a maximum absorption of 412 nm.<sup>(12)</sup>

The antilipid peroxidant effects of the three plant extracts were studied *in vitro*, following the modified method of Yoshiyuki et al<sup>(13)</sup> and Masao et al.<sup>(14)</sup> Briefly, 0.5 g of the rat liver tissue was sliced and homogenised with 10 ml of 150 mM KCl-Tris-HCl buffer (pH 7.2). The reaction mixture was composed of 0.25 ml liver homogenate, Tris-HCl buffer (pH 7.2), 0.1 mM ascorbic acid (AA), 4 mM FeCl<sub>2</sub> and 0.05 ml of various concentrations of the three plant extracts. The mixture (in triplicate) was incubated at 37°C for one hour in capped tubes. Subsequently, 0.1 N HCl, 0.2 ml of 9.8% sodium dodecyl sulphate, 0.9 ml of distilled water and 2 ml of 0.6% thiobarbituric acid were added to each tube and vigorously shaken. The tubes were placed in a boiling water bath at 100°C for 30 minutes. After cooling, the flocculent precipitate was removed by adding 5 ml of *n*-butanol and centrifuged at 3,000 rpm for 20 minutes. The absorbance of the supernatant was measured at 532 nm.

Thick paraffin sections (thickness, 7 µm) of buffered formalin-fixed liver samples were stained with haematoxylin-eosin for photomicroscopic observations of the liver histological architecture of the control and herbal drug-treated rats. Groups of ten mice each were treated with RN, IC or SC extract at different concentrations (100, 500 and 1,000 mg/kg, per orally). They were observed continuously for one hour for any gross behavioural changes, symptoms of toxicity and mortality, if any, and intermittently for the next six hours and then again 24 hours after dosing with the extracts.

**Table II. Effect of Aflatoxin B1 (AFB1) and the plant extracts, or Silymarin on reduced glutathione levels in Wistar rats (n = 3).**

Group	GSH (nmol / mg protein)
Normal Control	0.841 ± 0.001
AFB1 (1.5 mg/kg)	0.403 ± 0.001**
AFB1 (1.5 mg/kg) + IC (100 mg/kg)	0.475 ± 0.002
AFB1 (1.5 mg/kg) + IC (200 mg/kg)	0.744 ± 0.003*
AFB1 (1.5 mg/kg) + IC (300 mg/kg)	0.482 ± 0.001
AFB1 (1.5 mg/kg) + SC (100 mg/kg)	0.465 ± 0.001
AFB1 (1.5 mg/kg) + SC (200 mg/kg)	0.520 ± 0.003
AFB1 (1.5 mg/kg) + SC (300 mg/kg)	0.682 ± 0.002*
AFB1 (1.5 mg/kg) + RN (100 mg/kg)	0.485 ± 0.002
AFB1 (1.5 mg/kg) + RN (200 mg/kg)	0.722 ± 0.001*
AFB1 (1.5 mg/kg) + RN (300 mg/kg)	0.567 ± 0.002
AFB1 (1.5 mg/kg) + Silymarin (100 mg/kg)	0.768 ± 0.001*

Values are expressed as mean ± SD. \* p ≤ 0.01 when compared to the AFB1 control. \*\* p ≤ 0.001 when compared to the normal control group.

GSH: glutathione; IC: *Ixora coccinea*; SC: *Spilanthes ciliata*; RN: *Rhinacanthus nasuta*.

The data was expressed as mean ± standard deviation (SD), and statistical comparisons were performed using Student's *t*-test.<sup>(15)</sup>

## RESULTS

The effects of the three plant extracts on AFB1-induced hepatotoxicity in rats are shown in Table I. The SGOT, SGPT and SAKP levels were elevated significantly after AFB1 injection. In contrast, treatment with IC (200 mg/kg), RN (200 mg/kg), SC (300 mg/kg) or silymarin (100 mg/kg) reduced these enzyme levels significantly. The SAKP levels of the three plant extracts also showed significant reduction, almost comparable to that of the silymarin-treated group.

Histological studies supported the biochemical findings. Liver sections of the normal control animals showed normal cellular architecture with distinct hepatic cells. The liver sections of rats intoxicated with AFB1 showed disturbed lobular architecture, ballooning, fatty degenerative changes and focal necrosis. In the AFB1 + IC, SC or RN groups, an almost normal architecture of the liver was noticed, indicating the hepatoprotection afforded by the three plant extracts IC, SC and RN. (Figs. 1–6).

Rats administered with AFB1 were found to have significantly lower levels of hepatic GSH. IC, SC and RN, when administered at 200 mg/kg, 300 mg/kg and 200 mg/kg, respectively, completely restored the decrease in GSH levels in the liver caused by AFB1 (Table II). In the silymarin-treated group, the elevation of GSH levels

was found to be almost comparable to the control values. IC, SC and RN showed significant inhibition of FeCl<sub>2</sub>-AA stimulated rat liver lipid peroxidation *in vitro* (Table III). In the toxicity study, no mortality occurred within 24 hours with the three doses of the three plant extracts tested. The LD<sub>50</sub> of IC, SC and RN was therefore greater than 1,000 mg/kg per orally in the mice (data not shown).

## DISCUSSION

AFB1 is the most abundant and toxic form of all naturally occurring aflatoxins. It is teratogenic, hepatocarcinogenic and hepatotoxic to various animal species.<sup>(16-18)</sup> AFB1 is first metabolised (Phase 1 metabolism) mainly by the Cytochrome P<sub>450</sub> enzyme (CYP450) system found in the microsomes, producing a variety of metabolites such as AFB1 epoxide and hydroxylated metabolites (AFM1, AFP1, AFQ1 and aflatoxicol). AFB1 epoxide is a very reactive and unstable metabolite of AFB1 that will bind to cellular macromolecules like DNA, RNA, lipids and proteins, leading to lipid peroxidation and cellular injury.<sup>(19)</sup> The formation of AFB1-DNA adduct is highly correlated to the carcinogenic effect in both animal and human cancers.<sup>(20)</sup> The major AFB1-DNA adduct formed in liver is aflatoxin B1-N<sup>7</sup>-guanine.<sup>(21)</sup> This adduct is unstable and subjected to decomposition in the rat liver, which culminates in the destruction of hepatic cells.

A variety of physical and chemical agents have been reported to reduce AFB1-induced hepatotoxicity via different mechanisms.<sup>(9,22)</sup> While some agents interfere with AFB1 absorption, biotransformation and covalent binding to cellular macromolecules, others enhance the detoxification of the toxin through conjugation or through quite different and unknown mechanisms. The results obtained in the present study showed that the pre-treatment of rats with the three plant extracts (IC, SC and RN) caused a significant reduction in AFB1-induced serum enzyme levels, indicating their hepatoprotective effects. The leakage of these hepatic housekeeping enzymes serves as an indirect biochemical index of hepatocellular damage.<sup>(23,24)</sup> The hepatic marker enzymes SGOT and SGPT showed significantly lower values in the plant drug-treated groups that were almost comparable to the silymarin-treated groups. It is interesting to note that the SAKP levels of the three plant extract-treated groups were significantly lower than those of the silymarin-treated groups. The ability of the extracts to reduce the serum levels of SGPT, SGOT and SAKP suggests that the protective action might have occurred at a site in the chain of events leading to cell necrosis and also at the activation steps of AFB1 required for hepatic

**Table III. Inhibitory effect of plant extracts, IC / SC / RN on FeCl<sub>2</sub> - ascorbic acid (AA) - induced lipid peroxidation in rat liver homogenate *in vitro* (n = 3).**

Treatments	Concentration (µg /ml)	MDA (n mole/g wet liver)	MDA inhibition(%)
Normal control	-	1.41 ± 1.85	-
FeCl <sub>2</sub> -AA	-	3.81 ± 1.59**	-
FeCl <sub>2</sub> -AA + IC	1	1.81 ± 2.50	50.9
FeCl <sub>2</sub> -AA + IC	5	1.31 ± 1.95*	65.6
FeCl <sub>2</sub> -AA + IC	10	2.10 ± 1.43	44.8
FeCl <sub>2</sub> -AA + SC	1	2.16 ± 1.43	47.9
FeCl <sub>2</sub> -AA + SC	5	1.21 ± 1.43*	70.8
FeCl <sub>2</sub> -AA + SC	10	1.18 ± 1.06*	71.5
FeCl <sub>2</sub> -AA + RN	1	2.23 ± 2.41	46.2
FeCl <sub>2</sub> -AA + RN	5	1.81 ± 1.72	56.3
FeCl <sub>2</sub> -AA + RN	10	1.29 ± 1.11*	68.9

Values are expressed as mean ± SD. Significance \* p ≤ 0.01 when compared to the FeCl<sub>2</sub>-AA group. \*\* p ≤ 0.001 when compared to the normal control group; MDA: malondialdehyde

cell injury. However, it is difficult to speculate on the exact protective mechanism, since only crude extracts were used in this study. We have previously reported the hepatoprotective effects of IC, SC and RN with other toxins.<sup>(5-8)</sup>

The hepatic damage is associated with an increase in the tissue malondialdehyde (MDA) level, an indirect index of lipid peroxidation. The decrease of MDA *in vitro* that was observed in the present study and the increase of hepatic GSH levels in the liver of IC, SC and RN + AFB1 treated rats indicate that the three plant extracts have significant antioxidant effects, which is important for removing free radicals and reactive intermediates generated from the metabolism of environmental toxins.

GSH, a key antioxidant, is an important constituent of intracellular protective mechanisms against various noxious stimuli, including oxidative stress. GSH depletion in hepatocyte mitochondria, has been shown to be an important mechanism in the pathology of experimental liver injury.<sup>(25)</sup> It has been reported that higher GSH levels help to lower AFB1 toxicity through conjugation with the toxin.<sup>(9)</sup> The above findings are supported by other similar studies.<sup>(22,26)</sup>

We have earlier reported that the triterpenoid ursolic acid present in *I. coccinea*, flavonoids and triterpenes present in *R. nasuta* and alkaloids, flavonoids and coumarins present in *S. ciliata* may be responsible for their antioxidant and hepatoprotective effects.<sup>(5-8)</sup> Ursolic acid and flavonoids are known to protect against chemically induced liver damage.<sup>(27,28)</sup> The present results are supported by the findings of Wu et al, who reported that the total flavonoids of *Laggera alata* had significant hepatoprotective activity against liver toxins such as

carbon tetrachloride.<sup>(29)</sup> Martin-Aragon et al reported that treatment with ursolic acid significantly reversed the decreased glutathione levels in the rat liver.<sup>(30)</sup> In their study, ursolic acid showed radical scavenging properties, which suggested that ursolic acid treatment can normalise the disturbed antioxidant status of rats by maintaining the levels of glutathione and by inhibiting the production of MDA due to its radical scavenging properties.<sup>(30)</sup> Perhaps, compounds such as ursolic acid and flavonoids that are present in IC, SC and RN are responsible for the hepatoprotective effects observed here.

The overall significance of this study is that it has demonstrated that the plant extracts, viz. IC, SC and RN, that have reported therapeutic activity against liver diseases in the traditional medicine of Kerala, also protect against AFB1-induced liver damage in rats. This may provide an impetus for further investigations on the therapeutic efficacy of the extracts and their practical application in the treatment of liver diseases. Further studies are ongoing in our laboratory to pinpoint the exact phytochemicals responsible for the hepatoprotective properties of these three plant extracts.

#### ACKNOWLEDGEMENTS

The authors are thankful to Dr S Ganeshan, the Director of the Institute, for providing permission to use the facilities and for his encouragement, Mr KP Pradeepkumar for his photographic assistance and Mr S Radhakrishna Pillai for his technical assistance. Financial assistance from the Department of Biotechnology, Government of India, New Delhi, is gratefully acknowledged.

#### REFERENCES

1. Eaton DL, Gallagher EP. Mechanisms of aflatoxin carcinogenesis.

- Annu Rev Pharmacol Toxicol 1994; 34:135-72.
2. Kodama M, Inoue F, Akao M. Enzymatic and non-enzymatic formation of free radicals from aflatoxin B1. Free Radic Res Commun 1990; 10:137-42.
  3. Shen HM, Ong CN, Lee BL, Shi CY. Aflatoxin B1-induced 8-hydroxydeoxyguanosine formation in rat hepatic DNA. Carcinogenesis 1995; 16:419-22.
  4. Shen HM, Shi CY, Shen Y, Ong CN. Detection of elevated reactive oxygen species level in cultured rat hepatocytes treated with Aflatoxin B1. Free Rad Biol Med 1996; 21:139-46.
  5. Latha PG, Suja SR, Acham A, Rajasekharan S, Panikkar KR. Hepatoprotective effects of *Ixora coccinea* flower extract on rats. J Trop Med Plants 2003; 4:33-8.
  6. Suja SR, Latha PG, Pushpangadan P, Rajasekharan S. Evaluation of hepatoprotective effects of *Rhinacanthus nasuta* root extracts. J Trop Med Plants 2003; 4:151-7.
  7. Suja SR, Latha PG, Pushpangadan P, Rajasekharan S. Assessment of hepatoprotective and free radical scavenging effects of *Rhinacanthus nasuta* (Linn.) Kurz in Wistar rats. J Nat Remedies 2003; 4:66-72.
  8. Suja SR, Latha PG, Rajasekharan S, Pushpangadan P. Antihepatotoxic activity of *Spilanthes ciliata* on paracetamol-induced liver damage in rats. Pharm Biol 2003; 41:536-40.
  9. Dalvi RR, Séré A. Protective effect of *Cochlospermum tinctorium* A. Rich extract versus Aflatoxin B induced liver damage in rats. Pharm Biol 1988; 26:117-20.
  10. Reitman S, Frankel S. A colorimetric for the determination of serum glutamic oxalacetic and glutamic pyruvic transaminases. Am J Clin Pathol 1957; 28:56-63.
  11. King, EJ, Armstrong, AR. Calcium, magnesium phosphorus and phosphatase. In: Varley B, Gowenlock AH, Bell M, eds. Practical Clinical Biochemistry, Vol. 1. 5th ed. Heinemann, London, 1980; 850-2.
  12. Moron MS, Depierre JW, Mannervik B. Levels of glutathione, glutathione reductase and glutathione S-transferase activities in rat lung and liver. Biochim Biophys Acta 1979; 582:67-78.
  13. Yoshiyuki K, Michinori K, Todato T, Shigeru A, Hiromichi O. Studies on *Scutellaria radix*. Effects of lipid peroxidation on rat liver. Chem Pharm Bull 1981; 29:610-17.
  14. Masao H, Yang XW, Miyashiro H, Nabma T. Inhibitory effects of monomeric and dimeric phenyl propanoids from mice on lipid peroxidation *in vivo* and *in vitro*. Phytotherapy Res 1993; 7: 395-401.
  15. Snedecor GW, Cochran WG. Statistical Methods. Iowa: Iowa State University Press, 1980: 75.
  16. Bassir O, Adekunle A. Teratogenic action of aflatoxin B1, palmotoxin, B0 and palmotoxin G0 on the chick embryo. J Pathol 1970; 102:49-51.
  17. Adamson RH, Correa P, Seiber SM, McIntire KR, Dalgard DW. Carcinogenicity of aflatoxin B1 in rhesus monkeys: two additional cases of primary liver cancer. J Natl Cancer Inst 1979; 57:67-78.
  18. O'Brien K, Moss E, Judah K, Neal G. Metabolic basis of the species difference to aflatoxin B1 induced hepatotoxicity. Biochem Biophys Res Commun 1983; 114:813-21.
  19. Stresser DM, Bailey GS, Williams DE. Indol-3-carbinol and beta-naphthoflavone induction of aflatoxin B1 metabolism and cytochromes P-450 associated with bioactivation and detoxication of aflatoxin B1 in the rat. Drug Metab Dispos 1994; 22:383-91.
  20. Thabrew MI, Bababunmi EA. Levels of microsomal drug-metabolizing enzymes in animals which are highly susceptible to aflatoxin carcinogenicity: a case of the duck. Cancer Lett 1980; 9:333-8.
  21. Essigmann JM, Croy RG, Nadzan AM, et al. Structural identification of the major DNA adduct formed by aflatoxin B1 *in vitro*. Proc Natl Acad Sci USA 1977; 74:1870-4.
  22. Ip SP, Mak DH, Li PC, Poon MK, Koh KM. Effect of a lignan-enriched extract of *Schisandra chinensis* on aflatoxin B1 and cadmium chloride-induced hepatotoxicity in rats. Pharmacol Toxicol 1996; 78:413-6.
  23. Recknagel RO, Lombardi B. Studies of biochemical changes in subcellular particles of rat liver and their relationship to a new hypothesis regarding the pathogenesis of carbon tetrachloride induced fat accumulation. J Biol Chem 1961; 236:564-9.
  24. Klaassen CD, Watkins JB 3rd. Mechanisms of bile formation, hepatic uptake and biliary excretion. Pharmacol Rev 1984; 36:1-67.
  25. Yuan G, Gong Z, Li J, Li X. *Ginkgo biloba* extract protects against alcohol-induced liver injury in rats. Phytother Res 2007; 21:234-8.
  26. Sohn DH, Kim YC, Oh SH, et al. Hepatoprotective and free radical scavenging effects of *Nelumbo nucifera*. Phytomedicine 2003; 10:165-9.
  27. Handa SS, Sharma A, Chakraborti K.K. Natural products and plants as liver protecting drugs. Fitoterapia 1986; 57:307-51.
  28. Liu J. Pharmacology of oleanolic acid and ursolic acid. J Ethnopharmacol 1995; 49:57-68.
  29. Wu Y, Wang F, Zheng Q, et al. Hepatoprotective effect of total flavonoids from *Laggera alata* against carbon tetrachloride-induced injury in primary cultured neonatal rat hepatocytes and in rats with hepatic damage. J Biomed Sci 2006; 13:569-78.
  30. Martin-Aragón S, de las Heras B, Sanchez-Reus MI, Benedi J. Pharmacological modification of endogenous antioxidant enzymes by ursolic acid on tetrachloride-induced liver damage in rats and primary cultures of rat hepatocytes. Exp Toxicol Pathol 2001; 53:199-206.