

Primary cutaneous nodular amyloidosis initially presenting with eczema

Gan E Y, Tey H L

ABSTRACT

We report an unusual case of a 76-year-old woman with primary cutaneous amyloidosis who initially presented with features of asteatotic eczema that was unresponsive to topical corticosteroid treatment. Histological examination revealed amyloid deposits involving the superficial and deep dermis. These lesions later gradually evolved into erythematous nodules, and a second biopsy performed 29 months after the initial presentation again revealed diffuse collections of amyloid throughout the dermis. Further investigations did not reveal evidence of systemic involvement, thus indicating a diagnosis of primary cutaneous nodular amyloidosis. The initial presentation as eczematous lesions illustrates the importance of clinicopathological correlation and subsequent follow-up.

Keywords: amyloidosis, eczema, nodular

Singapore Med J 2010; 51(9): e158-e160

INTRODUCTION

Amyloidoses are a spectrum of diseases comprising both cutaneous and systemic forms, and are characterised by extracellular deposition of amyloid protein as nonfunctional beta-pleated sheets. The cutaneous and systemic types can be further classified as either primary or secondary. Primary cutaneous amyloidoses are more commonly observed in Asians, South Americans and Middle Easterners, with the Chinese being especially predisposed.⁽¹⁾ There are four main types of primary cutaneous amyloidoses with distinctive clinical features: lichen amyloidosis, macular amyloidosis, nodular amyloidosis and amyloidosis cutis dyschromica. Atypical variants include a familial form, a bullous form,⁽²⁾ diffuse biphasic amyloidosis,⁽³⁾ poikilodermic amyloidosis,⁽⁴⁾ and predominantly hypopigmented macular amyloidosis with or without hyperpigmentation.⁽⁵⁾ We report an unusual manifestation of primary cutaneous amyloidosis initially presenting as eczema.

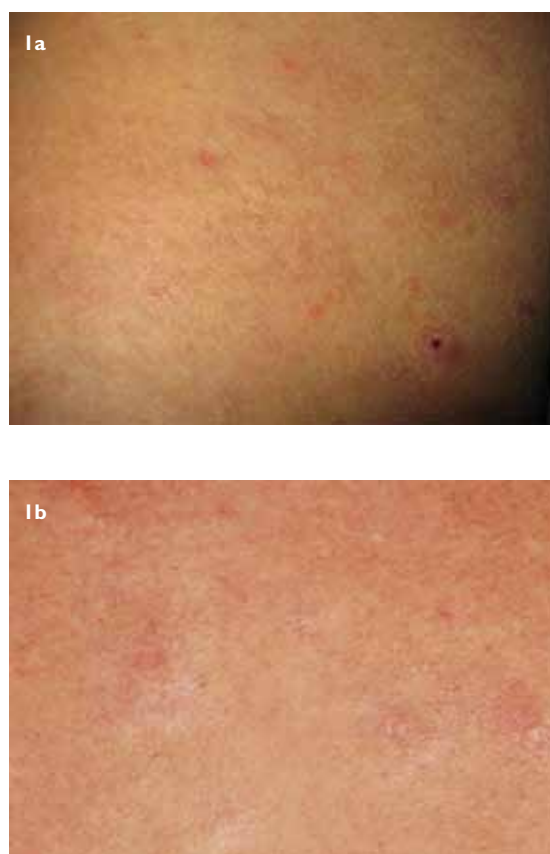

Fig. 1 Photographs show (a) eczematous excoriated papules on the patient's thigh at initial presentation and (b) dermal nodules on the patient's back three years after the initial presentation.

CASE REPORT

A 76-year-old Chinese woman was referred to the National Skin Centre, Singapore in 2006 with a four-week history of a pruritic rash over her trunk and limbs. She had been applying topical corticosteroids with no improvement and suffered from intolerable pruritus that was disrupting her sleep. Her other medical problems included hypertension, which was being treated with nifedipine, hyperlipidaemia, for which she was on diet control and a previous history of lepromatous leprosy in 1950, for which she had been successfully treated. On examination, the patient had excoriated papules and plaques scattered over her trunk, limbs and gluteal region, with urticated plaques on her upper back. In addition, generalised xerosis was observed (Fig. 1a).

National Skin Centre,
1 Mandalay Road,
Singapore 308205

Gan EY, MBBS
Medical Officer

Tey HL, MBBS, MRCP,
GDGM
Associate Consultant

Correspondence to:
Dr Emily Yiping Gan
Tel: (65) 6253 4455
Fax: (65) 6253 3225
Email: emily.ganyp@
gmail.com

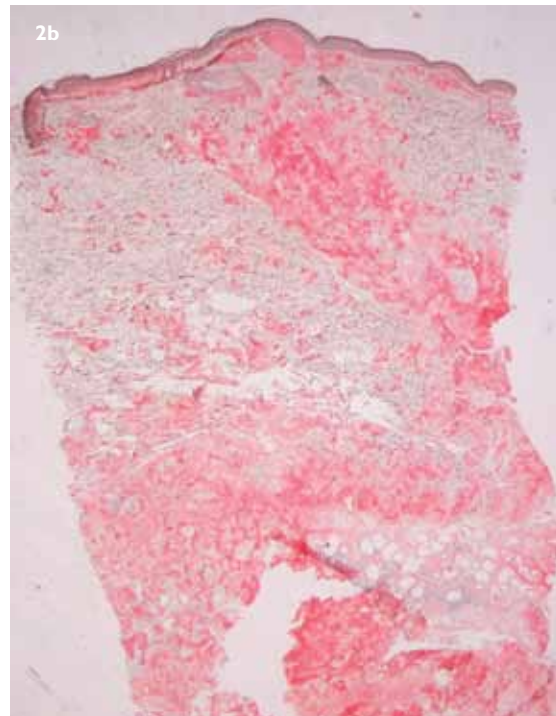
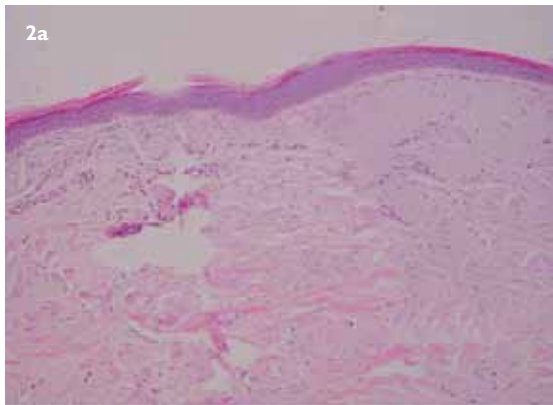


Fig. 2 Photomicrographs of the patient's eczematous lesion show (a) pale eosinophilic amorphous material throughout the dermis and between the collagen bundles. These had stained positive with Congo red. (Haematoxylin & eosin, $\times 20$) and (b) Congo red stain demonstrating diffuse collections of amyloid throughout the dermis and extending into the subcutis. (Congo red, $\times 10$).

A diagnosis of possible asteatotic eczema was made, and the patient was scheduled for a punch biopsy. Histological examination revealed abundant nests of eosinophilic deposits throughout the dermis, which extended into the subcutis. These deposits demonstrated positive staining with Congo red (Fig. 2a).

The patient was scheduled for further investigations in order to exclude systemic amyloidosis. However, she defaulted follow-up and only returned to our institution three years later, albeit for a separate problem of a callus on her right foot. Her examination at this visit revealed multiple erythematous, firm nodules that were scattered on her back, arms and legs, and which were distinctively different from those that she had initially presented with (Fig. 1b). In view of the patient's previous biopsy findings, a diagnosis of nodular amyloidosis was made. There was no clinical evidence of systemic infiltration such as organomegaly or macroglossia.

A repeat punch biopsy of one of the nodules on the patient's back confirmed the diagnosis of cutaneous amyloidosis with pale eosinophilic amorphous material between the collagen bundles, which extended throughout the dermis and stained positive with Congo red (Fig. 2b). Tests such as differential and full blood count, liver function, serum creatinine, urine and protein electrophoresis, and electrocardiogram were all unremarkable, thus confirming a lack of systemic involvement.

DISCUSSION

Nodular amyloidosis is characterised by diffuse infiltration of the dermis, subcutis and blood vessel walls with amyloid. Single or multiple nodules, or

plaques can occur in various sites, most commonly the legs, followed by the head, trunk, arms and genitalia in decreasing order of frequency. Patients may show an elevated erythrocyte sedimentation rate and beta- and gamma-globulin levels.⁽⁶⁾ Cutaneous deposition of amyloid L, which occurs in both systemic and nodular amyloidosis, appears histologically similar in both instances. Hence, it is important to evaluate for systemic involvement before diagnosing nodular amyloidosis.⁽⁷⁾ However, once nodular amyloidosis has been diagnosed, regular follow-up should be initiated as it may progress to systemic amyloidosis in 15%–50% of the cases. Various modes of treatment have been attempted for nodular amyloidosis, including surgical excision, cryotherapy, electrodesiccation and curettage as well as carbon dioxide laser, but none has shown to be consistently effective.⁽⁶⁾ Nodular amyloidosis also tends to recur as the amyloid can infiltrate the reticular dermis and subcutaneous tissues, unlike the lichen or macular variants.

Lichen amyloidosis was first reported by Gutmann in 1928 as amyloidosis localis cutis nodularis et disseminata and by Freudenthal in 1930, as lichen amyloidosis. It is characterised by the presence of multiple discrete hyperkeratotic scaly papules and plaques. Palitz and Peck described the macular variant in 1952 as a dark macular ripple pattern pigmentation distributed asymmetrically over the upper back and arms.⁽³⁾ Concurrent lichen and macular amyloidosis

in the same patient is termed as biphasic amyloidosis. Amyloidosis cutis dyschromica, on the other hand, is a different entity that is characterised by generalised dotted, reticular hyperpigmentation interspersed with hypopigmented spots.⁽⁸⁾ Unlike nodular amyloidosis, amyloid deposits in all these variants do not involve the whole span of the dermis, and cases of progression to systemic amyloidosis have not been reported.

There has been only one other report of a female patient with cutaneous amyloidosis who presented with an eczematous lesion covering the genital area. The authors described it as a slightly itchy, well-demarcated and hard-palpitory erythema.⁽⁹⁾ Biopsy revealed diffuse deposition of eosinophilic material throughout the dermis and subcutaneous fatty tissue, within the walls of the blood vessels and around fat cells, which stained positive with Congo red. The lesions in this patient regressed spontaneously over a period of 18 months.

Systemic amyloidosis is a known complication of lepromatous leprosy and has a striking association with a history of recurrent erythema nodosum leprosum reactions. Both these conditions are believed to occur due to impaired cell-mediated immunity.⁽¹⁰⁾ However, to our knowledge, there is no well-described association between leprosy and primary cutaneous amyloidosis in the literature.

As eczematous lesions are ubiquitous in all dermatology clinics, we have highlighted this interesting case of primary cutaneous nodular amyloidosis with an initial presentation of eczematous lesions. This case

demonstrates the importance of clinicopathological correlation as well as subsequent follow-up in order to study the disease evolution, since initial lesions can easily be mistaken for other disease processes, and thus reiterates the fact that making the correct diagnosis influences management decisions.

REFERENCES

1. Chang YT, Wong CK, Chow KC, Tsai CH. Apoptosis in primary cutaneous amyloidosis. *Br J Dermatol* 1999; 140:210-5.
2. Khoo BP, Tay YK. Lichen amyloidosis: a bullous variant. *Ann Acad Med Singapore* 2000; 29:105-7.
3. Wang WJ. Clinical features of cutaneous amyloidoses. *Clin Dermatol* 1990; 8:13-9.
4. Kang HY, Kang WH. Macular amyloidosis presented as poikiloderma: a case report. *J Korean Med Sci* 2000; 15:724-6.
5. Ho MS, Ho J, Tan SH. Hypopigmented macular amyloidosis with or without hyperpigmentation. *Clin Exp Dermatol* 2009; 34:e547-51.
6. Woollons A, Black MM. Nodular localized primary cutaneous amyloidosis: a long-term follow-up study. *Br J Dermatol* 2001; 145:105-9.
7. Schwendiman MN, Beachkofsky TM, Wisco OJ, Owens NM, Hodson DS. Primary cutaneous nodular amyloidosis: case report and review of the literature. *Cutis* 2009; 84:87-92.
8. Vijaikumar M, Thappa DM. Amyloidosis cutis dyschromica in two siblings. *Clin Exp Dermatol* 2001; 26:674-6.
9. Konishi A, Fukuoka M, Nishimura Y. Primary localized cutaneous amyloidosis with unusual clinical features in a patient with Sjögren's syndrome. *J Dermatol* 2007; 34:394-6.
10. Anders EM, McAdam KP, Anders RF. Cell-mediated immunity in amyloidosis secondary to lepromatous leprosy. *Clin Exp Immunol* 1977; 27:111-7.