

Persistent left superior vena cava: a possible site for haemodialysis catheter placement

Lim T C, H'ng M W C

ABSTRACT

Persistent left superior vena cava (PLSVC) is a congenital variant of the thoracic venous system, which is associated with other congenital abnormalities. Asymptomatic cases are often diagnosed incidentally during invasive cardiovascular procedures such as the deployment of central venous access devices. It is important to be aware of the existence of a PLSVC and the clinical implications that it may pose to the proceduralist during catheter placement. We describe our experience and the lessons learnt during the placement of a haemodialysis catheter via the left internal jugular venous route in a patient with unsuspected PLSVC.

Keywords: catheter, congenital variant, haemodialysis, internal jugular vein, persistent left superior vena cava

Singapore Med J 2010;51(12):e195-e197

INTRODUCTION

Persistent left superior vena cava (PLSVC) is a congenital variant of the thoracic venous system, which is known to be associated with other congenital abnormalities. Asymptomatic cases may be diagnosed incidentally during invasive cardiovascular procedures such as the deployment of central venous access devices. As there is an increasing trend of renal replacement therapy such as haemodialysis, it is important to be aware of the clinical implications a PLSVC may pose to the proceduralist during catheter placement.

CASE REPORT

A 58-year-old man with diabetes mellitus and end-stage renal failure presented with a one-day history of breathlessness that was not associated with chest pain, diaphoresis or fever. He had a history of aortic coarctation, which was surgically corrected about 30 years ago. The patient had been receiving haemodialysis via a left arteriovenous fistula (AVF). However, this was complicated by stenosis, which was refractory to

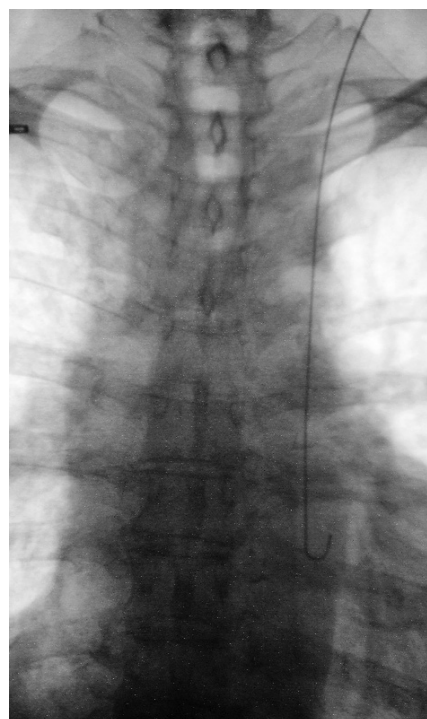

Fig. 1 Fluoroscopic image shows an unusual position of the guidewire along the left paramediastinum following left jugular venepuncture.

angioplasty, and was deemed to be unsalvageable by the vascular surgeon. Hence, he was scheduled for an insertion of a left internal jugular haemodialysis catheter in the interim, prior to the creation of a new right AVF.

A preliminary sonographic examination of the potential puncture site revealed a capacious and patent left internal jugular vein. A real-time ultrasonography-guided puncture was performed using a HemoStar 18-gauge venula, which was followed by an insertion of a guidewire under direct fluoroscopy. We noted an unusual course of the guidewire as it glided along the left paramediastinal region, following the expected course of the descending aorta (Fig. 1). Our initial impression was that of an inadvertent puncture of the left common carotid artery.

After mentally re-enacting each preceding step and ensuring that we had indeed punctured the vein rather than the artery, a BER II catheter was inserted.

**Department of
Diagnostic Imaging,
Tan Tock Seng
Hospital,
11 Jalan Tan Tock
Seng,
Singapore 308433**

Lim TC, MBBS,
MMed, FRCR
Registrar

H'ng MWC, MBBS,
MMed, FRCR
Associate Consultant

Correspondence to:
Dr Lim Tze Chwan
Tel: (65) 6357 8111
Fax: (65) 6357 8112
Email: tzechwan@
gmail.com

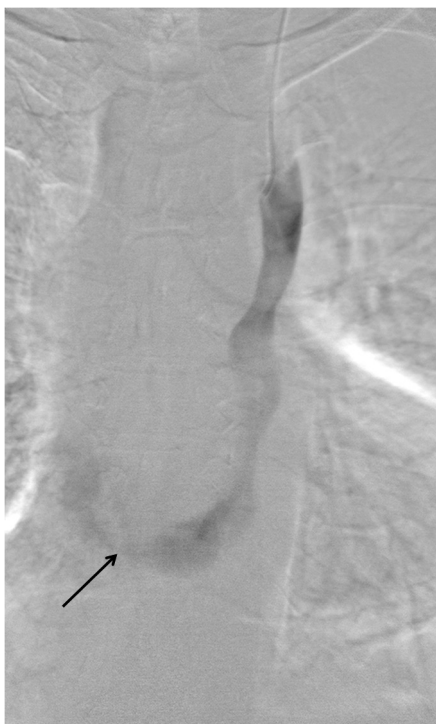

Fig. 2 Digital subtraction angiographic image shows a persistent left superior vena cava draining into the right atrium via the coronary sinus (arrow).

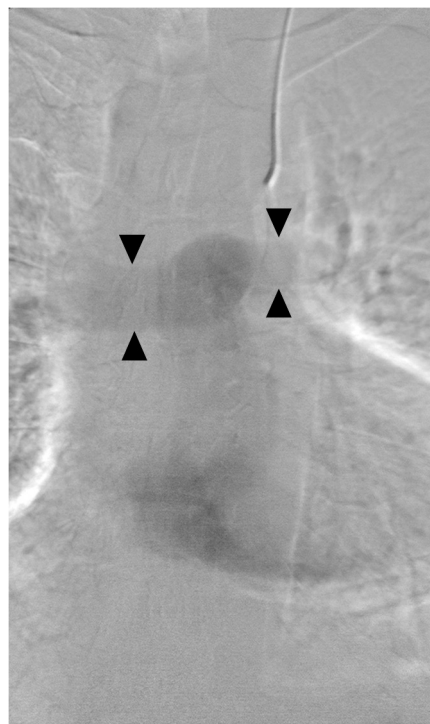

Fig. 3 Slightly delayed digital subtraction angiographic image shows subsequent opacification of the pulmonary arteries (arrowheads).

Digital subtraction angiography (DSA) (Figs. 2 & 3) revealed a PLSVC draining into the right atrium via the coronary sinus. No contrast opacification of the left heart chambers or aorta to suggest a significant vascular shunt was observed. Finally, a HemoStar haemodialysis catheter was successfully deployed within the PLSVC (Fig. 4), with satisfactory flow through both ports. A right brachiocephalic AVF was created three months after the insertion of the haemodialysis catheter. The patient was haemodialysed through this catheter for a total of five months, until maturity of the AVF.

DISCUSSION

PLSVC is a congenital variant of the thoracic venous system, with an estimated prevalence of 0.3%–0.5%.⁽¹⁾ It has been documented to be associated with other congenital abnormalities. More than 80% of the cases with PLSVC in a reported series were associated with cardiac malformation, such as complete atrioventricular septal defect and right outflow tract obstruction. The same study also showed an association between PLSVC and aortic coarctation,⁽²⁾ as was observed in our case. Although PLSVC is usually asymptomatic, there are important clinical implications during the insertion of central venous access devices.⁽³⁾

Placement of a haemodialysis catheter within a PLSVC is usually unintentional. In the process of

insertion, it may be alarming to see the guidewire descend along the expected course of the aorta. Inadvertent carotid artery puncture is a known complication of jugular venepuncture, with a reported incidence of 2%–8%.^(4,5) Although carotid artery puncture with a small-bore cannula or needle (18-gauge or smaller) is not likely to cause significant damage,⁽⁶⁾ there still lies a potential risk of severe complications, such as arteriovenous fistula and retrograde aortic dissection.^(7,8) From a practical standpoint, the duration of the procedure will be lengthened, as inadvertent arterial puncture mandates adequate manual compression prior to a repeat attempt at venepuncture.

Without the knowledge of variant venous anatomy and the anticipation of a PLSVC, a proceduralist may respond by immediately removing the venula and guidewire. In our case, the relevance of our patient's past history of aortic coarctation was recognised only in retrospect. Hence, it is prudent to anticipate the presence of a PLSVC in patients with a documented history of congenital cardiovascular abnormalities who require central venous access via the left internal jugular or subclavian route. Fortunately for us, alarming as the initial fluoroscopic images had appeared, we were certain that the guidewire was in the internal jugular vein, as venepuncture was performed under real-time ultrasonography guidance. Thus, as illustrated in our

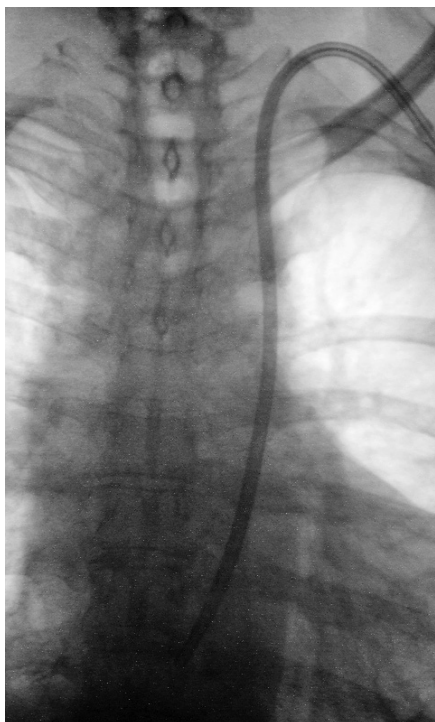


Fig. 4 Fluoroscopic image shows the final position of the haemodialysis catheter within the persistent left superior vena cava.

case, direct visualisation during vascular access is of great clinical importance.

There is an increased risk of having a coexistent cardiac shunt in a patient with PLSVC. This can be in the form of an atrial septal defect, a ventricular septal defect or a complete atrioventricular septal defect.⁽²⁾ These associated abnormalities have to be excluded prior to haemodialysis catheter placement. Small air bubbles introduced via the catheter are a source of embolism. In addition, blood clots or a fibrin sheath may form at the tip of the catheter, increasing the risk of embolisation. The presence of such a shunt may predispose one to systemic emboli and embolic stroke.⁽³⁾ Fortunately, no significant cardiac shunt was demonstrated on DSA in our patient.

Other cases of haemodialysis catheter placement within a PLSVC have been reported.^(9,10) The functionality of these catheters remains uncertain, although short-term usage is generally uneventful. Despite a rather tortuous

and angulated terminal course toward the right atrium, catheter placement in the PLSVC of our patient was uneventful and served its purpose.

PLSVC can be considered a potential site for short-term haemodialysis catheter placement. However, the possibility of a coexistent cardiac shunt has to be excluded prior to leaving the catheter within a PLSVC. An initial attempt at left internal jugular catheter placement in a patient with PLSVC can mimic an accidental arterial puncture to the unwary proceduralist. Therefore, real-time ultrasonography guidance during vascular access is important in order to ensure that the intended vessel is punctured. Identifying patients with associated risk factors for a PLSVC and recognising its angiographic appearances may help avoid unnecessary removal or repositioning of an appropriately placed device.

REFERENCES

1. Perloff JK. The clinical recognition of congenital heart disease. 5th ed. Philadelphia: Saunders, 2003.
2. Berg C, Knüppel M, Geipel A, et al. Prenatal diagnosis of persistent left superior vena cava and its associated congenital anomalies. *Ultrasound Obstet Gynecol* 2006; 27:274-80.
3. Sarodia BD, Stoller JK. Persistent left superior vena cava: case report and literature review. *Respir Care* 2000; 45:411-6.
4. Davies MJ, Cronin KD, Domaingue CM. Pulmonary artery catheterisation. An assessment of risks and benefits in 220 surgical patients. *Anaesth Intensive Care* 1982; 10:9-14.
5. Patel C, Laboy V, Venus B, Mathru M, Wier D. Acute complications of pulmonary artery catheter insertion in critically ill patients. *Crit Care Med* 1986; 14:195-7.
6. Eckhardt WF, Iaconetti J, Kwon JS, Brown E, Troianos CA. Inadvertent carotid artery cannulation during pulmonary artery catheter insertion. *J Cardiothorac Vasc Anesth* 1996; 10:283-90.
7. Gobeil F, Couture P, Girard D, Plante R. Carotid artery-internal jugular fistula: another complication following pulmonary artery catheterization via the internal jugular venous route. *Anesthesiology* 1994; 80:230-2.
8. Applebaum RM, Adelman MA, Kanschuger MS, Jacobowitz G, Kronzon I. Transesophageal echocardiographic identification of a retrograde dissection of the ascending aorta caused by inadvertent cannulation of the common carotid artery. *J Am Soc Echocardiogr* 1997; 10:749-51.
9. Jang YS, Kim SH, Lee DH, Kim DH, Seo AY. Hemodialysis catheter placement via a persistent left superior vena cava. *Clin Nephrol* 2009; 71:448-50.
10. Stylianou K, Korsavas K, Voloudaki A, et al. Can a left internal jugular catheter be used in the hemodialysis of a patient with persistent left superior vena cava? *Hemodial Int* 2007; 11:42-5.