

# MR imaging features of fibroepithelial ureteral polyp in a patient with duplicated upper urinary tract

Patheyar V, Venkatesh S K, Siew E P Y, Consiglieri D T, Putti T

## ABSTRACT

**We describe the magnetic resonance (MR) imaging features of a rare case of fibroepithelial polyp (FEP) in a duplicated upper urinary tract. The FEP appeared as a T2-hyperintense and T1-isointense filling defect within the dilated lower moiety ureter. Post gadolinium-enhanced images revealed enhancement of the FEP without ureteral wall-thickening or enhancement. Retrograde ureterography confirmed the findings, and the patient underwent ureterotomy and removal of the polyp. Histopathological findings were consistent with an FEP. It may be possible to differentiate FEP from an ureteric carcinoma based on MR imaging features. MR imaging may be useful for preoperative diagnosis of a benign ureteric tumour, and may thus prevent an unnecessary nephroureterectomy.**

**Keywords:** duplex ureter, fibroureteral polyp, MR imaging, ureteric polyp

*Singapore Med J 2011;52(3):e45-e47*

## INTRODUCTION

Blood clots, stones, strictures, valves and tumours are some of the causes of ureteral obstruction. Tumours can be benign or malignant and usually present as filling defects within the ureter. A fibroepithelial polyp (FEP) is a rare benign neoplasm of the ureter and its imaging features are similar to the more common malignant transitional cell carcinoma (TCC) on conventional computed tomography (CT) and magnetic resonance (MR) imaging. To the best of our knowledge, there is only one report of MR urography appearance of FEP, which was an incidental finding, thus reflecting the rarity of the condition and the tendency to use only conventional imaging.<sup>(1)</sup> We describe the MR imaging features of FEP, which may be useful for differentiating this rare condition from TCC.

## CASE REPORT

A 42-year-old woman presented to our institute with an asymptomatic unilateral hydronephrosis that was

incidentally picked up on screening ultrasonography. Excretory urography (EU) (Fig. 1) revealed a right-sided duplex system with smooth filling defects in the mid-right lower moiety ureter. Hydronephrosis of the lower moiety was present and the upper moiety was normal. MR imaging showed a polypoid mass in the mid-right ureter, which appeared hyperintense to the skeletal muscle on the T2-weighted images (Fig. 2) and hypo- to isointense to the muscle on the T1-weighted images. The lower moiety was hydronephrotic while the upper moiety was normal. The polyp demonstrated intense enhancement in the post-gadolinium enhanced T1-weighted images. The surrounding ureteric wall did not show any thickening or intense enhancement. The upper moiety of the right kidney, left kidney, left ureter and urinary bladder were normal, and no other focal enhancing lesions were demonstrated.

Retrograde ureterography confirmed a polypoidal-filling defect in the lower moiety ureter that was causing complete obstruction and partially extending into the common lower ureter. The patient underwent a right ureterotomy and an excision of the polyp. Frozen section at the time of surgery did not reveal any evidence of malignancy. Histopathology of the polyp showed polypoidal tissue lined by normal urothelium with cores of loose oedematous, fibrovascular stroma and mixed inflammatory infiltrate, which was consistent with an FEP. The patient is currently on clinical follow-up and has remained asymptomatic for the last two years.

## DISCUSSION

FEP is a rare benign tumour of the ureter. However, it is the most common benign mesodermal tumour of the urinary tract.<sup>(2)</sup> FEPs can occur in newborns and adults, but more commonly present in the third and fourth decades of life. The male to female ratio is 3:2.<sup>(2)</sup> Most FEPs occur in the ureter, 15% occur in the renal pelvis and a small number develop in the posterior urethra or bladder.<sup>(2)</sup> The more common ureteral FEPs have a predilection for the proximal ureter on the left side.<sup>(2)</sup> Approximately 62% of ureteral FEPs occur at the ureteropelvic junction or upper ureter.<sup>(2)</sup> They usually appear as solitary tumours; however,

Department of Diagnostic Imaging, National University Hospital, National University Health System, 5 Lower Kent Ridge Road, Singapore 119074

Patheyar V, MBBS, FRCS Registrar

Venkatesh SK, MBBS, MD, FRCS Consultant

Siew EPY, MBBS, FRCS Senior Consultant

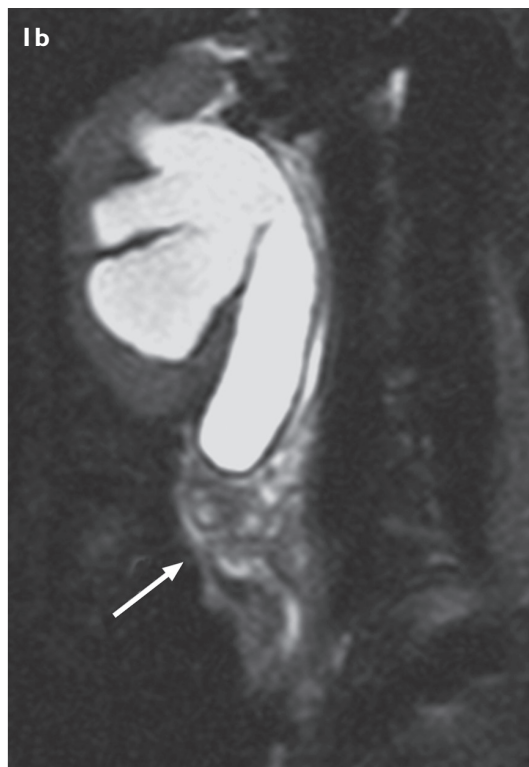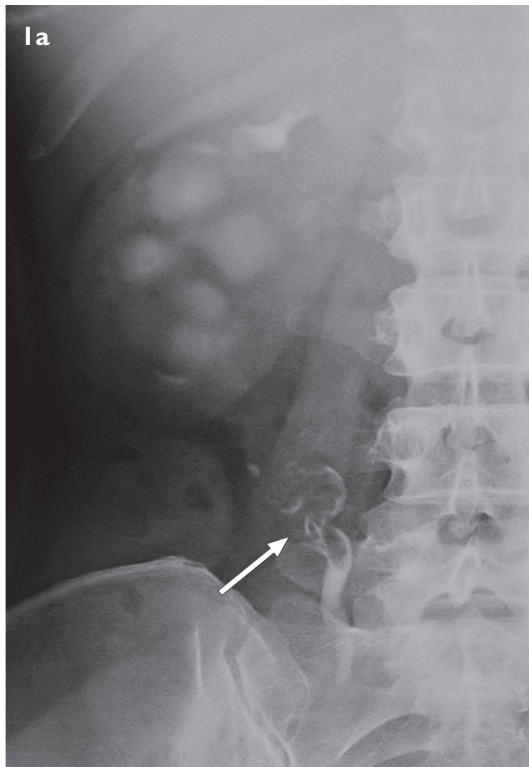
Department of Urology

Consiglieri DT, FRCSG, FAMS Senior Consultant

Department of Pathology

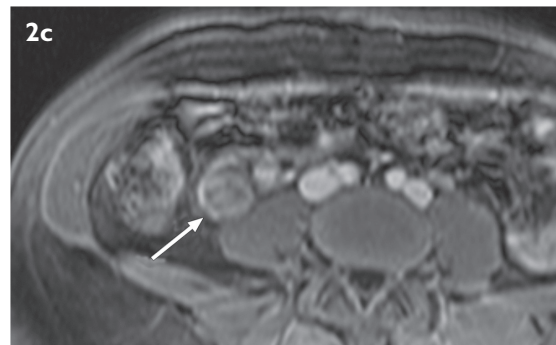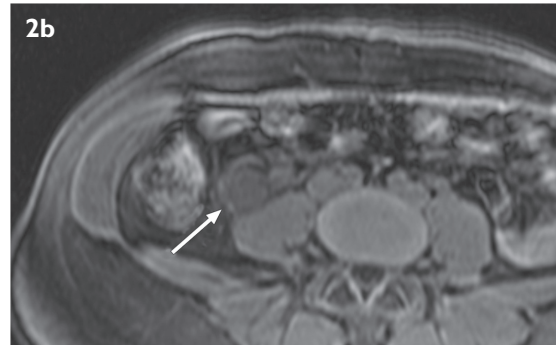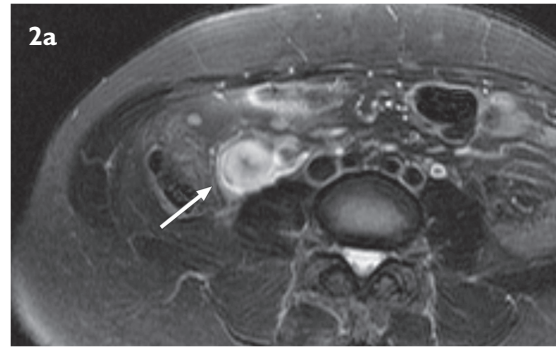
Putti T, MRCP Senior Consultant

**Correspondence to:** Dr Sudhakar K Venkatesh  
Tel: (65) 6772 2248  
Fax: (65) 6773 0190  
Email: dnrskv@nus.edu.sg



**Fig. 1** (a) Excretory urogram image shows hydronephrotic right lower moiety with smooth-filling defects (arrow) in the mid-ureter. (b) Coronal T2-W image shows the right dilated lower moiety ureter with hyperintense filling defects (arrow).

rare cases of multiple and bilateral appearances have been reported.<sup>(3)</sup> FEPs are mesodermal lesions consisting of hyperplastic fibroconnective tissue with a vascular stroma that is surrounded by transitional epithelium.<sup>(4)</sup>



**Fig. 2** (a) Fat-suppressed axial T2-W MR image at the level of the fibroepithelial polyp shows the right ureter that is distended with a hyperintense filling defect corresponding to the polyp (arrow). Axial T1-W MR image (b) before gadolinium shows a hypointense filling defect corresponding to the polyp (arrow) (c) that enhances on the post-gadolinium image.

These polyps are classified as benign hamartomas due to their histological organisation; however, malignant degeneration has previously been reported.<sup>(5)</sup>

Most patients with FEP present with flank pain and/or haematuria. However, due to the overlap in clinical presentations and radiological findings with the more common lesions like ureteral stones, blood clots and TCC, FEPs are a challenge to diagnose preoperatively,<sup>(2,7)</sup> and the diagnosis is usually made at surgery for a presumed malignant neoplasm.<sup>(7)</sup> Since FEP is a benign tumour, a conservative approach with endourological excision of ureteral FEP is now preferred rather than radical nephroureterectomy.<sup>(7)</sup> A preoperative radiological diagnosis is important and would help in surgical planning and decision.

However, preoperative radiological diagnosis of

**Table I. Comparison of MR imaging appearances of fibroepithelial polyp and transitional cell carcinoma.**

MR imaging features	Fibroepithelial polyp	Transitional cell carcinoma
T1-W*	Hypointense	Hypo- to isointensity
T2-W*	Hyperintense	Hypo- to isointensity
Post IV gadolinium	Intense enhancement	Mild to moderate enhancement
Ureteric wall	Normal and no post-gadolinium enhancement	Thickened and may show post-gadolinium enhancement

\* Signal intensity compared to the skeletal muscle.

MR: magnetic resonance; IV: intravenous; T1-W: T1-weighted; T2-W: T2-weighted

an FEP is difficult. Excretory urography and retrograde urography usually show an elongated, smooth ureteral filling defect within the renal pelvis or ureter that is surrounded by contrast material. Aside from the implantation zone, an FEP may show mobility and change position between images, unlike the fixation that is encountered with most TCCs.<sup>(8)</sup> On CT, FEPs are usually seen as a filling defect with a surrounding, continuous rim of contrast. This filling defect is usually attached to one part of the ureteral wall; this feature may aid in diagnosis.<sup>(8)</sup> However, blood clots and ureteric stones can also appear as hypodense filling defects and may thus appear to be indistinguishable from an FEP.

In our case, FEP was hyperintense to the skeletal muscle on the T2-weighted images and hypointense on the T1-weighted images, with intense post-contrast enhancement. These features are dissimilar to TCC of the urinary tract, which are hypo- to isointense to the skeletal muscle on T2 images, hypointense to intermediate signal intensity on T1 images and show moderate enhancement in post-contrast images.<sup>(9-11)</sup> Both TCCs and FEPs have lower signal intensity than the normal high signal intensity of urine on T2-weighted images, permitting good demonstration of the tumour in a dilated collecting system. The normal ureteral wall is thin and mildly enhancing after IV contrast administration in both CT and MR imaging. Recently, it has been shown that the ureteral wall at the site of a TCC appeared to be thickened on fat suppressed T1-weighted images. This occurs due to the proliferation of fibrous tissue and the wall enhances more intensely than TCC on post-gadolinium-enhanced images.<sup>(11)</sup> The ureteral wall at the site of the FEP in our case did not show thickening or abnormal post-gadolinium enhancement. This may be another important differentiating feature for distinguishing ureteral FEP from ureteral TCC.

T2-hyperintensity and intense enhancement of polyps without ureteric wall-thickening or enhancement may be important features that suggest a diagnosis of FEP (Table I). However, the findings should be validated by future studies. Furthermore, MR imaging does not involve radiation exposure unlike excretory urography and CT, and thus it may be a valuable imaging tool for characterising suspected benign ureteral lesions, as well as for differentiating a ureteral FEP from a TCC preoperatively.

## REFERENCES

- Lai TK, Chung CH, Chin AC, et al. Magnetic resonance imaging for ureteral fibroepithelial polyp. *Hong Kong Med J* 2008; 14: 408-10.
- Williams TR, Wagner BJ, Corse WR, Vestevich JC. Fibroepithelial polyps of the urinary tract. *Abdom Imaging* 2002; 27:217-21.
- Kiel H, Ullrich T, Roessler W, Wieland WF, Knuechel-Clarke R. Benign ureteral tumors: four case reports and a review of the literature. *Urol Int* 1999; 63:210-5.
- Chen WF, Huang SC, Yu TJ, Chen WJ. Benign ureteral polyp as a cause of obstruction in a child. *Pediatr Surg Int* 1994; 9:436-7.
- Zervas A, Rassidakis G, Nakopoulou L, et al. Transitional cell carcinoma arising from a fibroepithelial ureteral polyp in a patient with duplicated upper urinary tract. *J Urol* 1997; 157:2252-3.
- Kumar A, Das SK, Trivedi S, Dwivedi US, Singh PB. Genitourinary polyps: summary of the 10-year experiences of a single institute. *Int Urol Nephrol* 2008; 40:901-7.
- Faerber GJ, Ahmed MM, Marcovich R, Crisco CP, Belville WD. Contemporary diagnosis and treatment of fibroepithelial ureteral polyp. *J Endourol* 1999; 11:349-51.
- Harvin HJ. Ureteral fibroepithelial polyp on MDCT urography. *Am J Roentgenol* 2006; 187:434-35.
- Browne RF, Meehan CP, Colville J, Power R, Torreggiani WC. Transitional cell carcinoma of the upper urinary tract: spectrum of imaging findings. *Radiographics* 2005; 25:1609-27.
- Wong-You-Cheong JJ, Wagner BJ, Davis CJ Jr. Transitional cell carcinoma of the urinary tract: radiologic-pathologic correlation. *Radiographics* 1998; 18:123-42.
- Obuchi M, Ishigami K, Takahashi K, et al. Gadolinium enhanced fat suppressed T1-weighted imaging for staging ureteral carcinoma: correlation with histopathology. *AJR Am J Roentgenol* 2007; 188:W256-61.