

Prenatal diagnosis of trisomy 9

Zuzarte R, Tan J V, Wee H Y, Yeo G S

ABSTRACT

We present a foetus affected by trisomy 9, a rare chromosomal disorder, which was diagnosed in a low-risk patient during the first trimester of pregnancy. The finding of multiple structural foetal anomalies at the first trimester screening prompted chorionic villus sampling. Evaluation of quantitative fluorescent polymerase chain reaction was normal, but the final karyotype result revealed a diagnosis of trisomy 9. First trimester screening for the detection of foetal anomalies is highly effective. Although rapid molecular methods are available for prenatal diagnosis of common autosomal and sex chromosome aneuploidies, it is essential obtain a full karyotype in order to exclude the less commonly encountered chromosomal abnormalities.

Keywords: first trimester screening, prenatal diagnosis

Singapore Med J 2011;52(7):e150-e152

INTRODUCTION

Trisomy 9 is a rare chromosomal disorder that was first reported in 1973.⁽¹⁾ We describe a rare instance where trisomy 9 was diagnosed consequent to the finding of a constellation of ultrasonographic abnormalities. The condition was detected in an unselected, low-risk patient during the first trimester of pregnancy.

CASE REPORT

The patient was a 30-year-old primigravida who had been receiving antenatal care at our hospital since the sixth week of gestation. She had no medical history and was in a non-consanguineous marriage. Upon her first trimester screening (FTS) at 13 weeks' gestation, the foetus was found to have thickened nuchal translucency (NT) of 3.4 mm (Fig. 1a) and absent nasal bone. Using the algorithm provided by the Fetal Medicine Foundation, the adjusted risk for trisomy 21 was 1:30 and that for trisomies 13 and 18 was 1:161. In addition, there was a prominent posterior fossa cyst (Fig. 1b) that was suggestive of Dandy-Walker malformation, as well as a single umbilical artery, hypoplastic mandible (Fig. 1c) and a possible single ventricle heart. At 13 weeks and two

days' gestation, the patient underwent chorionic villus sampling (CVS) with quantitative fluorescent polymerase chain reaction (QF-PCR) evaluation for chromosomes 21, 13, 18, X and Y.

The QF-PCR result did not show any chromosomal abnormalities; however, repeat ultrasonography at 14 weeks' gestation revealed the same foetal structural abnormalities with additional cardiac anomalies, including dextrocardia, small left ventricle and a possible single outflow tract. In view of the multiple ultrasonographic abnormalities, the patient opted to terminate the pregnancy through the application of intravaginal prostaglandin. A malformed foetus with a body weight of 200 g was delivered. Postmortem evaluation was declined, but external examination of the abortus revealed facial dysmorphism and features of severe micrognathia (Fig. 2). The karyotype of the CVS sample, which was subsequently available at 15 weeks' gestation, revealed a karyotype of 47, XY, +9.

DISCUSSION

Trisomy 9 is characterised by the presence of multiple structural anomalies involving primarily the brain, face, heart, kidneys and limbs, in association with neurodevelopmental delay and growth deficiency.⁽²⁾ The incidence and severity of malformations and mental deficiency correlates with the extent of triplicated material. Mental retardation occurs in almost all patients. Complete trisomy 9 has a lethal prognosis. The majority of trisomy 9 pregnancies end in early spontaneous miscarriage. On rare occasions, a trisomy 9 pregnancy may progress into the later stages of pregnancy, when characteristic features may be detected by antenatal ultrasonography.⁽³⁾ However, most of these foetuses are trisomy 9 mosaics.⁽²⁾ In the exceptional event that the foetus survives to term, death usually occurs during the neonatal period. McDuffie found that only 25% (three out of 12) of live-born infants live beyond one week.⁽⁴⁾ To our knowledge, there have not been any long-term survivors with complete trisomy 9 to date.

Most of the cases in the literature document the occurrence of trisomy 9 in mothers younger than 35 years of age, rather than in those of advanced maternal age.⁽³⁻⁷⁾ This underlines the importance of foetal ultrasonography as a screening method in the low-risk population. The sonographic characteristics of trisomy 9 overlap with those

**Department of
Obstetrics and
Gynaecology,
KK Women's and
Children's Hospital,
100 Bukit Timah
Road,
Singapore 229899**

Zuzarte R, MBBS,
MRCOG, MMed
Associate Consultant

Wee HY, MBBS,
BAO, MRCOG
Consultant

**Department of
Maternal-Fetal
Medicine**

Tan J V, MBBS,
MRCOG
Consultant

Yeo GS, MBBS,
FRCOG, FAMS
Senior Consultant and
Chief of Obstetrics

Correspondence to:
Dr Regina Zuzarte
Tel: (65) 6394 1062
Fax: (65) 6298 6343
Email: drrzuzarte@
gmail.com

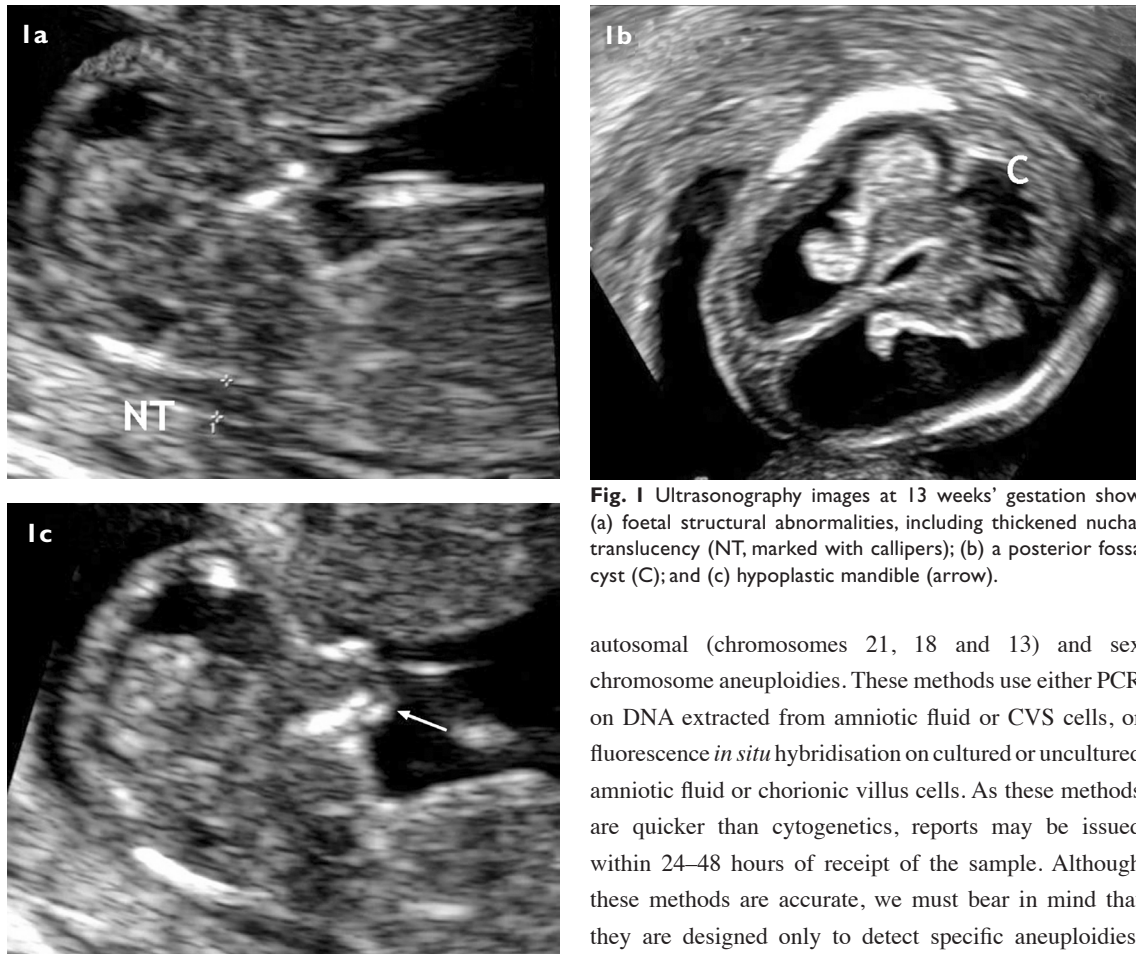


Fig. 1 Ultrasonography images at 13 weeks' gestation show (a) foetal structural abnormalities, including thickened nuchal translucency (NT, marked with callipers); (b) a posterior fossa cyst (C); and (c) hypoplastic mandible (arrow).

of trisomy 18, with the most prominent ultrasonographic findings being thickened NT, intrauterine growth restriction, craniofacial dysmorphism, central nervous system defects (Dandy-Walker malformation, absent cerebellar vermis or megacisterna magna), congenital heart defects, genitourinary anomalies and skeletal defects (lumbosacral spina bifida).^(3,7,8) This case describes the ultrasonographic anomalies of trisomy 9, which were detected during the first trimester ultrasonography. It also illustrates one of the rarer causes of an abnormal NT test.

Maternal serum marker trends are similar for trisomies 9 and 18. It is well established that maternal serum free- β hcg and pregnancy-associated plasma protein A (PAPP-A) levels are significantly decreased in pregnancies affected by trisomy 18. Previous reports in the literature have described an association between complete trisomy 9, low free- β hcg and low PAPP-A levels.^(6,9) A correlation has also been reported between elevated maternal serum alpha-fetoprotein and complete trisomy 9 associated with spina bifida.⁽⁵⁾ In this case, however, the manifold ultrasonographic findings obviated the need to proceed with serum testing.

Besides conventional karyotyping, molecular methods are available for prenatal diagnosis of common

autosomal (chromosomes 21, 18 and 13) and sex chromosome aneuploidies. These methods use either PCR on DNA extracted from amniotic fluid or CVS cells, or fluorescence *in situ* hybridisation on cultured or uncultured amniotic fluid or chorionic villus cells. As these methods are quicker than cytogenetics, reports may be issued within 24–48 hours of receipt of the sample. Although these methods are accurate, we must bear in mind that they are designed only to detect specific aneuploidies. In addition, they are inadequate for detecting mosaicism or structural rearrangements. Hence, the sole reliance on rapid testing methods and the omission of full karyotype analysis in patients at high risk of aneuploidy would lead to chromosome abnormalities being undetected in a significant number of cases (1%–30%). In a study of 8,637 amniocentesis and CVS samples conducted at our institution, 2.5% (219 samples) produced abnormal karyotypes. It was estimated that 37% of these abnormal karyotypes (82 out of 219 samples) would have been missed if the diagnosis was based solely on PCR results. Significantly, 10% of the affected fetuses (20 out of 219 samples) that were undetected by rapid testing alone were at high risk of serious physical developmental and intellectual disabilities (unpublished data).

Proponents of rapid testing opine that the total number of high-risk abnormal karyotypes represents merely 0.1% of women referred for invasive prenatal testing, and the number of women who deliver babies with congenital abnormalities is likely to be lower than this figure, as some abnormal pregnancies are destined to miscarry. Furthermore, full karyotyping would reveal translocations and minor deletions, many of which are benign. Therefore, it is concluded that the omission of full karyotyping prevents the uncertainties caused by the

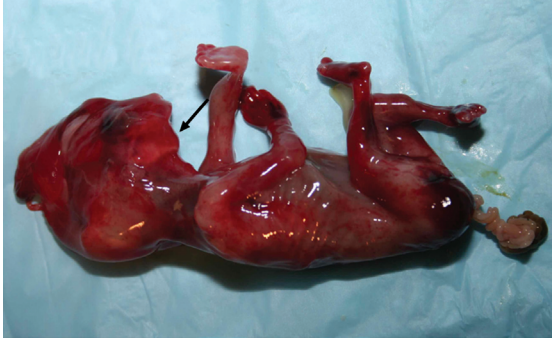


Fig. 2 Photograph of the abortus shows severe micrognathia (arrow) corresponding to ultrasonographic findings.

identification of such results of unknown prognosis, and thus simplifies counselling.⁽¹⁰⁾

Nevertheless, as many as 30% of cases with supernumerary marker chromosomes are associated with a significant risk of an abnormal outcome, and others are associated with profound developmental and intellectual handicap.^(11,12) The intended rate of invasive testing based on FTS results is 5%. Therefore, using our institutional data (unpublished), if all mothers in an institution delivering an excess of 10,000 babies per annum undergo FTS, 500 (5%) fetuses would be subjected to invasive testing, of which 12 (2.5%) would have an abnormal karyotype. The omission of full karyotyping for these 500 fetuses would save S\$50,000 per annum. However, as we estimate that 10% of affected fetuses that are undetected by rapid testing alone are in fact at high risk of disability, 1.2 severely handicapped children would be born per annum. Medical care for each of these children alone is estimated to cost S\$20,000 annually. Considering other costs, such as special education and loss of parental income from discontinuation of employment to provide childcare, the cost of raising these disabled children would exceed the savings from omission of full karyotyping. With these considerations, we have reservations that rapid testing alone is justifiable.

Initially established as a reliable screening method for Down's syndrome at 11–14 weeks' gestation, FTS has emerged as an effective tool for detection of foetal structural anomalies and other chromosomal defects. The detection of foetal anomalies in early pregnancy offers advantages for expectant mothers. Firstly, this may provide an opportunity for the pregnant woman to be better informed when deciding on invasive procedures such as CVS or amniocentesis in order to arrive at a more precise diagnosis. Mothers tend to be fearful of amniocentesis-related pain and miscarriage, but careful pre-procedure counselling may reduce anxiety.⁽¹³⁾ Secondly, this allows for early intervention through counselling on prognosis and postnatal management, and provides the option of

an earlier termination of pregnancy for a mother who is unable to accept continuing the pregnancy or having a severely handicapped child. Nevertheless, as certain structural abnormalities are more easily detectable during the second trimester, the conventional 20-week foetal anomaly imaging should not be abandoned.

In conclusion, trisomies 21, 18 and 13, and X and Y chromosomal disorders represent over 80% of all chromosome abnormalities detected by karyotyping. FTS is an excellent screening strategy for chromosomal defects and major foetal structural anomalies. When a chromosomal defect is suspected at FTS, rapid molecular methods are advantageous in providing a preliminary karyotype analysis. However, to arrive at a conclusive diagnosis, conventional cytogenetics to obtain a full karyotype remains essential in order to exclude the less commonly encountered chromosomal abnormalities.

ACKNOWLEDGEMENTS

We would like to thank Mr Yong Min Hwee, Principal Scientific Officer of Cytogenetics Laboratory, KK Women's and Children's Hospital, for his invaluable assistance.

REFERENCES

1. Feingold M, Atkins L. A case of trisomy 9. *J Med Genet* 1973; 10:184-7.
2. Jones KL. *Smith's Recognizable Patterns of Human Malformation (Major Problems in Pathology)*. 5th ed. Philadelphia: Saunders, 1996.
3. Benacerraf BR, Pauker S, Quade BJ, Bieber FR. Prenatal sonography in trisomy 9. *Prenat Diagn* 1992; 12:175-81.
4. McDuffie RS Jr. Complete trisomy 9: a case report with ultrasound findings. *Am J Perinatol* 1994; 11:80-4.
5. Chen CP, Chern SR, Cheng SJ, et al. Second-trimester diagnosis of complete trisomy 9 associated with abnormal maternal serum screen results, open sacral spina bifida and congenital diaphragmatic hernia, and review of the literature. *Prenat Diagn* 2004; 24:455-62.
6. Priola V, De Vivo A, Imbesi G, Azzerboni A, Triolo O. Trisomy 9 associated with maternal serum screening results positive for trisomy 18. Case report and review of the literature. *Prenat Diagn* 2007; 27:1167-9.
7. Yeo L, Waldron R, Lashley S, Day-Salvatore D, Vintzileos AM. Prenatal sonographic findings associated with nonmosaic trisomy 9 and literature review. *J Ultrasound Med* 2003; 22:425-30.
8. Sepulveda W, Wimalasundera RC, Taylor MJ, et al. Prenatal ultrasound findings in complete trisomy 9. *Ultrasound Obstet Gynecol* 2003; 22:479-83.
9. Quigg MH, Diment S, Roberson J. Second-trimester diagnosis of trisomy 9 associated with abnormal maternal serum screening results. *Prenat Diagn* 2005; 25:966-7.
10. Mackie Ogilvie C, Flinter F. Prenatal diagnosis. *Lancet* 2005; 366:1159-60.
11. Crolla JA. FISH and molecular studies of autosomal supernumerary marker chromosomes excluding those derived from chromosome 15, II. Review of the literature. *Am J Med Genet* 1998; 75:367-81.
12. Webb T. Inv dup(15) supernumerary marker chromosomes. *J Med Genet* 1994; 31:585-94.
13. Ng CC, Lai FM, Yeo GS. Assessment of maternal anxiety levels before and after amniocentesis. *Singapore Med J* 2004; 45:370-4.