

Primary cutaneous precursor B-cell lymphoblastic lymphoma with late dissemination

Bandyopadhyay R, Bandyopadhyay S K, Dhua D, Roy S

ABSTRACT

A 20-year-old woman presented with multiple painless nodular swellings on the skin of the extremities and face, without any systemic symptoms. Biopsy with immunohistochemistry revealed a diagnosis of precursor B-cell lymphoblastic lymphoma. There was no extracutaneous site of involvement. The patient denied chemotherapy and was subsequently lost to follow-up. She presented with symptomatic disseminated disease 18 months later and rapidly succumbed to her illness.

Keywords: precursor B-cell lymphoblastic lymphoma, skin

Singapore Med J 2011; 52(12): e258–e261

INTRODUCTION

Precursor B-cell lymphoblastic lymphoma (pre B-LBL) is an uncommon high-grade neoplasm of immature B cells. In contrast to the more common lymphoblastic lymphoma of T-cell lineage, B-LBL can be an extranodal disease, with a propensity to involve the skin and bone.⁽¹⁾ Most reported cases of B-LBL in the skin, a rarity in adults, are manifestations of existing systemic disease.⁽¹⁾ We report the case of a young woman with pre B-LBL, in which cutaneous presentation pre-dated the systemic dissemination by nearly two years.

CASE REPORT

A 20-year-old woman presented with multiple, slow-growing, painless nodular swellings in different parts of her body over a period of six months. The lesions first appeared on the antecubital skin of her left forearm, followed by similar swellings on her left leg, left axilla and the right side of the cheek, appearing in that order within a period of one month. They were not accompanied by any redness, pain, raised local temperature, sensory abnormality or motor weakness. There was no history of fever, abdominal pain, vomiting, weight loss, bleeding manifestations, headache, convulsions or respiratory/urinary symptoms. Neither

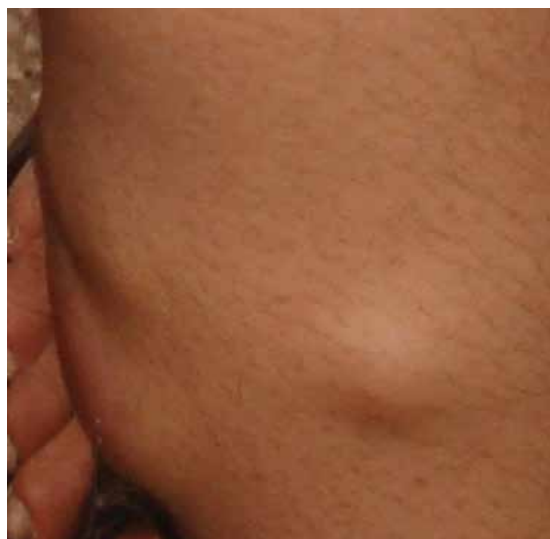

Fig. 1 Photograph shows multiple nodular cutaneous swellings on the patient's left leg.

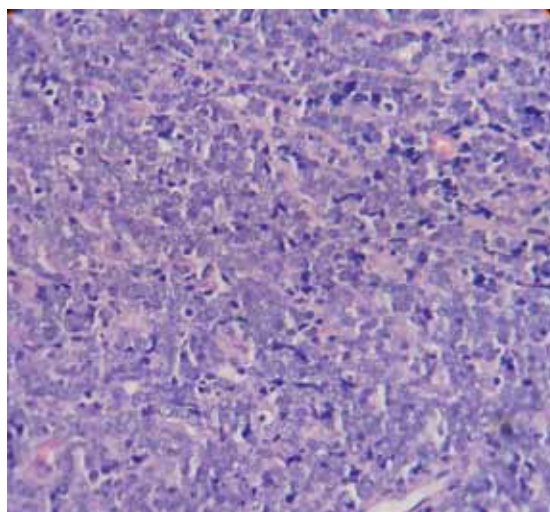


Fig. 2 Photomicrograph of the cutaneous nodule shows monomorphic atypical lymphoid cells with stippled chromatin, scanty cytoplasm and abundant mitosis (Haematoxylin & eosin, × 400).

was there a history of exposure to drugs, pets, tuberculosis or unprotected sexual intercourse. The patient had given birth two years ago, and the entire period of pregnancy and puerperium was uneventful. The rest of her personal and family history was non-contributory.

Department of Pathology,
Medical College,
88 College Street,
Kolkata 700073,
India

Bandyopadhyay R,
MD
Assistant Professor

Department of Medicine,
Nil Ratan Sircar
Medical College and
Hospital,
138 A,
JC Bose Road,
Kolkata 700014,
India

Bandyopadhyay SK,
MD, DNB, DM
Assistant Professor

Dhua D, MBBS
Resident

Roy S, MBBS
Resident

Correspondence to:
Dr Sanjay K
Bandyopadhyay
Tel: (91) 33 2664 0883
Fax: (91) 33 2321 6940
Email: drsanjay_b
@rediffmail.com

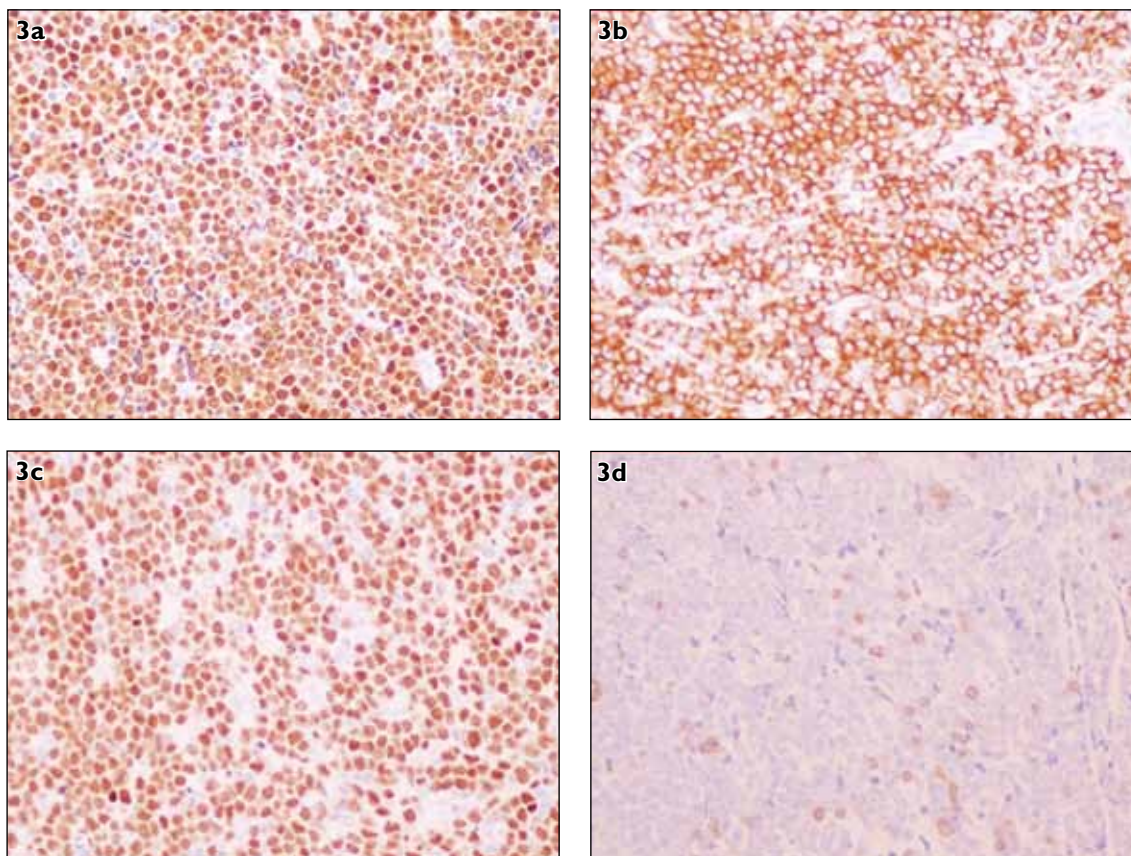


Fig. 3 Photomicrograph shows (a) TdT positive cells on immunohistochemistry (Nuclear staining, $\times 200$); (b) cells expressing CD10 on immunohistochemistry (Cytoplasmic stain, $\times 200$); (c) cells expressing Pax-5 on immunohistochemistry (Nuclear stain, $\times 200$); and (d) CD3 demonstrating negative staining pattern (Immunohistochemical stain, $\times 200$).

On examination, mild pallor was present, but there was no jaundice or lymphadenopathy. Multiple nodular swellings were observed on the patient's left forearm, left leg (Fig. 1), left axilla and below the lower right eyelid. These swellings varied in size, were soft to the touch, non-tender and fixed to the skin (but not to the underlying structures), and they had no local signs of inflammation. There was no hepatosplenomegaly or bone tenderness. The rest of the examination, including ophthalmoscopy, was uneventful.

Routine investigations revealed low haemoglobin (8.9 g/dL), normocytic normochromic red cells, high sedimentation rate (52 mm at the first hour) with normal leucocyte count, differentials and platelet count. Renal and liver biochemical parameters were also within normal limits. Chest radiography and abdominal ultrasonography were normal. Biopsy of one left forearm nodule revealed sheets of monomorphic atypical lymphoid cells with stippled chromatin and scanty cytoplasm (Fig. 2). A large number of mitotic figures were also observed. This finding was consistent with non-Hodgkin's lymphoma (NHL), in particular, NHL of the diffuse, high-grade, lymphoblastic type. On immunohistochemistry, the tumour cells were shown to express TdT, CD 9a, CD10 and Pax-5, but

were negative for CD20 and CD3, suggesting a pre-B phenotype (Fig. 3). Serum lactate dehydrogenase (LDH) level was elevated (695 IU/L). Bone marrow trephine biopsy revealed mild erythroid hyperplasia. A diagnosis of pre B-LBL with primary cutaneous involvement was made. The patient was advised to undergo combination chemotherapy, but she refused further treatment and was lost to follow-up.

The patient presented again 18 months later with high-grade fever, weight loss and episodic colicky pain in the abdomen, all present for three months. Examination revealed extensive cutaneous involvement, with numerous lobulated, soft and tender swellings having an excoriated surface (Fig. 4), severe pallor, bilateral axillary lymph nodes, bone tenderness, moderate hepatosplenomegaly and a poorly defined retroperitoneal lump at the periumbilical area. Contrast-enhanced computed tomography (CECT) of the abdomen revealed conglomerate, enlarged bilateral retroperitoneal lymphadenopathy extending below and up to the aortic bifurcation (Fig. 5). Routine haemogram showed pancytopenia. Biochemical investigations revealed low albumin (2.6 g/dL) and elevated alkaline phosphatase and LDH (729 IU/L). Biopsy re-confirmed the histology of

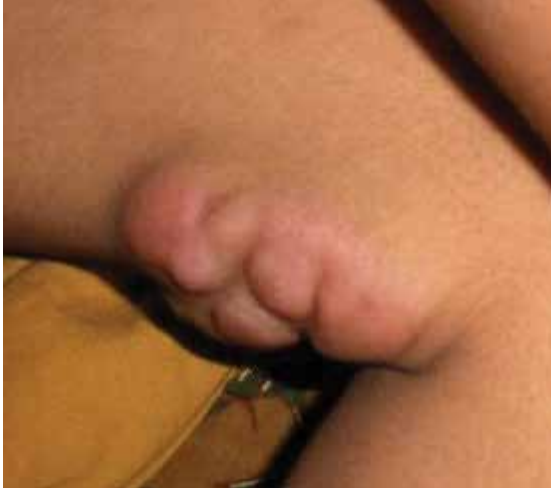

Fig. 4 Photograph shows one lobulated cutaneous swelling in the left thigh with excoriated surface.

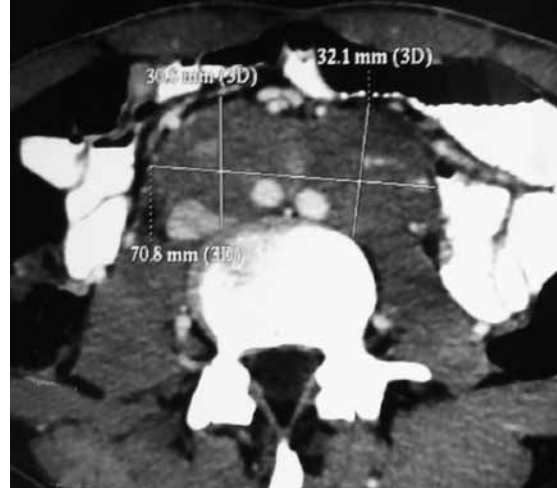


Fig. 5 Axial CECT image of the abdomen shows conglomerate, enlarged, bilateral retroperitoneal lymphadenopathy.

pre B-LBL. Chest radiography was normal. Bone marrow trephine biopsy showed sheets of monomorphic atypical lymphoid cells of pre B-cell phenotype. The patient succumbed to her illness four days after admission while being prepared for induction chemotherapy.

DISCUSSION

Pre B-LBL is an uncommon high-grade neoplasm of immature B-cells.⁽¹⁾ According to the World Health Organization (WHO) classification of NHL, it has been classified as precursor lymphoid neoplasm. It can involve the blood and bone marrow, and may occasionally present with primary involvement of nodal or extranodal sites (B-LBL/LBL). By convention, the term 'lymphoma' is used when the process is confined to a mass lesion, with no evidence of peripheral blood involvement and none to less than 25% blasts in the bone marrow.⁽²⁾ The most common sites of involvement are the skin, soft tissues, bone and lymph nodes. Unlike acute lymphoblastic leukaemia (ALL), in which 85% of the tumours belong to the B-cell lineage,⁽³⁾ less than 10% of LBL express B-cell markers. In contrast to the more common LBL of T-cell lineage, pre B-LBL can be an extranodal disease, with a propensity to involve the skin and bone.⁽¹⁾ Primary cutaneous involvement in pre B-LBL accounts for < 1% of all NHLs.⁽⁴⁾ In one large series on cutaneous involvement in LL/LBL, 24 of 1,359 children (1.8%) had skin lesions at the time of diagnosis, nine of which were cases of LBL.⁽⁵⁾ Pre B-LBL is more common in children (median age is ten years), with a tropism for the head and neck region.⁽¹⁾ Interestingly, in our patient, the lesions were located in the forearms and legs, in addition to the face.

In one series, most of the reported cases were associated with disease at other sites, such as the conjunctiva, lymph nodes, mediastinum, bone marrow, stomach and breast.⁽⁶⁾ Most patients with pre B-LBL have a high rate of complete remission and favourable outcome (74% survival at a median follow-up of 26 months).⁽²⁾ In the present case, the patient refused treatment in the initial phase; hence, the follow-up cannot be compared with cases where the patients were successfully treated. Pre B-LBL is similar to B-cell ALL in many aspects. However, some authors have highlighted differences such as frequency of skin involvement and cytogenetic abnormalities, and have suggested that a multicentre study is required in order to conclude whether this entity needs separate consideration.⁽²⁾

Histologically, pre B-LBL must be differentiated from other high-grade lymphoid tumours and small 'blue round cell' tumours, including Ewing's sarcoma.⁽⁷⁾ Due to the common absence of mature B-cell markers (e.g. CD20) in immunohistochemical studies, pre B-LBL may present a diagnostic challenge.⁽⁸⁾ In the absence of prospective studies for this population, patients are treated currently with intensive ALL regimens.⁽¹⁾

Our patient was diagnosed with pre B-LBL at 20 years of age, and her only presentation was multiple cutaneous swellings predominantly in the extremities. She did not have any evidence of systemic disease at that time. Only a few cases of such cutaneous presentations have been reported in the literature (Table I). The patient became symptomatic one and half years later, with disseminated disease that resulted in a rapidly downhill course.

Table 1. Clinical, immunophenotypic characteristics and treatment of primary precursor cutaneous B-cell lymphoblastic lymphoma reported in the literature.

Study	No. of patients	Age	Gender	Site/lesion	Immunophenotype	Treatment	Status/FU
Link et al, 1983 ⁽⁹⁾	1	3 yrs 9 mths	F	Scalp	CD10+	Chemotherapy	CR/11 mths/ Relapse & died at 2 yrs
Sander et al, 1991 ⁽⁶⁾	4	6–39 yrs	1M, 3F	Scalp 2, Forehead 2,	CD10+, CD19+, TdT+ (done in 2 patients)	Chemotherapy & chemotherapy with BMT 1	2 CR, 1 relapse (died), 1 lost to FU/3 mths–12 yrs
Millot et al, 1997 ⁽⁵⁾	9	4 mths– 9 yrs	7F, 2M	Scalp 7, Face 1, Chest wall 1	pre-B phenotype in 2, common B lineage in 5 (details not given)	Chemotherapy	7 CR, 1 died, 1 relapse/12– 60 mths
Lin et al, 2001 ⁽¹⁰⁾	6	6–27 yrs	4F, 2M	Scalp 1, Forehead 1, External ear 2, Scapula 1, Back (lumbar) 1	TdT+ in all 6, CD34, CD19 & CD10+ in 3	Chemotherapy 3, Surgery 1 (followed by radiation & salvage chemotherapy), denied treatment 2	2 CR, 2 died, 2 lost to FU/12–72 mths
Biasotti et al, 2001 ⁽¹¹⁾	1	14 mths	F	Buttocks, arm, leg	CD10+, CD19+, TdT+	Chemotherapy	CR/18 mths
Maitra et al, 2001 ⁽²⁾	1	10 yrs	F	Forehead	CD10+, TdT+	Chemotherapy	CR/16 mths
Trupiano et al, 2002 ⁽¹²⁾	1	8 wks	M	Buttocks, trunk	CD34+, CD19+	Chemotherapy	CR/13 mths
Kahwash et al, 2002 ⁽⁸⁾	6	5–15 yrs	6F	Scalp 3, Face 1, Orbit 1, Thigh 1	CD79a+ in all, CD20+ in 1, TdT+ in 5	Radiotherapy 1, Chemotherapy 5	5 CR, 1 died/1–18 yrs
Shafer et al, 2008 ⁽¹⁾	2	27 & 66 yrs	2M	Scalp 2 (1 also in trunk)	TdT+ in 2, CD34, CD10, CD20+ in 1	Chemotherapy	1 CR, 1 died/2 mths & 34 mths

M: male; F: female; CR: complete remission; FU: follow-up; BMT: bone marrow transplant

REFERENCES

1. Shafer D, Wu H, Al-Saleem T, et al. Cutaneous precursor B-cell lymphoblastic lymphoma in 2 adult patients: clinicopathologic and molecular cytogenetic studies with a review of the literature. *Arch Dermatol* 2008; 144:1155-62.
2. Maitra A, McKenna RW, Weinberg AG, Schneider NR, Kroft SH. Precursor B-cell lymphoblastic lymphoma. A study of nine cases lacking blood and bone marrow involvement and review of the literature. *Am J Clin Pathol* 2001; 115:868-75.
3. Brunning RD, McKenna RW. Acute leukemias. Tumors of the Bone Marrow. Washington, DC: Armed Forces Institute of Pathology, 1994:100-135. Atlas of Tumor Pathology, Third Series, Fascicle 9.
4. Schmitt IM, Manente L, Di Matteo A, et al. Lymphoblastic lymphoma of the pre-B phenotype with cutaneous presentation. *Dermatology* 1997; 195:289-92.
5. Millot F, Robert A, Bertrand Y, et al. Cutaneous involvement in children with acute lymphoblastic leukemia or lymphoblastic lymphoma. The Children's Leukemia Cooperative Group of the European Organization of Research and Treatment of Cancer (EORTC). *Pediatrics* 1997; 100:60-4.
6. Sander CA, Medeiros LJ, Abruzzo LV, Horak ID, Jaffe ES. Lymphoblastic lymphoma presenting in cutaneous sites. A clinicopathologic analysis of six cases. *J Am Acad Dermatol* 1991; 25:1023-31.
7. Kerl H, Burg G. Histomorphology and cytomorphology of cutaneous B-cell lymphomas. *J Dermatol Surg Oncol* 1984; 10:266-70.
8. Kahwash SB, Qualman SJ. Cutaneous lymphoblastic lymphoma in children: report of six cases with precursor B-cell lineage. *Pediatr Dev Pathol* 2002; 5:45-53.
9. Link MP, Roper M, Dorfman RF, et al. Cutaneous lymphoblastic lymphoma with pre-B markers. *Blood* 1983; 61:838-41.
10. Lin P, Jones D, Dorfman DM, Medeiros LJ. Precursor B-cell lymphoblastic lymphoma: a predominantly extranodal tumor with low propensity for leukemic involvement. *Am J Surg Pathol* 2000; 24:1480-90.
11. Biasotti S, Sementa AR, Zupo S, et al. A novel pediatric case of cutaneous pre-B lymphoblastic lymphoma. *Haematologica* 2001; 86:997-8.
12. Trupiano JK, Bringelsen K, Hsi ED. Primary cutaneous lymphoblastic lymphoma presenting in an 8-week old infant. *J Cutan Pathol* 2002; 29:107-12.