

# Endobronchial pulmonary cryptococcosis and tuberculosis in an immunocompetent host

Thomas R<sup>1</sup>, MD, FRACP, Christopher DJ<sup>1</sup>, DNB, FCCP, Balamugesh T<sup>1</sup>, MD,DM, James P<sup>1</sup>, MD, Thomas M<sup>2</sup>, MD

**ABSTRACT** Pulmonary cryptococcosis presenting as an endobronchial tumour-like growth has rarely been described. We report the case of a male patient with normal immune function who presented with a right upper lobe mass lesion. Bronchoscopy revealed a tumour-like growth that completely occluded the anterior segment of the right upper lobe bronchus. Bronchial biopsy and computed tomography-guided lung biopsy revealed *Cryptococcus*, and culture of lung biopsy specimen grew *Cryptococcus neoformans* and *Mycobacterium tuberculosis*. The patient responded clinically to amphotericin B, fluconazole and anti-tuberculous therapy. However, chest radiographic response was unremarkable. A presentation of pulmonary cryptococcosis and tuberculosis, along with endobronchial tumour-like growth in the same patient, is unusual and has not been previously described.

Keywords: cryptococcosis, endobronchial mass, tuberculosis  
Singapore Med J 2012; 53(2): e32–e34

## INTRODUCTION

Pulmonary cryptococcosis presenting as an endobronchial tumour-like growth has rarely been described. The presentation of cryptococcosis and tuberculosis as an endobronchial growth in the same patient has not been previously reported in the literature.

## CASE REPORT

A 65-year-old Indian man presented to the pulmonary medicine department of the Christian Medical College, Vellore, India with a six-month history of cough productive of white sputum and chest pain. He was a farmer and a smoker with a 2.5 pack-year history. There was no history of wheezing, haemoptysis, loss of weight or appetite or neurological symptomatology. He was initially evaluated at a local hospital and had been prescribed antibiotics for pneumonia of the right lung; however, there was no significant clinical or radiological improvement.

At the time of presentation, physical examination, including a thorough neurological examination, was unremarkable. The patient had no neurological symptoms. Initial investigations revealed a total leucocyte count of 8,400/mm<sup>3</sup> and a differential count of 24% lymphocytes and 65% neutrophils. Blood sugar level as well as other routine blood and urine examinations were normal. Chest roentgenogram (Fig. 1a) and computed tomography (CT) of the chest (Fig. 1b) showed a right upper lobe mass, with evidence of narrowing of the right upper lobe bronchus. Sputum microbiology for acid-fast bacillus was negative. Flexible bronchoscopy was performed, which revealed a tumour-like growth covered with slough that completely occluded the anterior segment of the right upper lobe bronchus (Fig. 2). Bronchial biopsy revealed chronic inflammation, and *Cryptococci* were seen. Bronchial wash samples were not sent for fungal culture, since the bronchoscopic appearance was suggestive of a neoplastic disease; this ruled

out a possible infectious aetiology. A CT-guided biopsy was also performed to confirm the diagnosis and to rule out an underlying neoplastic process. The histopathology also revealed chronic inflammation and *Cryptococci* (Fig. 3), and fungal culture of the lung tissue grew *Cryptococcus neoformans*.

The patient was then evaluated for an underlying immunosuppressive state. Enzyme-linked immunosorbent assay test for human immunodeficiency virus was negative. Total lymphocyte count, serum complement and immunoglobulin levels were normal. CD4 and CD8 counts could not be performed. The patient was initiated on treatment with intravenous amphotericin B. After receiving a cumulative dose of 1 g, amphotericin was replaced with oral itraconazole due to the patient's intolerance to amphotericin. Two months later, the mycobacterial culture of the lung biopsy tissue grew *Mycobacterium tuberculosis*, and the patient was thus started on anti-tuberculosis treatment.

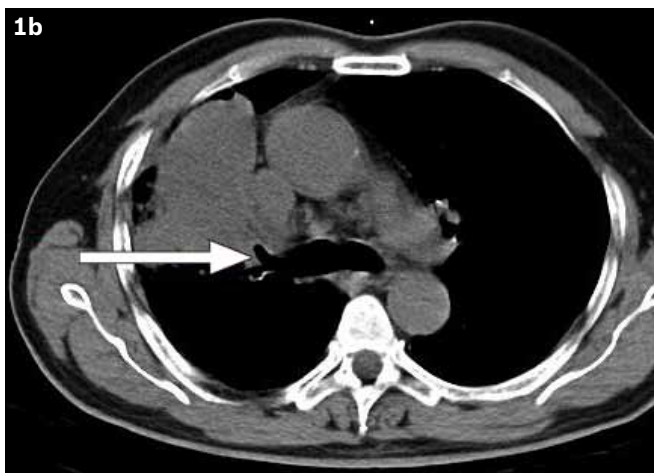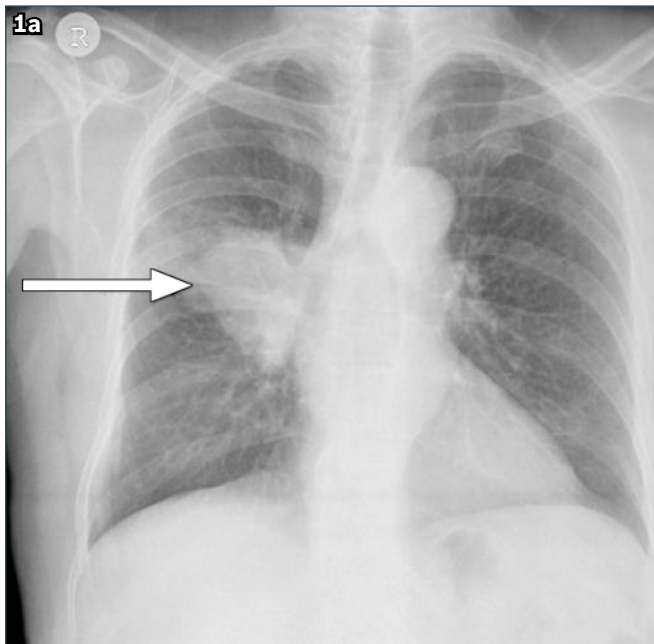
Chest roentgenogram repeated after four months showed no significant resolution. Mycobacterial culture did not reveal any drug resistance, and on close questioning, it appeared that the patient had been compliant with therapy. He had partial clinical and symptomatic improvement, and it was possible that there may have been a radiological lag. A repeat bronchoscopy was advised in order to remove the necrotic tissue and to rule out underlying tumours. Unfortunately, the patient refused further surgical intervention and the repeat bronchoscopy. Anti-tuberculous treatment and itraconazole were continued, but the patient was subsequently lost to follow-up.

## DISCUSSION

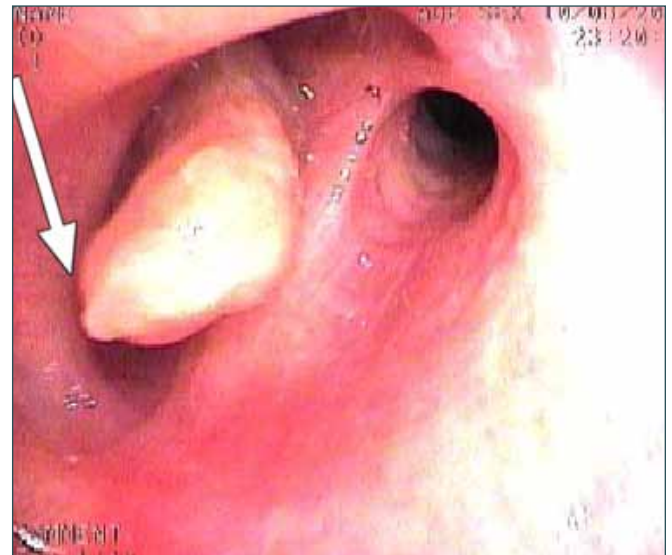Pulmonary cryptococcosis commonly occurs as an opportunistic infection in immunocompromised patients, but it rarely occurs

<sup>1</sup>Department of Pulmonary Medicine, <sup>2</sup>Department of Pathology, Christian Medical College, India

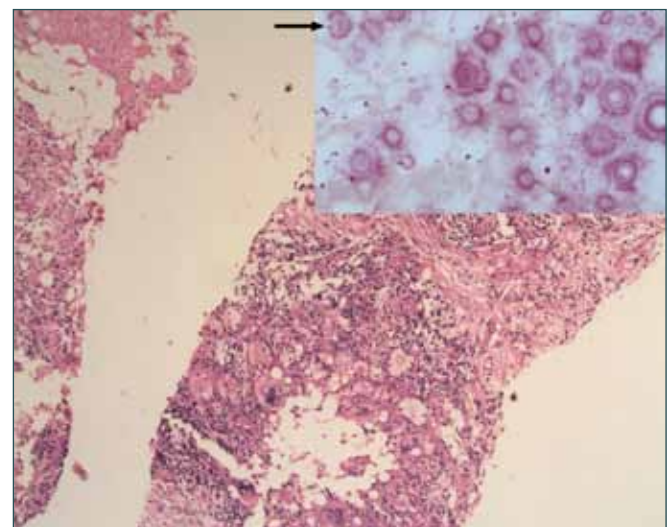
**Correspondence:** Dr DJ Christopher, Professor and Head, Department of Pulmonary Medicine, Christian Medical College, Vellore 632002, Tamil Nadu, India. djchris@cmcvellore.ac.in



**Fig. 1** (a) Chest roentgenogram shows a right upper lobe mass (arrow). (b) Chest CT shows the right upper lobe mass with evidence of narrowing of the right upper lobe bronchus (arrow).



**Fig. 2** Flexible bronchoscopic image shows a tumour-like growth completely occluding the anterior segment of the right upper lobe bronchus (arrow).



**Fig. 3** Histopathology of the lung biopsy shows histiocytes, foamy macrophages and lymphocytes around large yeast-like organisms, with the adjacent lung showing fibrosis (Haematoxylin & eosin,  $\times 100$ ). Inset: photomicrograph shows necrotic lung tissue with a large 16 micron yeast-like organism with thick capsule stained positive for mucicarmine (arrow) (Mucicarmine stain,  $\times 400$ ).

in individuals with normal immunity. It presents radiologically with nodular lesions, pneumonic infiltrates, patchy interstitial or alveolar infiltrates, pleural effusions, hilar masses and thoracic lymphadenopathy.

Endobronchial cryptococcosis has been described in a few case reports. In a retrospective study of 48 patients with disseminated cryptococcosis and acquired immunodeficiency syndrome, endobronchial abnormalities were identified in four patients during bronchoscopy.<sup>(1)</sup> One report described a patient with pulmonary cryptococcosis and AIDS, whose bronchoscopic examination demonstrated white, slightly raised, plaque-like lesions in the trachea and bronchi.<sup>(2)</sup> Endobronchial involvement can also manifest as pseudomembranous tracheo-bronchitis, similar to that described in association with aspergillosis.<sup>(3)</sup>

Endobronchial cryptococcosis presenting as endobronchial mass lesion is rare. Carter et al reported a case of endobronchial cryptococcosis causing complete lung collapse. In this patient, bronchoscopy showed a mass lesion totally occluding the left

lower lobe bronchus and partially occluding the left upper lobe bronchus.<sup>(4)</sup> Long et al described a patient with right upper lobe consolidation, whose bronchoscopy revealed a gelatinous mass in the right upper lobe bronchus.<sup>(5)</sup> Chang et al described a case of primary pulmonary cryptococcosis in an immunocompetent individual who developed left upper lobe collapse due to endobronchial occlusion.<sup>(6)</sup> Mito et al described a patient with cryptococcosis with an elevated lesion in the truncus intermedius on bronchoscopic examination.<sup>(7)</sup> Emmons et al<sup>(8)</sup> and Mahida et al<sup>(9)</sup> have also reported cases of endobronchial cryptococcoma.

Our case was unique, as our patient had both endobronchial cryptococcosis and tuberculosis. The diagnosis of cryptococcosis was based on both histology and culture from multiple sterile

samples, including lung and bronchial tissues, while that of tuberculosis was based on positive culture from lung tissue. The patient had partial clinical and symptomatic improvement, but there was no initial radiological response. This may have been due to a lag in radiological response, which is known to occur. Unfortunately, the patient was lost to follow-up, and the final outcome is thus unknown. There is no report in the literature where endobronchial cryptococcosis and tuberculosis have presented as an endobronchial tumour-like mass in the same patient. Also, despite an extensive evaluation, we found no evidence of immune deficiency in our patient. There appears to be no evidence in the literature that suggests that presentation with an endobronchial lesion is associated with immunocompromise.<sup>(9)</sup> This case report also highlights the fact that pulmonary cryptococcosis and tuberculosis can sometimes mimic a lung neoplasm radiologically and bronchoscopically, and therefore, they need to be considered in the differential diagnosis of endobronchial mass lesions.

---

## REFERENCES

1. Chechani V, Kamholz SL. Pulmonary manifestations of disseminated cryptococcosis in patients with AIDS. *Chest* 1990; 98:1060-6.
2. Kashiya T, Kimura A. Endobronchial cryptococcosis in AIDS. *Respirology* 2003; 8:386-8.
3. Peikert T, Prakash UB, Tazelaar HD. Endobronchial Cryptococcosis. *Chest* 2004; 126:946S.
4. Carter EA, Henderson DW, McBride J, Sage MR. Case report: complete lung collapse-an unusual manifestation of cryptococcosis. *Clin Radiol* 1992; 46:292-4.
5. Long RF, Berens SV, Shambhag GR. An unusual manifestation of pulmonary cryptococcosis. *Br J Radiol* 1972; 45:757-9.
6. Chang YS, Chou KC, Wang PC, Yang HB, Chen CH. Primary pulmonary cryptococcosis presenting as endobronchial tumor with left upper lobe collapse. *J Chin Med Assoc* 2005; 68:33-6.
7. Mito K, Kawano H, Yamakami Y, et al. [Primary pulmonary cryptococcosis with endobronchial lesion]. *Nihon Kogyoku Gakkai Zasshi* 2000; 38:302-6. Japanese.
8. Emmons WW 3rd, Luchsinger S, Miller L. Progressive pulmonary cryptococcosis in a patient who is immunocompetent. *South Med J* 1995; 88:657-60.
9. Mahida P, Morar R, Goolam Mahomed A, et al. Cryptococcosis: an unusual cause of endobronchial obstruction. *Eur Respir J* 1996; 9:837-9.