

# Ganglion cyst of the posterior cruciate ligament in a child

Shamsi Abdul Hameed<sup>1</sup>, MS Ortho, Premjit Sujir<sup>1</sup>, MS Ortho, Monappa A Naik<sup>1</sup>, DNB Ortho, Sharath K Rao<sup>1</sup>, MS Ortho

**ABSTRACT** Ganglion cysts are more commonly associated with the anterior cruciate ligament than the posterior cruciate ligament (PCL). A literature review showed that all reported cases of ganglion cysts to date involved adults. We report a rare case of ganglion cyst in the PCL of a four-year-old boy, and discuss its aetiology, clinical presentation, imaging features and management. Ganglion cysts of the PCL may be confused with meniscal cysts arising from tears of the posterior horn of the medial meniscus on magnetic resonance (MR) imaging. Hence, the posterior horn of the medial meniscus has to be carefully evaluated to rule out a tear. MR imaging is the method of choice to confirm diagnosis, and arthroscopic resection is a safe treatment modality even in children.

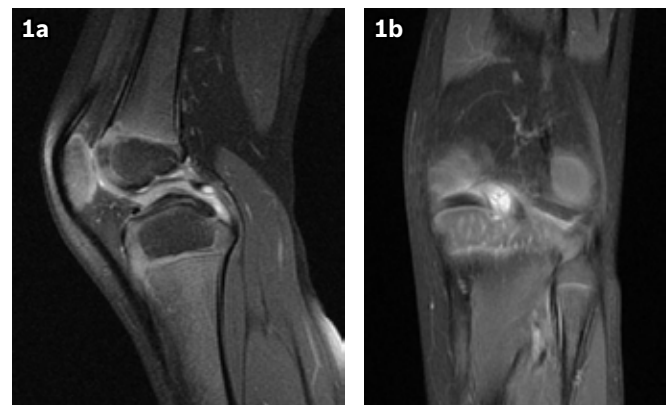
Keywords: ganglion cyst, posterior cruciate ligament  
Singapore Med J 2012; 53(4): e80–e82

## INTRODUCTION

Ganglion cysts usually arise close to tendons and joints. Their occurrence inside the joint is rare and is typically an incidental finding during arthroscopy or magnetic resonance (MR) imaging. The first case of ganglion cyst of the knee joint, reported by Caan in 1924,<sup>(1)</sup> was asymptomatic. It was discovered during a postmortem dissection of the knee and was located in the anterior cruciate ligament (ACL). In 1965, Bromley and Cohen reported the first case of ganglion cyst in the posterior cruciate ligament (PCL) in a 21-year-old woman.<sup>(2)</sup> Ganglion cysts are more commonly associated with the ACL rather than the PCL.<sup>(3)</sup> We report a rare case of ganglion cyst in the PCL of a four-year-old child, and present its aetiology, clinical presentation, imaging features and management.

## CASE REPORT

A four-year-old Indian boy presented with pain in his left knee for the past six months. The pain was dull and aching, and was localised at the back of the knee. It was associated with a limp while walking, which was exacerbated by running and was not relieved with rest. There was no history of trauma to the knee or constitutional symptoms. Clinical examination revealed wasting of the quadriceps muscle and deep tenderness over the posteromedial joint line without any swelling. The patient had full range of motion but experienced pain during 60 degrees of flexion to full extension. The McMurray and Lachman tests, as well as the anterior drawer, posterior drawer, varus and valgus stress tests were all negative. There was no retropatellar tenderness, and patellar movements were normal. Plain radiographs of the knee and diagnostic ultrasonography (US) were normal. MR imaging of the left knee revealed minimal joint effusion and a thickened PCL with a focal, well-defined, oval area of altered signal intensity, which was hyperintense on proton density-weighted fat suppression and



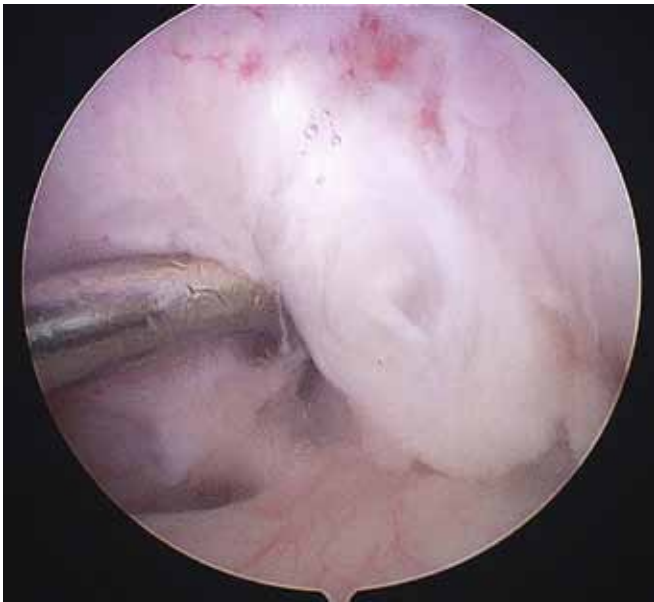
**Fig. 1** (a) Sagittal and (b) coronal PDFS images of the knee joint show a well-defined, oval, hyperintense lesion in the posterior aspect of the posterior cruciate ligament at its mid-substance.

gradient-recalled echo sequences and showed mild peripheral rim of enhancement on contrast-enhanced MR imaging. Other internal structures of the knee, including the ACL, menisci and collateral ligaments, were found to be normal. The presence of a tear to the posterior horn of the medial meniscus was carefully ruled out. MR image was suggestive of a PCL ganglion cyst or mucoid degeneration of the PCL (Fig. 1).

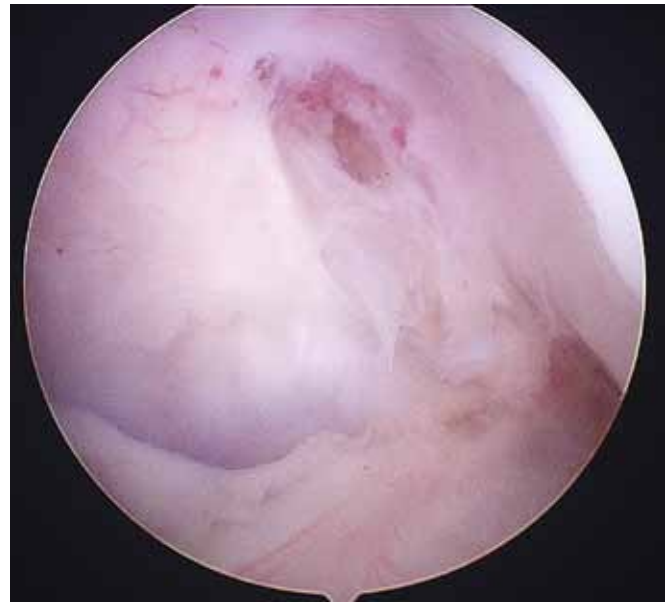Due to persistent knee pain, the patient subsequently underwent arthroscopy of the left knee. The cyst was excised arthroscopically, and the PCL was debulked (Figs. 2 & 3). Both menisci, the ACLs and PCLs were intact. A biopsy report confirmed the diagnosis of ganglion cyst. Microscopic sections showed a partially collapsed cyst lined by flattened cells, focal myxoid changes in the wall, adjacent tissue fibrosis and dilated vascular channels. The patient achieved a pain-free, full range of motion of the knee joint in two weeks and has since remained asymptomatic.

<sup>1</sup>Department of Orthopaedics, Kasturba Medical College, Manipal University, Manipal, India

**Correspondence:** Dr Shamsi Abdul Hameed, Associate Professor, Department of Orthopaedics, Kasturba Medical College, Manipal University, Manipal, Karnataka 576104, India. shams273@yahoo.com



**Fig. 2** Arthroscopic view of the knee through the anterolateral portal shows the ganglion within the posterior cruciate ligament.



**Fig. 3** Anterolateral portal view of the knee after resection of the cyst shows intact posterior cruciate ligament fibres (after debulking).

## DISCUSSION

Intra-articular ganglion cysts in the knee arise from alar folds that cover either the infrapatellar fat pad or the cruciate ligaments.<sup>(4)</sup> Intra-articular cysts are predominantly incidental findings on MR imaging and arthroscopy, with a reported prevalence of 0.2%–1.3% and 0.6%, respectively.<sup>(3,4)</sup> Ganglion cyst of the PCL is uncommon, and a literature review showed that all reported cases to date involved adults.<sup>(1-4)</sup> Our patient was only four years old and is likely to be the first case of a ganglion cyst in the knee reported in a child.

The symptoms of intra-articular ganglion cyst may resemble those of internal derangement of the knee. However, in the study by Brown and Dandy,<sup>(5)</sup> pain was the most common complaint and 50% of the cases with intra-articular ganglion demonstrated on arthroscopy had no indication of abnormality of the knee other than the ganglion.<sup>(4,5)</sup> The clinical presentation of ganglion cyst associated with the PCL is variable and nonspecific. Patients typically experience knee pain, a sense of fullness during extreme flexion of the knee, limitation in knee motion and flexion or extension block.<sup>(6)</sup> However, our patient had pain only, and apart from the ganglion, the other structures in the knee were normal on arthroscopy.

The aetiology of intra-articular ganglion remains unknown. The theories include herniations of the synovium into the surrounding tissue, displacement of synovial tissue during embryogenesis, degeneration of the connective tissue following trauma and proliferation of pluripotent mesenchymal stem cell.<sup>(7)</sup> Intra-articular ganglion is mostly acquired following trauma or irritation. The likelihood of synovial herniation into the developing PCL seems to be the most probable cause in our case considering the patient's age and absence of trauma. As the development continued, the synovium within the fibres of the PCL may have lost its connection with the intra-articular portion and then developed into a cyst. The suspected aetiology of ganglion cyst of the PCL may be

mechanical stress experienced on the posterior aspect of the cruciate ligament during knee motion; however, this remains a theory.<sup>(3)</sup> The site of origin of the main cystic component is posterior to the PCL in 87.5% and anterior to the PCL in 12.5% of cases.<sup>(3)</sup> In our patient, the cyst was located in the posterior aspect of the PCL at its mid-substance.

Ganglion cysts of the PCL are usually diagnosed incidentally while investigating other serious knee-related pathologies with diagnostic US or MR imaging. The modality of choice is MR imaging, as it is the most sensitive and specific for depicting cystic masses.<sup>(3)</sup> Rarely, ganglion cysts of the PCL may be confused with meniscal cysts arising from tears of the posterior horn of the medial meniscus on MR imaging, especially the larger cysts. Hence, the posterior horn of the medial meniscus has to be carefully evaluated to rule out a tear.<sup>(8)</sup> The main approach in the treatment of ganglion cyst of the PCL is surgical, the most common being arthroscopic resection.<sup>(3,5)</sup> Computed tomography and US-guided aspirations have also been used to treat intra-articular cysts; however, the incidence of recurrence following these procedures is reported to be high.<sup>(3)</sup>

To conclude, ganglion cyst of the PCL is very uncommon and has not been reported in a child. This is a rare incidence of intra-articular ganglion cyst of the knee joint with respect to the age of the patient and the anatomical structure involved. It is important to consider PCL cysts as a differential diagnosis in painful knee conditions in young children without any history of significant trauma or constitutional symptoms. MR imaging is the investigation of choice to confirm the diagnosis, and arthroscopic resection is a safe treatment modality, even in children.

## REFERENCES

1. Caan P. Cyst formation (ganglion) in an anterior cruciate ligament of the knee. *Dtsch Z Chir* 1924; 186:403-8.
2. Bromley JW, Cohen P. Ganglion of the posterior cruciate ligament: report of a case. *J Bone Joint Surg Am* 1965; 47:1247-9.

3. Durante JA. Ganglion cyst on the posterior cruciate ligament: case report. *J Can Chiropr Assoc* 2009; 53: 334-8.
4. Bui-Mansfield LT, Youngberg RA. Intraarticular ganglia of the knee: prevalence, presentation, etiology and management. *AJR Am J Roentgenol* 1997; 168:123-7.
5. Brown MF, Dandy DJ. Intraarticular ganglia in the knee. *Arthroscopy* 1990; 6:322-3.
6. Deutsch A, Veltri DM, Altchek DW, et al. Symptomatic intra articular ganglion cyst of the cruciate ligament. *Arthroscopy* 1994; 10:110-2.
7. Silberberg R. Diseases of the joints. In: Kissane JM, ed. *Anderson's pathology* 8th edn. Vol. 2. St Louis: Mosby, 1985:1842.
8. Lektrakul N, Skaf A, Yeh L, et al. Pericruciate meniscal cysts arising from tears of the posterior horn of the medial meniscus: MR imaging features that simulate posterior cruciate ganglion cysts. *Am J Roentgenol* 1999; 172:1575-9.