

# Congenital absence of the vermiform appendix

Aniruddha Sarkar<sup>1</sup>, MBBS, MD

**ABSTRACT** Agenesis of the vermiform appendix is very rare. The incidence is estimated to be one in 100,000 laparotomies for suspected appendicitis. During a routine dissection of the abdomen in a 60-year-old donated male cadaver, the vermiform appendix was found to be absent. The ileocaecal junction and retrocaecal area were thoroughly searched, but the vermiform appendix was not found or appeared to resemble a tubercle. This is likely the first reported case of agenesis of a vermiform appendix in India. This suggests the possibility that the human vermiform appendix would ultimately become rudimentary or absent in the course of evolution.

*Keywords: agenesis of vermiform appendix  
Singapore Med J 2012; 53(9): e189–e191*

## INTRODUCTION

Agenesis of the vermiform appendix is an incidental finding during laparotomies for suspected cases of appendicitis, with a ratio of 1:100,000.<sup>(1)</sup> According to the evolutionary knowledge of comparative anatomy, many organs in our body can be categorised as vestiges. The vermiform appendix is the most commonly cited and the most disputed vestigial organ in our body. To date, all experimental studies that determine the functions of the vermiform appendix have been conducted mostly in rabbits and, to a lesser extent, in rodents.

It is currently unclear whether the gut-associated lymphoid tissue (GALT) in the human appendix performs any specialised function apart from the function performed by the much larger lymphoid tissue already distributed throughout the gut.<sup>(2)</sup> In comparative vertebrate anatomy, it has been well-established that the human appendix and the end of the mammalian caecum are homologous.<sup>(3)</sup> The appendix is the blind, terminal end of the caecum and hence, it can be called the 'true caecal apex'. It is very difficult to identify the rabbit's appendix as separate from the rest of the caecum. The rabbit's caecum is extremely large, relative to the colon, and can degrade ingested cellulose due to its specialised microflora. The rabbit's appendix is also the site of the GALT lodgement, whereas the human appendix has little contribution to the lodgement of the GALT. In humans, the majority of the GALT is distributed as Peyer's patches in the small intestine in the hundreds and in the large intestine at nearly 10,000. There are important differences in lymphoid follicular structure, T-cell distribution and immunoglobulin density between the human appendix and the GALT.<sup>(3)</sup> As the epithelium of the human vermiform appendix is coated with a biofilm of commensal bacterial flora that may play a role in gut immunity, it is thought that the appendix is preserved by natural selection.<sup>(4)</sup>

It is still unclear if the human vermiform appendix plays any role in cellulose digestion. In herbivorous animals, the caecum is essential for the digestion of cellulose, a very common plant

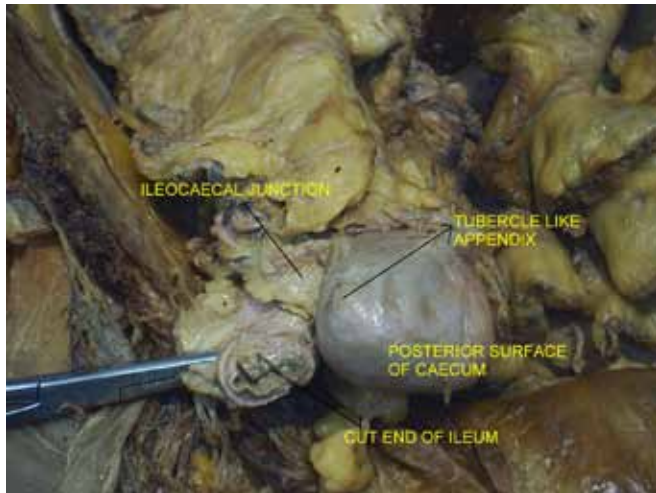
molecule. In these animals, the caecum is the site of aggregation of a specialised symbiotic microflora that can secrete the enzyme cellulase, without which cellulose digestion is impossible. The human caecum is different from that of herbivorous animals because the small human caecum does not house any significant amount of cellulase-excreting bacteria. Thus, we can only digest a negligible amount of cellulose.<sup>(5)</sup>

The human vermiform appendix is a vestigial organ as it has been proven that the removal of this organ after infancy does not cause any harm. It has also been proven that persons with agenesis of the vermiform appendix can lead a normal life.<sup>(1,6)</sup> Although the vermiform appendix is not essential for humans, its presence might become dangerous by causing life-threatening appendicitis. Acute appendicitis is more common in young age and the lifetime risk is 7%.<sup>(7,8)</sup> In the case of humans, the appendix, a dead-end pocket, opens in the caecum through a small opening, which makes it prone to physical blockage and can ultimately lead to appendicitis. In 60% of the cases, lymphoid hyperplasia obstructing the lumen and its opening is the leading cause of acute appendicitis, indicating that the human appendix is prone to abnormal proliferation of lymphoid aggregation.<sup>(9)</sup> If the opening of the human appendix were to be wider and the lumen more spacious, then the incidence of appendicitis would be considerably reduced. In other primates, the appendix can perform better due to its wider opening to a larger caecum.<sup>(10)</sup>

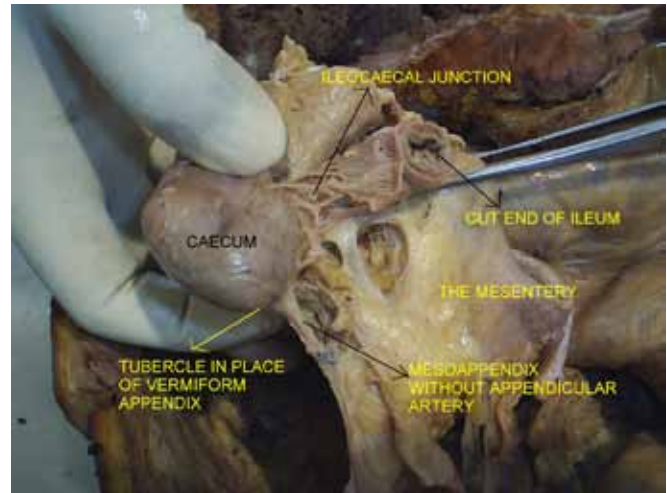
It has also been proven that the removal of the appendix in humans helps to prevent the occurrence of ulcerative colitis, an inflammatory disease of the colon. In humans, it can be said that the vermiform appendix is not properly constructed and is a maladaptive organ with tightly packed lymphoid aggregations, making it highly prone to inflammatory reactions. Therefore, on the path of evolution, if there is agenesis of the human vermiform appendix, we could escape from the ill-effects of the appendix, such as appendicitis. Although the present case report has no

<sup>1</sup>Department of Anatomy, Medical College, Kolkata, West Bengal, India

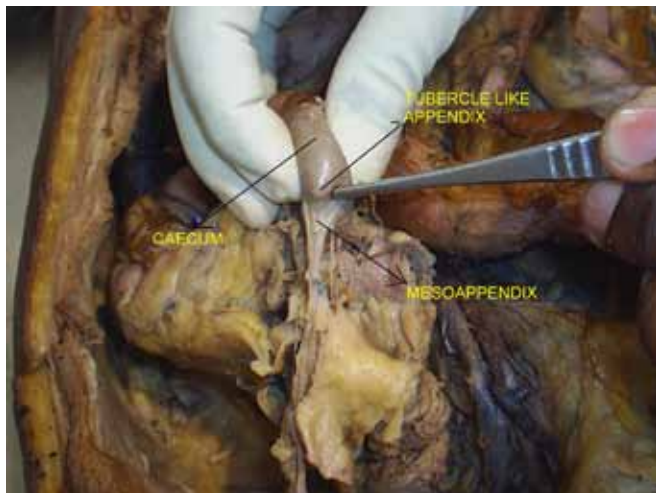
**Correspondence:** Dr Aniruddha Sarkar, Assistant Professor, Department of Anatomy, Medical College, 88 College Street, Kolkata 700073, West Bengal, India. drani77@gmail.com



**Fig. 1** Photograph shows the caecum with its tubercle-like appendix as seen from the front.



**Fig. 3** Photograph shows the posterior surface of the caecum with its tubercle-like appendix.



**Fig. 2** Photograph shows the caecum, as viewed from its apex, with its tubercle-like appendix.

immediate impact on surgical therapeutics, this very rare anomaly can act as a basis for the path of evolution through which, after many years, we can expect human beings without the vermiform appendix.

## CASE REPORT

During a routine dissection of the abdomen in a 60-year-old donated male cadaver in Medical College Kolkata, India, the vermiform appendix was not found. However, on the caecum 2 cm below the ileocaecal junction, one tubercle was seen (Figs. 1 & 2). After an appendectomy operation, the base or stump of the appendix usually appears inverted and puckered, but in this case, the tubercle had a blunt apex that was not puckered or inverted. Histopathological examination confirmed the dissected tubercle as the vermiform appendix. However, there was no incision mark on the abdominal skin, and the mesentery appeared normal on dissection.

According to the history obtained from the family members of the deceased, the deceased had not undergone any appendectomy or abdominal operations during his lifetime.

He did not suffer from any chronic disease, except hypertension. There was no history of taking medications for a prolonged period except for antihypertensive medicines. He had died due to intracerebral haemorrhage. During dissection, no mesoappendix or a separate artery for the tubercle-like appendix was found (Fig. 2).

## DISCUSSION

Developmentally, the vermiform appendix is the lower, narrower part of the caecal diverticulum, which arises from the distal limb of the U-shaped loop of the primitive midgut loop. To reach the right iliac fossa, the caecum and the appendix undergo a 270° rotation around the axis of the superior mesenteric artery. The appendix retains its free mesentery, called the mesoappendix, through which the appendicular artery, a branch of the inferior division of the ileocolic artery, will pass.<sup>(11)</sup>

A developmental defect called the familial apple peel jejunal atresia<sup>(12)</sup> may be associated with 'short gut syndrome'. The disease is thought to be transmitted by an autosomal recessive gene. In jejunal atresia, or short gut syndrome, the appendix may be absent.<sup>(13)</sup> Thalidomide can prevent the growth of the appendix if the foetus is exposed to thalidomide in the intrauterine stage.<sup>(14)</sup> The lengths of the appendix and the mesoappendix increase with gestational age. Along with the growth of the distal part of the appendix, there is a separate artery, called the appendicular artery, that will pass through the mesoappendix. Therefore, in agenesis of the appendix, there is no need for the appendicular artery. Lymphocyte aggregation at the appendix first appears in the 17<sup>th</sup> week of gestation and when the appendix matures in the second trimester of the foetal period.<sup>(5)</sup>

In conclusion, from an evolutionary perspective, the human appendix is a derivative of the end of the phylogenetically primitive herbivorous caecum that was found in our primate ancestors. It is now proven that the human appendix has no role in cellulose digestion. However, lymphoid aggregation of the vermiform appendix persists and thus most probably has some role in gastrointestinal immunity. However, in order to provide

immunity, the gut is heavily provided with Peyer's patches. Hence, the human vermiform appendix has no role to play and becomes a vestigial organ. On the path to evolution, we can expect a day when there will be no vermiform appendix in the human body. We can then escape from the ill-effects of the vermiform appendix.

## REFERENCES

1. Chèvre F, Gillet M, Vuilleumier H. Agenesis of the vermiform appendix. *Surg Laparosc Endosc Percutan Tech* 2000; 10:110-2.
2. Dasso JF, Howell MD. Neonatal appendectomy impairs mucosal immunity in rabbits. *Cell Immunol* 1997; 182:29-37.
3. Dasso JF, Obiakor H, Bach H, Anderson AO, Mage RG. A morphological and immunohistological study of the human and rabbit appendix for comparison with the avian bursa. *Dev Comp Immunol* 2000; 24:797-814.
4. Randal Bollinger R, Barbas AS, Bush EL, Lin SS, Parker W. Biofilms in the large bowel suggest an apparent function of the human vermiform appendix. *J Theor Biol* 2007; 249:826-31.
5. Slavin JL, Brauer PM, Marlett JA. Neutral detergent fiber, hemicellulose and cellulose digestibility in human subjects. *J Nutr* 1981; 111:287-97.
6. Hei EL. Congenital absence of the vermiform appendix. *ANZ J Surg* 2003; 73:862.
7. Addis DG, Shaffer N, Fowler BS, Tauxe RV. The epidemiology of appendicitis and appendectomy in the United States. *Am J Epidemiol* 1990; 132:910-25.
8. Körner H, Söndena K, Söreide JA, et al. Incidence of acute nonperforated and perforated appendicitis: age-specific and sex-specific analysis. *World J Surg* 1997; 21:313-7.
9. Andersson RE, Olaison G, Tysk C, Ekblom A. Appendectomy and protection against ulcerative colitis. *N Engl J Med* 2001; 344:808-14.
10. Buerger N, Schulzke JD, Zeitz M. [Appendectomy reduces the risk of development of ulcerative colitis]. *Chirurg* 2002; 73:805-8. German.
11. Langman's Medical Embryology. Digestive system. In: Sadler TW, ed. *Special Embryology*. Philadelphia: Lippincott Williams and Wilkins, 2004: 308-9.
12. Seashore JH, Collins FS, Markowitz RI, Seashore MR. Familial apple peel jejunal atresia: surgical, genetic and radiological aspects. *Pediatrics* 1987; 80:540-4.
13. Woywodt A, Verhaart S, Kiss A. Atresia of the appendix. *J Pediatr Surg* 1998; 33:1423-5.
14. Shand JE, Bremner DN. Agenesis of the vermiform appendix in a thalidomide child. *Br J Surg* 1977; 64:203-4.